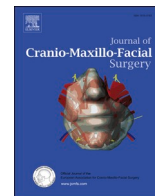



Contents lists available at ScienceDirect

Journal of Cranio-Maxillo-Facial Surgery

journal homepage: www.jcmfs.com

Treating head and neck venous malformations with cold helium plasma electrosurgical device: A 17 patients case series

Benedetta Mattei ^a, Giacomo Colletti ^{a,*}, Sara Negrello ^a, Alexandre Anesi ^a,
Giangiacomo Sanna ^b, Riccardo Nocini ^c

^a Department of Medical and Surgical Sciences for Children & Adults, Cranio-Maxillo-Facial Surgery, University of Modena and Reggio Emilia, Largo del Pozzo, 71, 41124, Modena, Italy

^b Department of Surgical and Odontostomatological Sciences for Children & Adults, University of Verona, Piazzale Aristide Stefani, 1, 37126, Verona, Italy

^c Head and Neck Department, Unit of Otolaryngology, University of Verona, Piazzale Aristide Stefani, 1, 37126, Verona, Italy

ARTICLE INFO

Keywords:

Cavernous angioma
Cavernous hemangioma
Venous malformations
Head and neck
Helium plasma

ABSTRACT

Venous malformations (VMs) are some of the most common vascular malformations. Their treatment varies from laser to sclerotherapy and surgery. For many years, radiofrequency and argon plasma devices have been used on soft tissues VMs. However, their use has been limited because of high thermal impact of nearby structures. The here described cold-helium plasma electrosurgical device carries intrinsic bio-technical advantages, as the helium plasma beam manages to move towards tissues with less impedance, such as VM vessels. The primary objective of this study was to assess if J-Plasma® could be effective on treating the superficial portion of VMs, in a single or multimodal approach.

From January 2022 to January 2024, 17 patients affected by head and neck VM involving mucosa or skin were treated using J-Plasma®, in addition to sclerotherapy. More than 1 session was needed in all but 1 patient. All patients showed a progressive shrinkage of the venous chambers and thickening of the surface, while no major intraoperative and perioperative complications, such as necrosis or severe bleeding were observed. Minor complications like oedema or exfoliation were mild. All 17 patients had a complete healing of the mucosal surface one week after treatment. The grade of effectiveness and the stability of the results correlated with the complexity of the VMs. This research may serve as groundwork for future studies that may aim to explore the use of this device on other vascular malformations.

Level of evidence: Case series: level 4.

1. Introduction

First approved in 2012 by FDA, J-Plasma® (Apyx Medical Corporation, Clearwater, Florida) is an energy device which combines cool helium plasma technology with radiofrequency energy. This allows heat to be transferred to tissues in two ways in a combined manner: first, radiofrequency energy is transmitted by an electrosurgical generator unit to energize an electrode, then a helium plasma beam is produced by directing helium gas through the same energized electron. This allows heat to be transferred to tissue as a cold focused helium stream with low voltages. Minimum lateral thermal effect is generated through the ionization and rapid neutralization of helium atoms (Gentile, 2018). In this way, coagulation and soft-tissue contraction occur via rapid heating and likely rapid cooling by conductive heat transfer to surrounding

tissue and unionized helium (Masghati et al., 2019). Through this technology, radiofrequency energy can be handled to continuously move towards tissues with the least resistance as it encounters structures with varying impedance, allowing minimal depth of thermal effect and directing the energy flow to the whole area without having to redirect it around manually (Doolabh, 2019; Masghati et al., 2019).

In the last few years, this electrosurgical unit has been applied to different surgical areas, such as urology (Hirst et al., 2014), oncological gynecological surgery (Alletti et al., 2022; Parsa, 2015; Theodoulidis et al., 2022), dermatologic and plastic surgery (Doolabh, 2019; Gay--Mimbrera et al., 2016) and vascular surgery (Filis et al., 2020) emerging as a valid means in treating many delicate anatomical structures.

Venous malformations (VM) are congenital malformations of the vascular system that predominantly or exclusively affect the venous

* Corresponding author.

E-mail address: giacomo.colletti@unimore.it (G. Colletti).

<https://doi.org/10.1016/j.jcms.2025.02.024>

Received 17 July 2024; Received in revised form 28 January 2025; Accepted 18 February 2025

Available online 22 February 2025

1010-5182/© 2025 The Authors. Published by Elsevier Ltd on behalf of European Association for Cranio-Maxillo-Facial Surgery. This is an open access article under the CC BY license (<http://creativecommons.org/licenses/by/4.0/>).

system (Carqueja et al., 2018; Bertino et al., 2021). They are the most common vascular malformations along with the capillary ones (Colletti and Ierardi, 2017). Clinically, a venous malformation presents as a soft, compressible mass that enlarges when the venous pressure increases and deflates when the opposite occurs. When the skin is involved, a bluish discoloration is typical, while when a venous malformation develops within a mucosal membrane, it results in an intense bluish-purple stain or bulge. In extensive cases, the use of sclerosing agents is the treatment of choice when dealing with VM, especially ethanol and sodium tetradecyl sulfate (Fowell et al., 2017). Bleomycin and other sclerosants have also proven effective. Sclerotherapy can be the sole treatment mode in some cases while in other circumstances it can be used as a preparatory aid before surgical removal of the VM, while surface Nd:YAG can be useful and effective to treat superficial VMs of the skin and mucosa (Colletti et al., 2014; Seront et al., 2018).

Because of its intrinsic technology, we hypothesized that J-Plasma® could be particularly useful in treating vascular malformations of the head and neck district, in particular venous malformations, because the helium plasma beam finds its path towards tissues with the least impedance, such as VM vessels, which typically present with a single layer of endothelial cells (Colletti et al., 2014).

The primary objective of this study was to assess if J-Plasma® could be effective to help managing the superficial portion of venous malformations of the head and neck, as a single means or in the setting of a multimodal approach.

2. Materials and methods

The present study received approval from the IRB of University of Modena and Reggio Emilia.

Seventeen patients were enrolled from January 2022 to February 2024 (Table 1). The inclusion criteria were:

- 1 clinically, radiologically and/or histologically proven venous malformations (VMs) involving the head and neck
- 2 Mucosal and/or cutaneous involvement of the VM
- 3 VMs treated with the aid of a cold helium plasma electro-surgical device alone or in a multimodal setting (see Table 1).

The procedures were all carried out by the same surgeon (G.C.) from a single institution (AOU Policlinico di Modena). Written informed consent was obtained from all individual participants (or legal guardians if patient was underage) before each procedure, along with permission for acquiring and sharing photographic material and results publication.

The enrolled patients were 11 females and 6 males; the youngest one was 18 months-old, two patients were 6 years old, one was 11 years old, two of them were 14 years old and the oldest one was a 64-year-old woman. Twelve patients out of seventeen were affected by a VM involving the tongue (Fig. 1), eight patients presented with a VM of the mucosal side of the cheek (Fig. 2), five of them were treated for skin and deep soft tissues (subcutis, muscles) venous malformations of the neck or scalp, one of them was affected by a frontotemporal venous malformation and in thirteen patients out of seventeen, nasopharynx, oropharynx and/or laryngopharynx were affected by the vascular malformation (Fig. 3).

The present study received approval from the IRB of University of Modena and Reggio Emilia.

2.1. Technique

The surface of VMs to be treated with J-Plasma® is first identified. In 16 out of 17 patients, this was the mucosal surface of the lips, cheek, tongue, palate, pharynx or larynx. The longer handpiece (15 cm length) of the cold helium plasma electro-surgical device is used pedal-controlled with its Cool-Coag setting at 30–40 W with helium flow at 4L/min, either with its blade retracted or extended, positioning it a few

Table 1
Characteristics of patients and treatments.

	Age (years)	Sex	Site	Concomitant sclerotherapy	Goyal stage
Case 1	14	M	tongue submandibular lodge	ethanol + STS	grade 3
Case 2	32	M	perilaryngeal peripharyngeal space oropharynx	bleomycin	grade 2A
Case 3	30	F	tongue base epiglottis right 2/3 of the face lips	bleomycin + STS	grade 3
Case 4	55	F	tongue soft and hard palate pharynx lips	bleomycin + ethanol + STS	grade 3
Case 5	14	M	rhino nasopharynx oropharynx larynx	/	grade 1
Case 6	43	M	frontotemporal region parietal region occipital region	bleomycin + ethanol + STS	grade 3
Case 7	11/2	F	left and median 2/3 of the neck rhino nasopharynx oropharynx hard and soft palate larynx	bleomycin + STS	grade 1
Case 8	20	F	left cheek	bleomycin + STS	grade 1
Case 9	23	M	oropharynx larynx	bleomycin	grade 1
Case 10	11	F	larynx tongue chin	bleomycin + STS	grade 2A
Case 11	64	F	retromolar trigone tongue larynx	bleomycin + ethanol + STS	grade 3
Case 12	6	F	floor of mouth	bleomycin + STS	grade 2B
Case 13	25	F	oropharynx rhino nasopharynx	bleomycin + ethanol + STS	grade 3
Case 14	53	M	left side of the neck right and left cheek tongue and tongue base	bleomycin + ethanol + STS	grade 3
Case 15	6	F	floor of mouth oropharynx ipharynx	bleomycin	grade 2A
Case 16	20	F	right cheek right side of tongue soft palate inferior 1/3 of the face neck laryngopharynx	bleomycin + ethanol + STS	grade 2B
Case 17	60	F	right cheek tongue oropharynx	bleomycin + ethanol + STS	grade 2A

millimeters detached from the tissue away from the surface that is being treated. This allows the plasma beam to spread out on the surface and the electrical energy to take the path of least impedance, which coincides with malformed venous lakes (see Video 1, Supplementary material).

Supplementary data related to this article can be found online at <https://doi.org/10.1016/j.jcms.2025.02.024>

Thus, when activating the handpiece, the plasma rays will selectively direct to the venous malformation. Heat is then transmitted to the blood and, in turn, to the surrounding walls of the malformation.

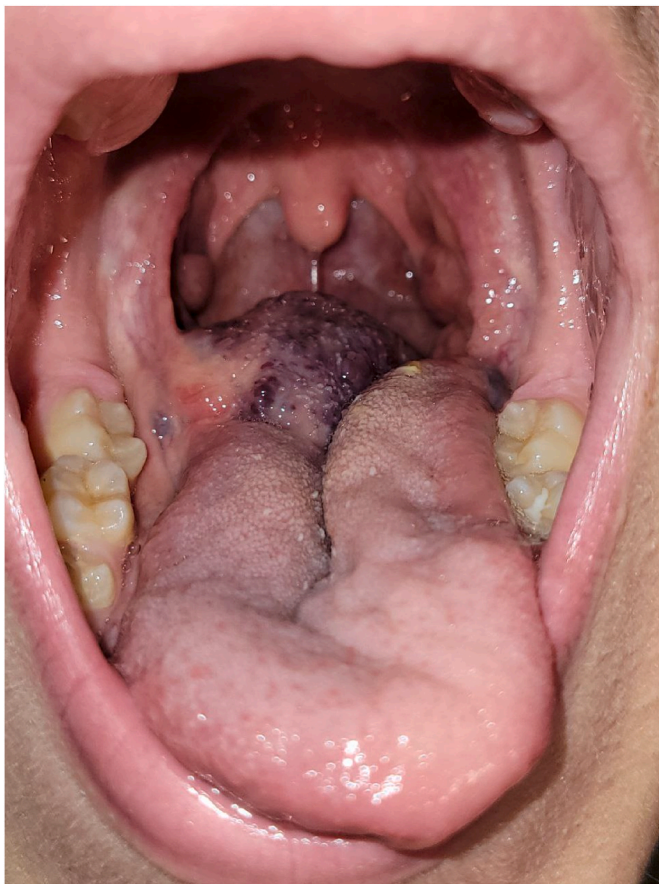

Fig. 1. Venous malformation of the tongue on a 14-year-old patient.

This can be seen as a progressive shrinkage of the venous chamber and as a thickening of the surface.

All 17 patients had a fiberoptic reevaluation at 7 and 14 days after the procedure. After that, they were followed-up at one-month, three-months and six-months with clinical, fiberoptic (when indicated, i.e. pharyngeal and laryngeal disease) and ultrasonographic evaluation. An MRI was done every 6 months after treatment.

Follow-up duration ranged from 10 months to 25 months (average 15 months).

3. Results

To manage the entirety of the VM, 16 out of 17 patients required two to four treatment sessions (See Table 1), while one patient (Pt. 5) was successfully treated in a single session.

One patient presented a vast venous malformation involving almost the entirety of his left epicranial soft tissues, the naso and oropharynx, and the neck (Pt. 6). A significant part of the VM involved the anterior neck in full thickness as well. This patient was treated in a multimodal setting: a) tracheostomy under local anesthesia; b) J-plasma® treatment of the mucosal part of the malformation (naso and oropharynx,

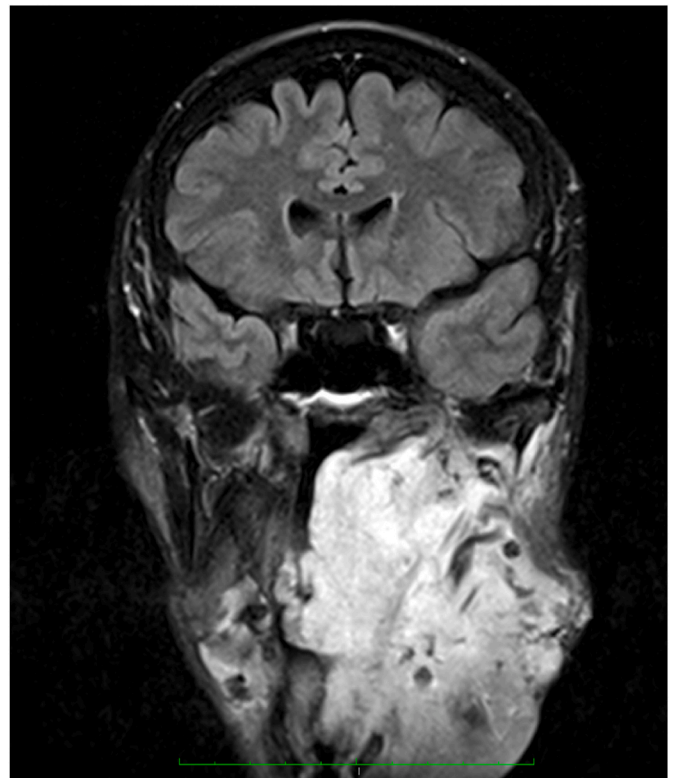


Fig. 3. A typical venous malformation involving the rhino naso-oropharynx and the glottic-periglottic spaces. T2 weighted MRI is hyperintense with black spots corresponding to phleboliths.

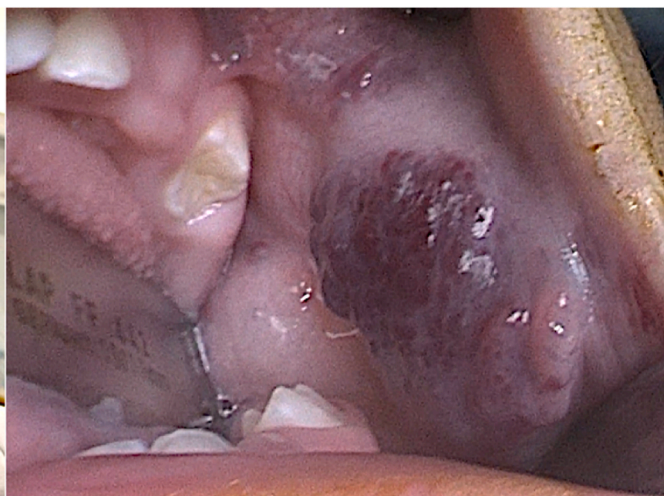
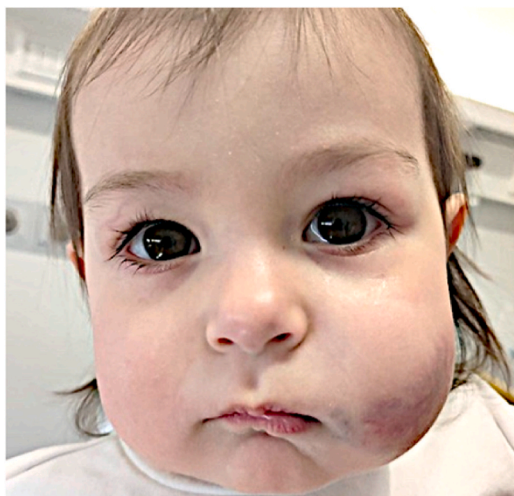
Fig. 2. 18-month-old patient presenting with a venous malformation involving the mucosal side of her left cheek.

peripharyngeal space); c) sclerotherapy of epicranial and neck component of the VM. During this procedure, J-Plasma® was used with a contactless application, as already described, to determine shrinkage of the nasopharyngeal portion of the malformation along with the oral and laryngopharyngeal segment under endoscopic guidance (Video 1). One month later, a laryngoscopy was performed, the lowest part of his pharynx appeared disease-free with normal mucosa, and of the nasopharyngeal portion of it had a near-complete shrinkage.

On another patient (Pt. 8), 2 surgical approaches were needed to treat a laryngopharyngeal venous malformation (Figs. 4 and 5). On this 20-year-old patient, J-Plasma® was used under laryngoscopy guidance to shrink and stiffen the superficial part of the malformation while bleomycin and polidocanol were used as sclerosing agents to reach the deeper part of the disease. A second specular session was performed 3 months after. Six months after, fiberoptic exam and an MRI showed complete resolution (Figs. 6 and 7).

The same J-Plasma® based technique was applied on an 18-month-old girl with a VM her left cheek (Pt.7) (Fig. 2). She underwent a procedure in which the superficial portion of the malformation was electrocoagulated exploiting the cold helium plasma beam of the device (Video 2) while intracameral percutaneous sclerotherapy was made under ultrasound guidance with polidocanol and bleomycin. Dramatic shrinkage in volume of the vascular malformation and a near complete disappearance of the mucosal component was assessed at one, three and six-month after the procedure (Fig. 8).

Supplementary data related to this article can be found online at <http://doi.org/10.1016/j.jcms.2025.02.024>

3.1. Evaluation of safety and results

Since the focus of this paper concerns the effectiveness of J-Plasma in the management of superficial VMs or the superficial component of more complex VMs, this will be the only focus. Evaluation of the success of treatment of adjacent areas involved by the disease was not done.

3.2. Intra and perioperative course

No major complications were observed. Mild bleeding did happen in 3 cases and required stitching the surface of the VM's laceration. No major bleeding happened, and no blood transfusion was needed.

Oedema was limited and did not affect the postoperative management.

No tissue necrosis took place.

Noteworthy, all 17 patients had the treated mucosa completely healed after just one week.

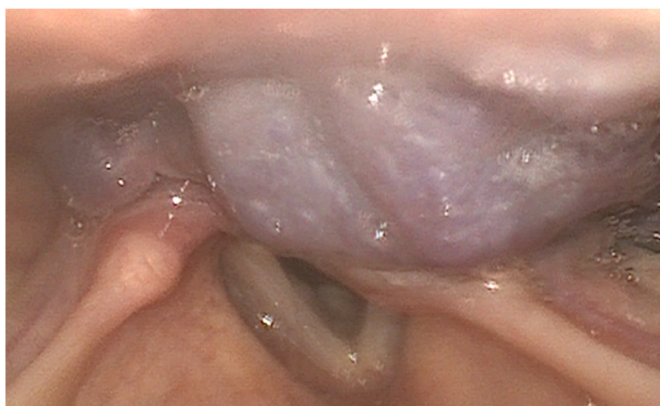

Fig. 4. Laryngopharyngeal venous malformation in a 20-year-old patient during a preoperative fibrolaryngoscopy.

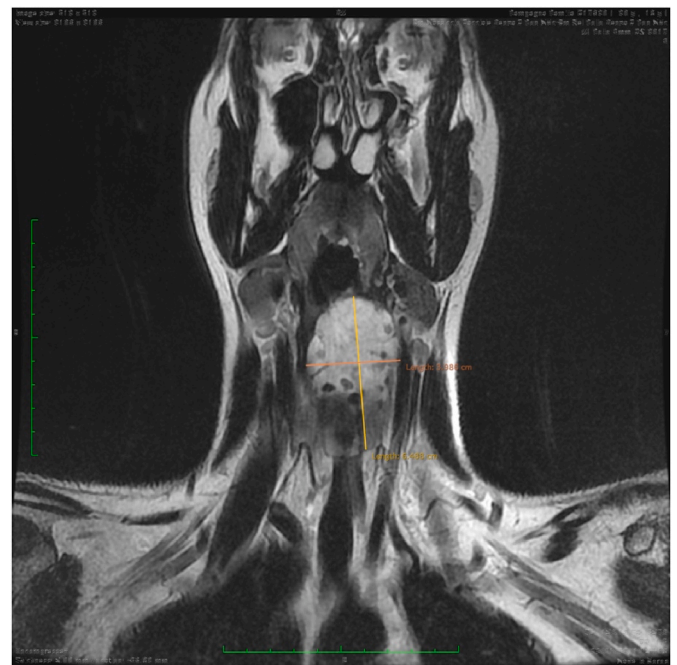


Fig. 5. Magnetic resonance image showing a laryngopharyngeal venous malformation of the same 20-year-old patient.

3.3. Short term results

After the end of the treatment cycle (see Table 1), at 1 and 3 months follow up the observe results were as follows: All Goyal's grade 1 and 2A cases had a 95–100% clearance. Remnants of the VM were just small discolorations of the mucosa. Goyal's 2B cases had major improvement (75–90%) with minor areas still involved by the disease.

Even the mucosal component of complex Goyal 3 cases had an excellent clearance of the VM (70–80%). However, in these patients, major residual disease was there in those areas not managed with J-Plasma (nasopharynx, posterior coanal region).

3.4. Mid-term results

At a 6 months follow-up, results were stable at the clinical and fiberoptic evaluation. On MRI a 70–100% clearance was detected. One Goyal 1 and 2 Goyal 2A had a complete resolution where a 70% reduction regarded all Goyal 3 cases.

One year after treatment all patients had the treated mucosal components stable. At the MRI, however, a partial disease relapse was detected in all Goyal 3 cases.

4. Discussion

The ideal treatment of VMs is still a matter of research. In fact, while isolated and confined ones are frequently managed straightforwardly (Goyal stage grade 1 and 2A), more extensive and ill-defined VMs and the ones involving sensible areas (Goyal stage grade 2B and 3) (Goyal et al., 2002) can be difficult and perilous. These ones are preferably treated in experienced, high-volume centers, in a multimodal setting (Colletti et al., 2014). Laser, sclerotherapy and surgery are all relied upon in these cases (Gregory et al., 2018; Patel et al., 2023). However, based on the preliminary result of this paper, it would seem that J-Plasma® could be an effective adjunct in some circumstances where it has significant advantages over “traditional” means. At times it can even be the sole required means.

Laser, specifically surface Nd:YAG is used to manage VMs and Interstitial Nd:YAG, based on fiberoptic transmission of the light is also

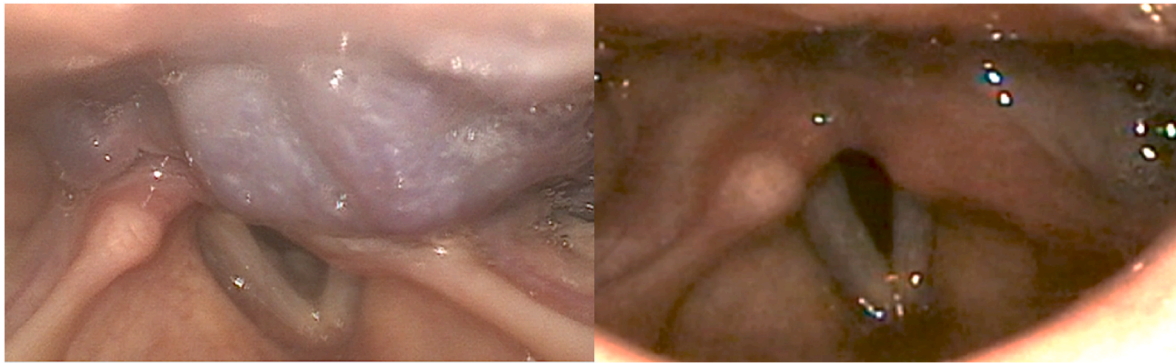


Fig. 6. Laryngopharyngeal venous malformation of the same 20-year-old patient, before and after combined J-Plasma® and sclerotherapy.

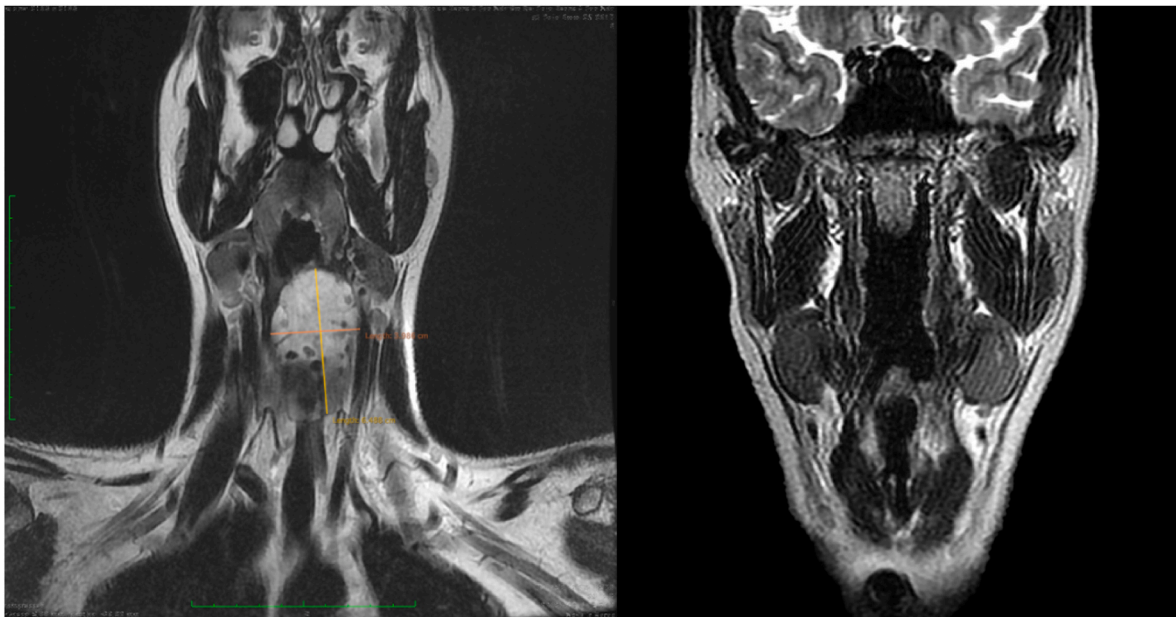


Fig. 7. Pre and post-operative T2-weighted MRI of the same patient.

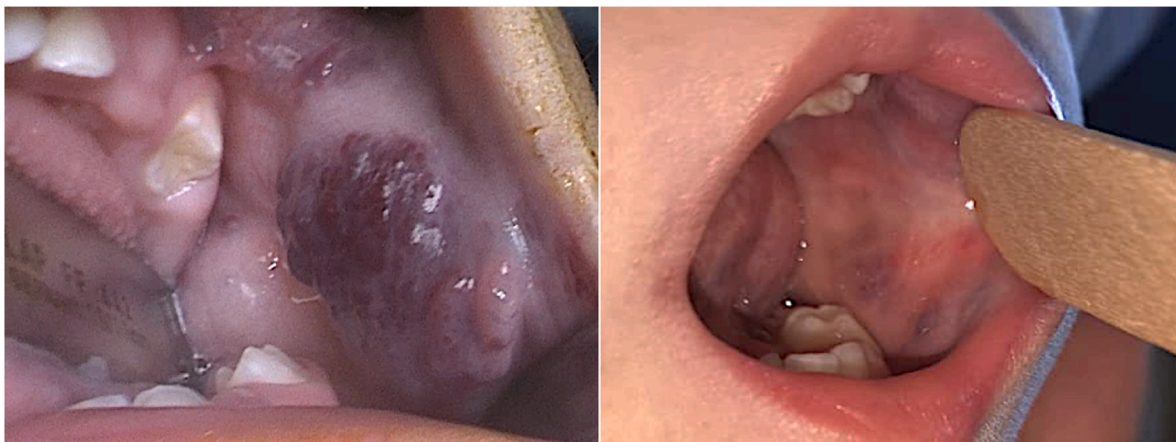

Fig. 8. Venous malformation involving the mucosal cheek of an 18-month-old patient, before and 6 months after a single procedure.

available (Buckmiller et al., 2010).

J-Plasma®, when the longer handpiece is used, can reach VMs as far localized as laryngeal ones. When used in the way described here, it does not need to be in contact with the mucosal surface hence minimizing the

risk of breakdown. Moreover, in our experience, ulceration and necrosis never took place, contributing to a faster healing and increased tolerability of treatment.

Sclerotherapy is routinely used in the management of extensive VMs,

and results appear often good. However, some drawbacks hold true for sclerotherapy as well. Aggressive sclerotherapy, leading to optimal results, can still produce necrosis of mucosal surfaces with subsequent ulceration and scarring. Even in the absence of complications, oedema and exfoliation can be a cause of severe discomfort as it takes weeks to subside (Greene and Ahmad, 2011). No such occurrences were experienced with J-Plasma®. In fact, quite surprisingly, all patients presented in this case series had a complete healing of the mucosal surface just one week after treatment.

Surgical excision continues to be a good therapeutic option and, in some cases, it can be considered the best cure. Excision of extensive lesions, however, remains a challenge as larger venous malformations are rarely well-defined lesions, and intraoperative bleeding can determine a difficult identification and preservation of noble structures (Buckmiller et al., 2010). Preoperative glue embolization can help (Greene and Ahmad, 2011; Parsa, 2015).

However, this approach is difficult to recommend for VMs involving the pharynx and larynx.

Other plasma technologies are available. It appears clear how avoiding unnecessary heat spread might be particularly useful when treating frail structures such as venous malformations (Filis et al., 2020). J-Plasma® has intrinsic bio-technical advantages over argon-based plasma devices: an argon unit has 18 electrons while helium only contains two, which means less energy is needed to ionize meanwhile allowing for a higher precision. Helium is also 10 times more thermally conductive than argon, granting to remove excessive heat from the surgical site. In addition, this device offers a retractable and rotating blade which enhances versatility and allows to target deeper structures when extended, cutting tissue with precision, and granting coagulation and controlled ablation when retracted.

In this study, cold helium plasma proved effective in the management of different categories of patients and on various types of venous malformation, from very extended ones to smaller ones, showing a particular efficacy on venous malformation that involve mucosal tissues. Furthermore, unique among devices suitable to treat VMs involving the surfaces, J-Plasma® allows to treat far located tissues such as the lower pharynx and larynx.

This device also seems able to reduce peri-operative complications, in particular bleeding, and no intraoperative complications or device-related adverse events occurred when using J-Plasma®.

Finally, mucosal surfaces heal outstandingly fast after being treated with this technology, potentially making it a better tolerated procedure as compared to traditional ones.

Because of its intrinsic technology, it also appeared time sparing since the surgeon does not need to redirect the device around as it automatically spreads the plasma beam towards low impedance tissues.

4.1. This study has limitations

The most important one is that all but 1 patient were treated in a multimodal approach leaning to sclerotherapy as the other means. It is difficult to demonstrate the relative advantage of the 2 in granting the results. However, 2 aspects led us to surmise that J-Plasma made a difference. First, in Goyal 3 cases, those areas not treated with J-Plasma had little improvements. Second, qualitatively comparing this cohort with previous cases managed by the same group, a dramatic difference can be observed. However, this is just a subjective measure, and a more thorough comparison is desirable.

5. Conclusion

The employment of J-Plasma® in treating venous malformations is promising. It appears easy to use and effective, as our initial hypothesis is being confirmed: the helium plasma beam is able to autonomously target venous malformations and diffuse directly to the disease, without breaking its thin walls, hence reducing the risk of bleeding, and at the

same time thickening its surface. The use of this device does not aim to replace other treatments, such as laser and sclerotherapy or surgical procedures, but when paired with these more standard methods, it may lead to a more satisfying and extended result, providing the operator with a valid technique when accessing these diseases. In selected cases it can be the sole required means.

Our study aims to report a qualitative evaluation that we assessed when using this device, especially in terms of absence of complications that could be directly referred to J-Plasma®, but also in terms of fast healing recovery and ease of use by the operator.

It may be of interest to carry out a further study to compare the efficacy of lasertherapy and J-Plasma® on venous malformations and to compare their handiness.

There are some limitations to our study, especially a small sample size, use of combination techniques together with the J-Plasma® and their consequent potential impact. Nevertheless, in our 17 patients series, we have found that combining these modalities appear safe and effective from a qualitative point of view. This study may serve as groundwork for future prospective ones that may aim to explore the utilization of this device on other vascular malformations.

Funding

This research did not receive any specific grant from funding agencies in the public, commercial, or not-for-profit sectors.

Conflict of interest statement

The authors have no funding, financial relationship, or conflicts of interest to disclose.

References

- Alletti, Gueli, Salvatore, Rosati, Andrea, Andrea Capozzi, Vito, Pavone, Matteo, Gioè, Alessandro, Cianci, Stefano, Chiantera, Vito, Vizzielli, Giuseppe, Scaglione, Giulia, Fagotti, Anna, Scambia, Giovanni, 2022. Use of laparoscopic and laparotomic J-plasma handpiece in gynecological malignancies: results from a Pilot study in A tertiary care center. *Front. Oncol.* 12. <https://doi.org/10.3389/FONC.2022.868930>.
- Bertino, F., Trofimova, A.V., Gilyard, S.N., Hawkins, C.M., 2021. Vascular anomalies of the head and neck: diagnosis and treatment. *Pediatr. Radiol.* 51 (7), 1162–1184. <https://doi.org/10.1007/s00247-021-04968-2>. Epub 2021 Apr 16. PMID: 33860862.
- Buckmiller, L.M., Richter, G.T., Suen, J.Y., 2010. Diagnosis and management of hemangiomas and vascular malformations of the head and neck. *Oral Dis.* 16 (5), 405–418. <https://doi.org/10.1111/J.1601-0825.2010.01661.X>.
- Carqueja, I.M., Sousa, J., Mansilha, A., 2018. Vascular malformations: classification, diagnosis and treatment. *Int. Angiol.* 37 (2), 127–142. <https://doi.org/10.23736/S0392-9590.18.03961-5>. Epub 2018 Feb 8. PMID: 29424187.
- Colletti, Giacomo, Ierardi, Anna Maria, 2017. Understanding venous malformations of the head and neck: a comprehensive insight. *Med. Oncol.* 34 (3). <https://doi.org/10.1007/s12032-017-0896-3>.
- Colletti, Giacomo, Valassina, Davide, Bertossi, Dario, Melchiorre, Fabio, Vercellio, Gianni, Brusati, Roberto, 2014. Contemporary management of vascular malformations. *J. Oral Maxillofac. Surg. : Offic. J. Am. Asso. Oral Maxillofacial Surge.* 72 (3), 510–528. <https://doi.org/10.1016/J.JOMS.2013.08.008>.
- Doolabh, Vaishali, 2019. A single-site postmarket retrospective chart review of subdermal coagulation procedures with renuvion. *Plastic Reconstruc. Surgery. Global Open* 7 (11). <https://doi.org/10.1097/GOX.0000000000002502>.
- Filis, Konstantinos, George, Galyfos, Sigala, Fragiska, Zografos, Georgios, 2020. Utilization of low-temperature helium plasma (J-Plasma) for dissection and hemostasis during carotid endarterectomy. *J. Vascular Surgery Cases Innov. Techniq.* 6 (1), 152–155. <https://doi.org/10.1016/J.JVSCIT.2020.01.008>.
- Fowell, C., Vereia Linares, C., Jones, R., Nishikawa, H., Monaghan, A., 2017. Venous malformations of the head and neck: current concepts in management. *Br. J. Oral Maxillofac. Surg.* 55 (1), 3–9. <https://doi.org/10.1016/j.bjoms.2016.10.023>. Epub 2016 Nov 25. PMID: 27894790.
- Gay-Mimbrera, Jesús, García, María Carmen, Isla-Tejera, Beatriz, Rodero-Serrano, Antonio, García-Nieto, Antonio Vélez, Ruano, Juan, 2016. Clinical and biological principles of cold atmospheric plasma application in skin cancer. *Adv. Ther.* 33 (6), 894–909. <https://doi.org/10.1007/S12325-016-0338-1>.
- Gentile, Richard D., 2018. Cool atmospheric plasma (J-Plasma) and new options for facial contouring and skin rejuvenation of the heavy face and neck. *Facial Plast. Surg.* 34 (1), 66–74. <https://doi.org/10.1055/s-0037-1621713>.
- Goyal, Mayank, Causer, Petrina A., Armstrong, Derek, 2002. Venous vascular malformations in pediatric patients: comparison of results of alcohol sclerotherapy

- with proposed MR imaging classification. *Radiology* 223 (3), 639–644. <https://doi.org/10.1148/radiol.2233010025>.
- Greene, Arin K., Ahmad, I. Alomari, 2011. Management of venous malformations. *Clin. Plast. Surg.* 38 (1), 83–93. <https://doi.org/10.1016/J.CPS.2010.08.003>.
- Gregory, Stacie, Burrows, Patricia E., Ellinas, Herodotos, Stadler, Michael, Chun, Robert H., 2018. Combined Nd:YAG laser and bleomycin sclerotherapy under the same anesthesia for cervicofacial venous malformations: a safe and effective treatment option. *Int. J. Pediatr. Otorhinolaryngol.* 108, 30–34. <https://doi.org/10.1016/j.ijporl.2018.02.005>.
- Hirst, Adam M., Frame, Fiona M., Maitland, Norman J., Connell, Deborah O., 2014. Low temperature plasma: a novel focal therapy for localized prostate cancer? *BioMed Res. Int.* <https://doi.org/10.1155/2014/878319>, 2014.
- Masghati, Salome, Pedroso, Jasmine, Gutierrez, Melissa, Stockwell, Erica, Warren Volker, K., Howard, David L., 2019. Comparative thermal effects of J-plasma®, monopolar, argon, and laser electrosurgery in a porcine tissue model. *Surg. Technol. Int.* 34, 35–39.
- Parsa, M., 2015. “Retropertoneal dissection of ovarian endometrioma using J-plasma technology”. *J. Minim. Invasive Gynecol.* 22 (6S). <https://doi.org/10.1016/J.JMIG.2015.08.475>. S140.
- Patel, Neha A., Bonilla-Velez, Juliana, Rosenberg, Tara L., Siegel, David, Shivaram, Giri, Chun, Robert H., Waner, Milton, Teresa, M.O., Chen, Itay, Moon, Rony, Richter, Gresham T., Perkins, Jonathan A., 2023. American society of pediatric otolaryngology vascular anomalies task force review of tongue venous malformations: techniques, pearls, and pitfalls. *Int. J. Pediatr. Otorhinolaryngol.* 167, 111497. <https://doi.org/10.1016/j.ijporl.2023.111497>.
- Seront, Emmanuel, Vikkula, Miikka, Boon, Laurence M., 2018. Venous malformations of the head and neck. *Otolaryngol. Clin.* 51 (1), 173–184.
- Theodoulidis, Vasilios, Prodromidou, Anastasia, Stamatakis, Emmanouil, Alexakis, Nicholas, Rodolakis, Alexandros, Haidopoulos, Dimitrios, 2022. Application of J-plasma in the excision of diaphragmatic lesions as part of complete cytoreduction in patients with advanced ovarian cancer. *Mole. Clin. Oncol.* 17 (1). <https://doi.org/10.3892/MCO.2022.2546>.