

This is the peer reviewed version of the following article:

Renal Manifestations of Hepatitis C Virus / Ferri, Clodoveo; Giuggioli, Dilia; Colaci, Michele. - In: CLINICS IN LIVER DISEASE. - ISSN 1089-3261. - 21:3(2017), pp. 487-497. [10.1016/j.cld.2017.03.005]

Terms of use:

The terms and conditions for the reuse of this version of the manuscript are specified in the publishing policy. For all terms of use and more information see the publisher's website.

04/05/2026 03:03

(Article begins on next page)

Renal Manifestations of Hepatitis C Virus

Clodoveo Ferri, MD^{*}, Dilia Giuggioli, MD, Michele Colaci, MD

KEY POINTS

Hepatitis C virus (HCV) is both a hepatotropic and lymphotropic virus responsible for a spectrum of hepatic and extrahepatic immune-mediated and neoplastic disorders, including renal involvement.

HCV-infected patients should undergo careful clinicoserologic assessment at the first referral followed by constant monitoring to detect possible organ involvement early, including renal involvement.

HCV-related nephropathy may show different histopathologic patterns, more often a membranoproliferative glomerulonephritis, which may appear at any time during the natural history of HCV infection.

Renal involvement may develop as isolated manifestation or in association with other HCV-related disorders, mainly mixed cryoglobulinemia syndrome (MCS).

New direct-acting viral agents (DAAs) represent the first-line treatment of HCV-related nephropathy; other pathogenetic therapies (steroids/immunosuppressors/plasmapheresis) may be usefully used for rapidly progressive glomerulonephritis.

INTRODUCTION

HCV is a hepatotropic and lymphotropic virus responsible for a wide spectrum of both hepatic and extrahepatic diseases.¹⁻³ The HCV-related extrahepatic manifestations (HCV-EHMs) include nonorgan and organ-specific autoimmune/lymphoproliferative and neoplastic disorders (Fig. 1).^{2,3} MCS, also termed cryoglobulinemic vasculitis, represents the prototype of extrahepatic systemic immune-mediated disorder characterized by multiple organ involvement.¹⁻³ The authors previously introduced the term, *HCV syndrome* (see Fig. 1), to refer to the multiform complex of HCV-related diseases.^{1,3} In this scenario, HCV-related renal involvement is one of the most severe

HCV-EHMs; it includes a broad spectrum of kidney histopathologic lesions, mostly the membrane-proliferative glomerulonephritis (MPGN).

Clinically, patients with HCV nephropathy may be totally asymptomatic, showing only mild urinary abnormalities; on the other hand, renal insufficiency, up to end-stage renal failure requiring kidney transplant, may represent a possible harmful evolution.⁴⁻⁶ Overall, HCV infection per se has been clearly recognized as an independent risk factor for kidney damage, even if some possible comorbidities, such as diabetes mellitus or other metabolic disorders, may be also involved.⁷

The actual prevalence of renal involvement in HCV-infected patients is difficult to estimate, because of the large heterogeneity of reported case series, in terms of both geographic provenience and subspecialty referral (see Fig. 1); in the setting of HCV-related MCS, previous cohort studies showed a fairly constant percentage of approximately a third of patients with complicating nephropathy.^{8,9}

HEPATITIS C VIRUS-ASSOCIATED RENAL DISEASE

Histopathologic Features

HCV-related renal damage may include several histopathologic patterns, with possible glomerular and/or interstitial lesions.^{4,10,11} As shown in Table 1, MPGN type 1 is the most typical and frequent pathologic entity. This renal manifestation may be in the context of the clinical picture of MCS; on the other hand, MPGN may appear as unique or clinically relevant organ involvement as part of the HCV syndrome, regardless of the presence/absence of detectable serum mixed cryoglobulins.

Etiopathogenesis

Kidney injury may be the result of 2 main processes, not mutually exclusive: immune-mediated tissue damage and HCV direct effects (Fig. 2). Moreover, other unknown environmental and/or host factors, such as genetic background, and/or other concomitant severe manifestations (decompensated cirrhosis, widespread cryoglobulinemic vasculitis, and/or comorbidities, such as diabetes) may contribute to renal damage.⁴⁻¹¹

The renal deposition of cryoprecipitable and noncryoprecipitable immune complexes containing HCV antigens is the main pathogenetic mechanism of the glomerular inflammation, even if the virus may directly contribute to tissue damage by infecting the endothelium, tubular epithelial cells, and infiltrating leukocytes.^{6,10,11}

Mixed cryoglobulins that circulate in the arteriolar vessels may deposit in the mesangium after the active crossing through the endothelial barrier, during the macromolecular trafficking in the

glomeruli. Immunofluorescence reveals subendothelial IgM deposits; sometimes, immune complexes also occlude capillary lumen as dense

eosinophilic deposits.^{6,10,11} The strong affinity of the IgM with rheumatoid activity for cellular fibronectin in the mesangium is considered a cause of nephrotoxicity.¹¹ Moreover, the immune complexes produce vasculitis, via complement activation, with fibrinoid necrosis of the glomerular vessels. On the other hand, endothelial cells overexpress adhesion molecules that recruit inflammatory cells; platelet activation and aggregation complete this pathologic process. Finally, if capillary damage results, cryoglobulins may pass into the urinary space, contributing to the development of crescents and tubular casts.

In cases of noncryoglobulinemic immune complexes, anti-HCV IgG deposits and complement fragments may be found in the mesangium, leading to MPGN.^{6,10,11} Furthermore, immunoglobulins with antiendothelial activity may also stimulate cell activation and injury.

Endothelial damage may be determined by the direct effect of HCV, as observed in the hepatic sinusoids where cell apoptosis is induced by the virus. Also, epithelial cells from the Bowman capsule may be infected by HCV that eventually causes the loss of podocytes as well as the cells of renal tubules.^{6,10,11} Finally, a direct effect of the virus on mesangial cells cannot be excluded.

Clinical Aspects

Patients with HCV-related nephropathy may present a variety of clinical features, including both typical renal symptoms and 1 or more possible extrarenal manifestations⁴⁻¹¹; in particular, they may be totally asymptomatic with occult urinary abnormalities or with the multiform manifestations of cryoglobulinemic vasculitis (see [Figs. 1 and 2](#)). For descriptive purposes, the following main clinical patterns can be identified.

Isolated hepatitis C virus–related renal disease

Patients with isolated MPGN or other less frequent renal conditions⁴ generally present with microscopic hematuria and mild proteinuria, associated with variable impairment of renal function; the latter is reported in approximately 10% of HCV-infected individuals in a large US cohort.¹² In more severe cases, higher amounts of proteinuria led to nephrotic syndrome or, less commonly, to acute nephritic syndrome, acute renal failure, and/or oligo-anuria in a few instances. These conditions may be responsible for a variable degree of edema, pericardial or pleural effusion, and/or hypertension with possible end-organ damage.

Renal involvement plus other hepatitis C virus extrahepatic manifestations

The clinical pattern, renal involvement plus other HCV extra-hepatic manifestations, encompasses a heterogeneous group of extrarenal disorders, namely different organ-specific and non-organ-specific autoimmune diseases or neoplastic complications that characterize the HCV syndrome (see [Fig. 1](#); discussed previously).³ HCV may persistently infect several cell types, including lymphocytes and epithelial and glandular cells, triggering autoimmune processes that may lead to thyroiditis, arthritis, sialadenitis, diabetes, myocarditis, and so forth. On the other hand, HCV may facilitate lymphomagenesis as a consequence of its persistent antigenic stimulation and/or direct oncogenic potential.^{1-3,13} The more frequent types of hematological malignancy are diffuse large B-cell, lymphoplasmacytic, and marginal zone non-Hodgkin lymphomas.

In this scenario, it is often difficult to completely define the exact clinical pattern of a single patient because of the complex overlap between different HCV-related disorders; in these instances, a

multidisciplinary approach is opportune for a comprehensive patient assessment and tailored treatment (Fig. 3). Therefore, a systematic clinico-serologic evaluation of HCV patients is mandatory, according to proposed guidelines (discussed later).¹⁴

Renal involvement and cryoglobulinemic vasculitis

In the setting of HCV-EHMs, the MCS (cryoglobulinemic vasculitis) represents one of the most complex and harmful manifestations that may be complicated by renal involvement.^{1-3,8}

MCS is the prototype of systemic autoimmune disease related to chronic HCV infection.^{1-3,8} It is classically characterized by cutaneous leukocytoclastic vasculitis; the classic clinical triad of palpable orthostatic purpura, asthenia, and arthralgias; and possible multiorgan involvement.^{1-3,8} The MC-associated nephropathy, mainly MPGN due to glomerul deposition of cryoprecipitable immune complexes (see Table 1), may represent the main clinical feature in approximately one-third of cases. In these patients, other autoimmune disorders can be clinically relevant, including the increased risk of non-Hodgkin lymphoma; they may contribute to renal damage and may severely affect the overall prognosis.^{6,8}

Renal dysfunction in hepatitis C virus–related liver cirrhosis

Patients with advanced liver damage, mainly decompensated cirrhosis, may develop acute renal failure, the classic hepatorenal syndrome, a life-threatening condition that may require dialysis and liver transplant.¹⁵ The hepatorenal syndrome is considered a consequence of splanchnic vasodilation due to portal hypertension with renal hypoperfusion. The activation of the renin-angiotensin-aldosterone system ultimately produces prerenal azotemia, which may progress to acute or chronic tubular necrosis.^{6,15} The renal involvement secondary to decompensated cirrhosis may also precipitate a contemporary/preexisting immune-mediated glomerulonephritis in HCV-infected patients.

Other comorbidities, such as diabetes or ongoing treatments (immunosuppressors/ corticosteroids), may contribute to renal injury.

DIAGNOSIS

All HCV-infected patients should routinely undergo urinalysis, including sediment evaluation, to identify the clinical onset of possible renal disease early (see Fig. 3).^{4,14} Renal involvement in HCV patients may be easily suspected in the presence of urinary abnormalities, edema, hypertension, proteinuria, and/or increased serum creatinine (see Fig. 3).^{4,14} Patients with these presenting symptoms are firstly referred to a nephrologist (see Figs. 1 and 3). Ultrasound kidney evaluation often reveals cortical hyperechogenicity and loss of cortical-medullar differentiation, whereas urinary sediment may contain dysmorphic erythrocytes due to their crossing through damaged glomeruli. Renal needle biopsy is mandatory to histologically assess glomerular/interstitial patterns, including the immunofluorescence studies (see Table 1). Glomerulonephritis may complicate the clinical pattern in MC patients or subjects affected by other autoimmune or neoplastic HCV-related disorders, requiring a multidisciplinary patient assessment (see Fig. 3).

PROGNOSIS

It is difficult to evaluate the prognosis of HCV-related nephropathy because of the complexity of the clinical spectrum of HCV syndrome and possible comorbidities.¹⁻³ Besides the careful evaluation of the severity/activity of histopathologic alterations, the prognostic value of renal involvement should be contextualized in the entire clinical pattern presented by a single patient.

Moreover, the impact of chronic kidney disease in HCV patients with increased risk of cardiovascular complications (severe arrhythmia, congestive heart failure, and death) has been evaluated in a large US population diagnosed between 2004 and 2014.¹⁶ Negative prognostic factors were the higher rates of hypertension and diabetes observed in HCV patients with renal involvement compared with those without.¹² In this context, a direct pathogenetic role of the virus in the development of endothelial dysfunction has been hypothesized; HCV may induce a chronic inflammation that in turn may induce the development of diffuse atherosclerosis.¹⁷

The impact of persistent HCV infection per se on chronic kidney disease is relevant; lower survival rates in dialyzed populations^{5,7} were reported, with hepatocellular carcinoma and liver cirrhosis frequent causes of death. A review, including 18 observational studies, showed that HCV-infected renal transplant recipients have worse outcomes (mortality and graft loss) than HCV-negative recipients with HCV infection as an independent risk factor for graft loss and increased mortality.¹⁸ Overall, the survival of patients with kidney transplant was significantly lower in the HCV-positive patients than in the HCV-negative patients.¹⁹

For patients with HCV-related renal disease, the risk of progression to end-stage renal failure is correlated with patient age, serum creatinine level, and proteinuria at the time of histologic diagnosis.⁴

Finally, renal involvement is one of the most harmful complications in MCS and may severely affect a patient's clinical outcome; a survival study demonstrated that renal failure caused by chronic glomerulonephritis was responsible for death in one-third of deceased MC patients.⁸

TREATMENT

Considering the complex, multistep etiopathogenesis of HCV-related disorders, the therapeutic strategy of HCV-related nephropathy, as well as of other HCV-EHMs, is essentially based on 3 main levels of intervention (see Fig. 1): the etiologic treatment by means of antivirals directed at HCV eradication, the pathogenetic therapies with immunomodulating-immunosuppressive agents, and the pathogenetic/symptomatic therapies, such as corticosteroids, plasmapheresis, and antiinflammatory/analgesic drugs.²⁰

The antiviral therapy for HCV, formerly based on the association of pegylated interferon alpha and ribavirin, has been recently revolutionized by the availability of new DAAs.^{21–23} These agents, variably combined, with or without ribavirin, permit avoiding the harmful side effects of interferon, mainly in patients affected by autoimmune disorders (ie, neuropathy and thyroiditis). The stronger antiviral activity of DAAs and better adherence to therapeutic protocols have permitted high successful eradication rates. Therefore, the eradication of HCV is considered a mainstay of the treatment of patients affected by virus-related hepatic or extrahepatic disorders.^{1,20} It can be assumed that the elimination of the principal etiologic factor may interrupt the complex autoimmune process underlying different manifestations of HCV syndrome (Fig. 4).

The actual role of DAAs in HCV-related kidney disease needs to be further studied. Among the currently approved DAAs, sofosbuvir is the only one that has significant renal elimination. The other DAAs (simeprevir, ledipasvir, daclatasvir, paritaprevir/ritonavir, ombitasvir, dasabuvir, grazoprevir, and elbasvir) are not eliminated by the kidneys and thus do not need dose adjustment, even in patients with severe renal impairment.

Besides the etiologic therapy, various pathogenetic/symptomatic treatments may be used to control different HCV-EHMs, alone or in concomitance (see Fig. 4).^{2,20}

The immunologic/pathogenetic therapies include the use of rituximab, a monoclonal anti-CD20 antibody, to reduce B-lymphocyte overexpression.²⁴ This biologic agent was revealed as particularly effective in HCV-related extrahepatic autoimmune manifestations, including glomerulonephritis, showing a generally safe profile, particularly at a dose of 375 mg/m² a week for 4 consecutive weeks (see Fig. 4).^{23,24}

Other immunosuppressive agents potentially effective for HCV-related renal disease are corticosteroids, cyclophosphamide, and plasma exchange, alone or as combination therapy (see Fig. 4). This approach may represent a prompt, useful treatment of recent-onset, rapidly progressive glomerulonephritis; sensory-motor peripheral neuropathy; and/or severe life-threatening vasculitis.²⁰ Corticosteroids may be used in a wide range of dosages; low-dose corticosteroids may be sufficient for mild to moderate HCV-EHMs, such as purpura, arthralgias/arthritis, and so forth.²⁰ Finally, plasma exchange (or double-filtration plasmapheresis for patients with cryoglobulinemic vasculitis) still represents an effective and safe therapeutic approach, usually in association with other immunosuppressors, to avoid the possible rebound of circulating cryoprecipitable and noncryoprecipitable immune complex levels.

In all cases, the presence of some adverse prognostic factors should be carefully evaluated before the therapeutic decisions; in particular, the severity of liver involvement with decompensated cirrhosis, diffuse cryoglobulinemic vasculitis with multiple-organ damage, and some important comorbidities, such as diabetes, heart/lung involvement, cancer, and possible HBV/HIV coinfection.

In conclusion, the etiologic treatment with DAAs, alone or in combination with immunosuppressors, may represent the gold standard therapy that may lead to HCV eradication and possible improvement or complete resolution of HCV-EHMs. Preliminary trials regarding small patients series with short clinical follow-up after HCV eradication showed somewhat discordant results.^{21–23} Unfortunately, there are not available predictive factors for therapeutic effects of antivirals in the single patient; the unpredictable results might be related to different steps of the HCV-related immune-system condition underlying the HCV-EHMs in a given subject at the time of antiviral therapy; it is possible to hypothesize that in some individuals lymphoproliferative alterations might have passed the point of no return and are not yet reversible despite virus

eradication. Therefore, the actual role of antivirals in the natural history of HCV-EHMs can be clarified in the near future by means of clinical trials on wider patients' series with homogeneous clinico-immunologic patterns, including HCV-related glomerulonephritis alone or in association with MCS or other HCV-EHMs.

REFERENCES

1. Ferri C, Sebastiani M, Giuggioli D, et al. Hepatitis C virus syndrome: a constellation of organ- and non-organ specific autoimmune disorders, B-cell non-Hodg-kin's lymphoma, and cancer. *World J Hepatol* 2015;7:327–43.
2. Zignego AL, Gragnani L, Piluso A, et al. Virus-driven autoimmunity and lymphoproliferation: the example of HCV infection. *Expert Rev Clin Immunol* 2015;11: 15–31.
3. Ferri C, Antonelli A, Mascia MT, et al. HCV-related autoimmune and neoplastic disorders: the HCV syndrome. *Dig Liver Dis* 2007;39(Suppl 1):S13–21.
4. Roccatello D, Fornasieri A, Giachino O, et al. Multicenter study on hepatitis C virus-related cryoglobulinemic glomerulonephritis. *Am J Kidney Dis* 2007;49: 69–82.
5. Cacoub P, Desbois AC, Isnard-Bagnis C, et al. Hepatitis C virus infection and chronic kidney disease: time for reappraisal. *J Hepatol* 2016;65(1 Suppl):S82–94.
6. Barsoum RS, William EA, Khalil SS. Hepatitis C and kidney disease: a narrative review. *J Adv Res* 2017;8:113–30.
7. Fabrizi F, Martin P, Dixit V, et al. Hepatitis C virus infection and kidney disease: a meta-analysis. *Clin J Am Soc Nephrol* 2012;7:549–57.
8. Ferri C, Sebastiani M, Giuggioli D, et al. Mixed cryoglobulinemia: demographic, clinical, and serologic features and survival in 231 patients. *Semin Arthritis Rheum* 2004;33:355–74.
9. Terrier B, Cacoub P. Renal involvement in HCV-related vasculitis. *Clin Res Hepatol Gastroenterol* 2013;37:334–9.
10. Ozkok A, Yildiz A. Hepatitis C virus associated glomerulopathies. *World J Gastroenterol* 2014;20:7544–54.
11. Fabrizi F, Plaisier E, Saadoun D, et al. Hepatitis C virus infection, mixed cryoglobulinemia, and kidney disease. *Am J Kidney Dis* 2013;61:623–37.
12. Moorman AC, Tong X, Spradling PR, et al. Prevalence of renal impairment and associated conditions among HCV-infected persons in the chronic hepatitis

cohort study (CHeCS). *Dig Dis Sci* 2016;61:2087–93.

13. Vannata B, Arcaini L, Zucca E. Hepatitis C virus-associated B-cell non-Hodgkin's lymphomas: what do we know? *Ther Adv Hematol* 2016;7:94–107.
14. Ferri C, Ramos-Casals M, Zignego AL, et al, ISG-EHCV coauthors. International diagnostic guidelines for patients with HCV-related extrahepatic manifestations. A multidisciplinary expert statement. *Autoimmun Rev* 2016;15:1145–60.
15. Pipili C, Cholongitas E. Renal dysfunction in patients with cirrhosis: where do we stand? *World J Gastrointest Pharmacol Ther* 2014;5:156–68.
16. Tartof S, Arduino JM, Wei R, et al. The additional impact of chronic kidney disease on cardiovascular outcomes and death among HCV patients. Poster presented at the EASL Meeting. Barcelona, Spain, April 15, 2016.
17. Oyake N, Shimada T, Murakami Y, et al. Hepatitis C virus infection as a risk factor for increased aortic stiffness and cardiovascular events in dialysis patients. *J Nephrol* 2008;21:345–53.
18. Rostami Z, Nourbala MH, Alavian SM, et al. The impact of Hepatitis C virus infection on kidney transplantation outcomes: a systematic review of 18 observational studies: the impact of HCV on renal transplantation. *Hepat Mon* 2011;11:247–54.
19. Amir AA, Amir RA, Sheikh SS. Hepatitis C infection in kidney transplantation. In: Rath T, editor. *Current issues and future direction in kidney transplantation*. In-Tech; 2013. Available at: <https://www.intechopen.com/books/current-issues-and-future-direction-in-kidney-transplantation/hepatitis-c-infection-in-kidney-transplantation>. Accessed April 11, 2017.
20. Pietrogrande M, De Vita S, Zignego AL, et al. Recommendations for the management of mixed cryoglobulinemia syndrome in hepatitis C virus-infected patients. *Autoimmun Rev* 2011;10:444–54.
21. Sise ME, Bloom AK, Wisocky J, et al. Treatment of hepatitis C virus-associated mixed cryoglobulinemia with direct-acting antiviral agents. *Hepatology* 2016; 63:408–17.
22. Gragnani L, Visentini M, Fognani E, et al. Prospective study of guideline-tailored therapy with direct-acting antivirals for hepatitis C virus-associated mixed cryoglobulinemia. *Hepatology* 2016;64:1473–82.

23. Fabrizi F, Martin P, Cacoub P, et al. Treatment of hepatitis C-related kidney disease. *Expert Opin Pharmacother* 2015;16:1815–27.
24. Ferri C, Cacoub P, Mazzaro C, et al. Treatment with rituximab in patients with mixed cryoglobulinemia syndrome: results of multicenter cohort study and review of the literature. *Autoimmun Rev* 2011;11:48–55.

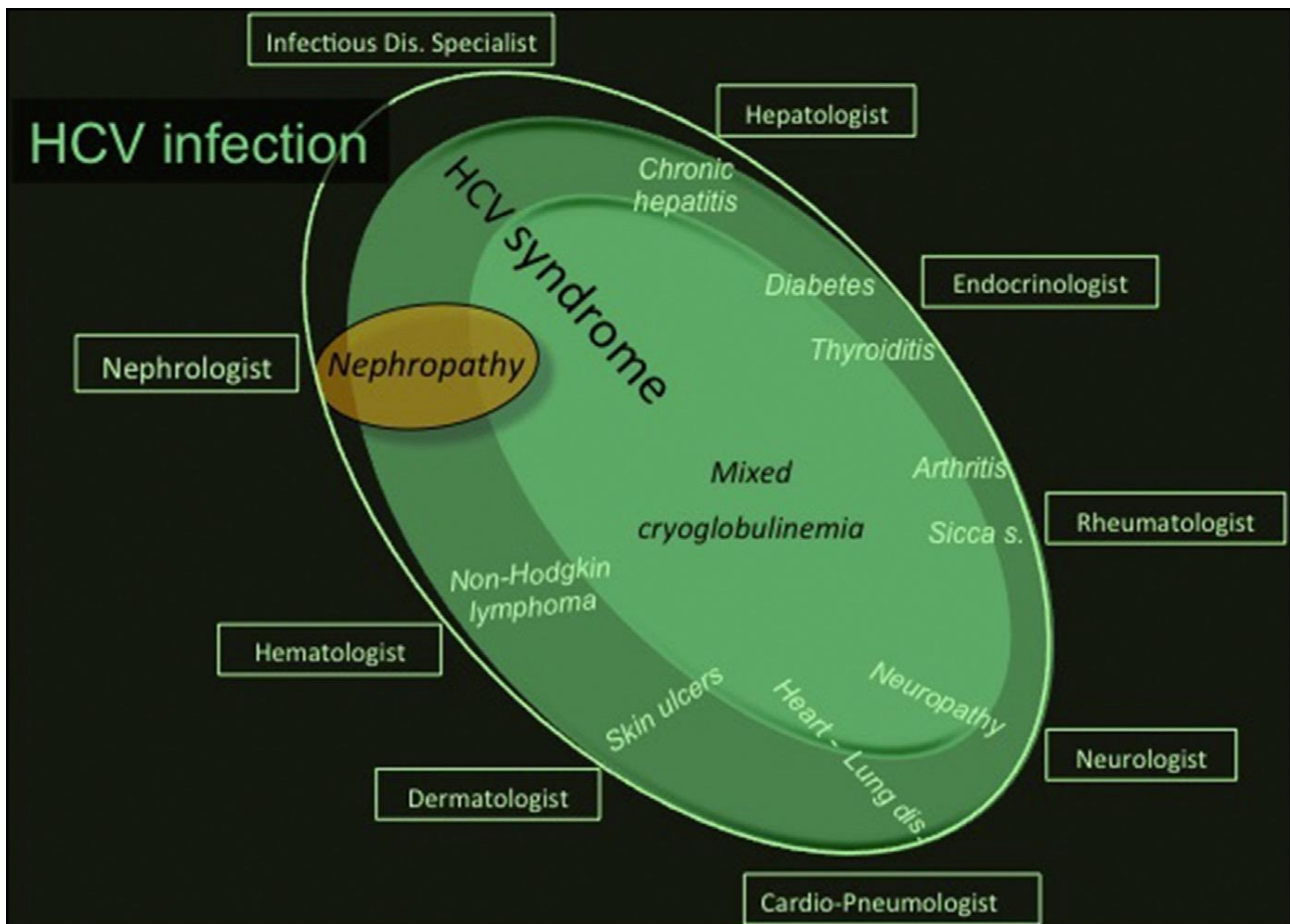


Fig. 1. Renal involvement and HCV infection. The figure schematically reproduces the spectrum of HCV infection and diseases. HCV is a hepatotropic and lymphotropic virus responsible for a wide spectrum of both hepatic and extrahepatic diseases. The term HCV syndrome refers to the multiform complex of all HCV-related diseases. Besides HCV-infected patients without clinical manifestations or isolated liver involvement, HCV-EHMs may include a variety of nonorgan and organ-specific autoimmune/lymphoproliferative and neoplastic disorders; therefore, HCV-positive patients are commonly referred to different specialists according the prevalent clinical manifestation(s). MCS, also termed cryoglobulinemic vasculitis, represents the prototype of extrahepatic systemic immune-mediated disorder characterized by multiple organ involvement. In this scenario, HCV-related renal involvement is one of the most severe HCV-EHMs; it may present as apparently isolated condition or in association with other HCV-EHMs, mainly MCS. dis, diseases; sicca s, sick syndrome/Sjogren's syndrome.

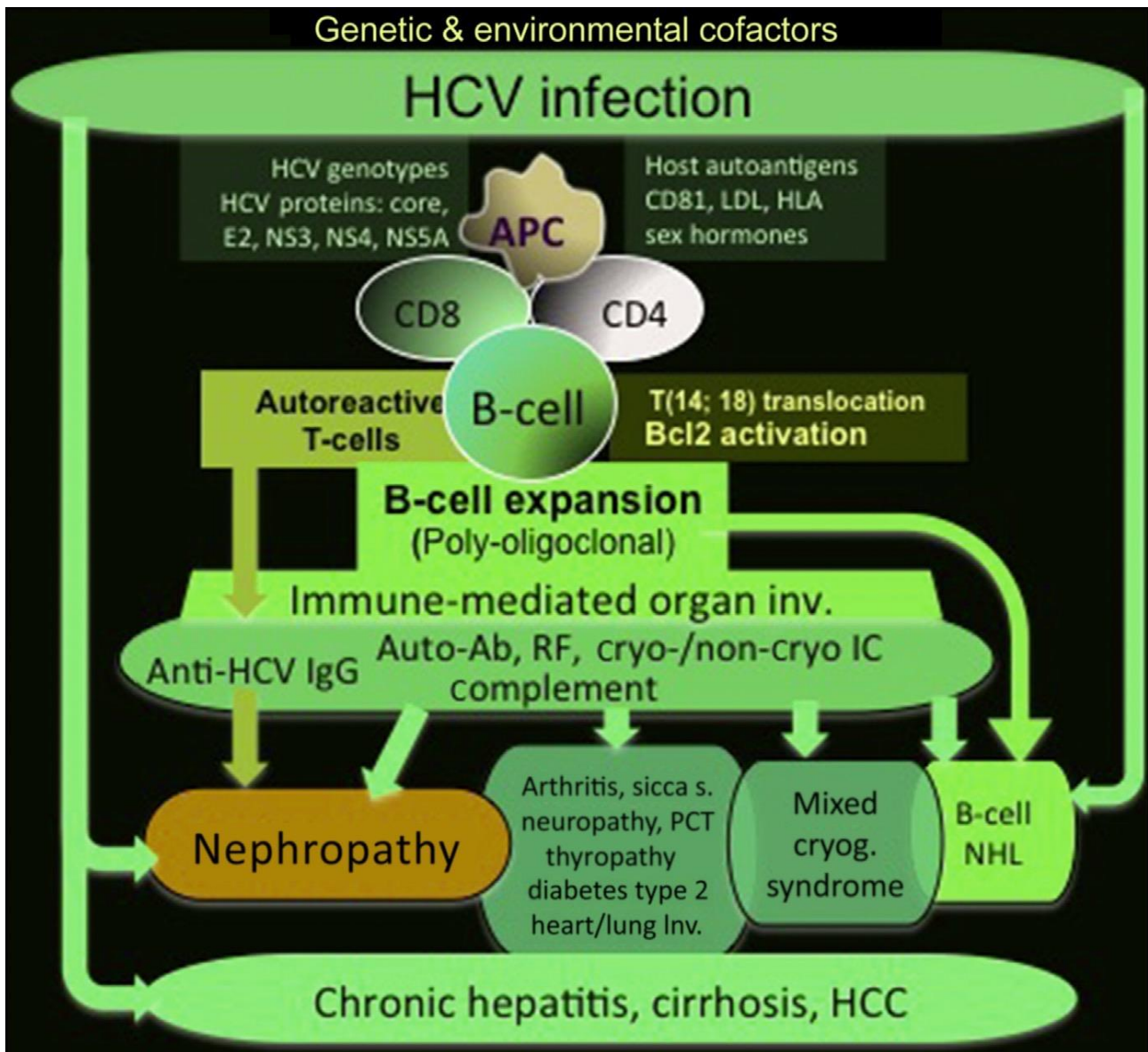


Fig. 2. Etiopathogenesis of HCV-related diseases. Kidney involvement may be the result of 2 main processes, not mutually exclusive: immune-mediated tissue damage and HCV direct injury. In addition, other unknown environmental and/or host predisposing factors (genetic background, and/or concomitant severe manifestations, such as decompensated cirrhosis or diabetes) may contribute to renal damage. The HCV lymphotropism represents the main pathogenetic mechanism of HCV-related clinical manifestation, including the nephropathy, in the setting of HCV syndrome (see Fig. 1). HCV antigens are responsible for both T-lymphocyte and B-lymphocyte activation with production of different autoantibodies and cryoprecipitable and noncryoprecipitable immune complexes, potentially involved in the pathogenesis of HCV-related nephropathy. Moreover, the HCV infection of B-lymphocytes is responsible for lymphoproliferative manifestations, including frank B-cell NHL. HCV-related nephropathy is the result of glomerular deposition of immune complexes, anti-HCV IgG, and/or antiendothelial antibodies and complement responsible for the inflammatory process. On the other hand, HCV may directly contribute to tissue damage by infecting the endothelium, tubular epithelial cells, and infiltrating leukocytes. Ab, antibodies; APC, antigen-presenting cells; cryo, cryoprecipitable; cryog, cryoglobulinemia; HCC, hepatocellular carcinoma; HLA, human leukocyte antigen; IC, immune complexes; inv, involvement; LDL, low-density lipoprotein; NHL, non-Hodgkin lymphoma; PCT, porphyria cutanea tarda; RF, rheumatoid factor; s, syndrome.

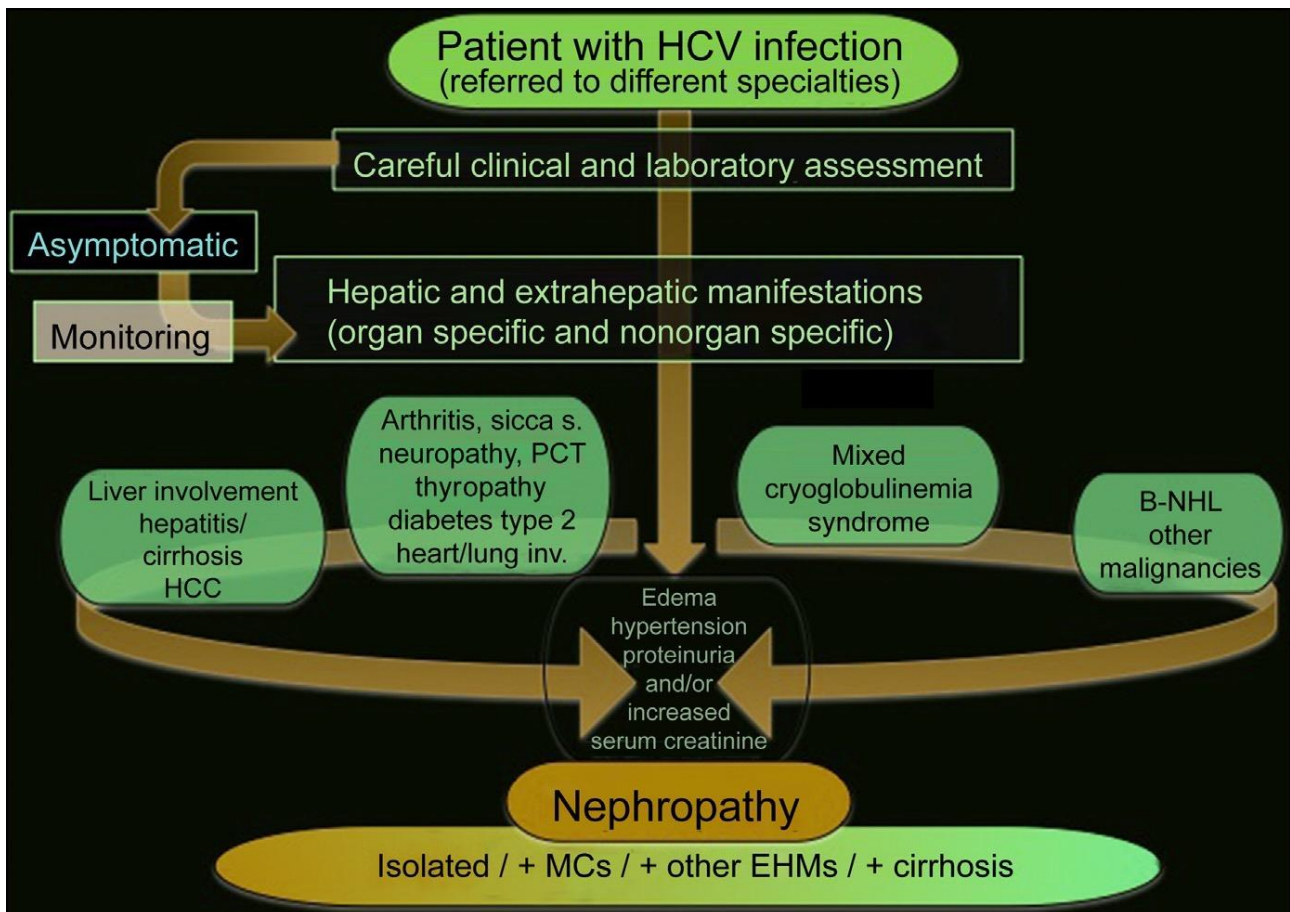


Fig. 3. HCV-related nephropathy: clinical assessment and diagnosis. Patients with HCV infection should be systematically investigated with regards to both hepatic and extrahepatic autoimmune/lymphoproliferative and neoplastic disorders, regardless of the specialty of the referral centers. In addition, asymptomatic HCV-infected subjects should be monitored to detect possible hepatic and HCV-EHMs early, including urinalysis and sediment evaluation. Nephropathy may be easily suspected in the presence of urinary abnormalities, edema, hypertension, proteinuria and/or increased serum creatinine, ultrasound kidney evaluation, and if opportune renal needle-biopsy. Clinically, renal manifestations, mainly the MPGN, can be observed as isolated manifestation or more frequently in association with MCS or other HCV-EHMs; alternatively, it may complicate severe hepatic (decompensated cirrhosis), metabolic (diabetes), and/or cardiopulmonary manifestations. inv, involvement; HCC, hepatocellular carcinoma; MCs, mixed cryoglobulinemia syndrome; NHL, non-Hodgkin lymphoma; PCT, porphyria cutanea tarda; s, syndrome.

Table 1
Histopathological features of hepatitis C virus–related renal involvement

Renal Disease Pattern	Histologic Features	Frequency
Diffuse or focal MPGN	Mesangial cells proliferation plus deposits of immune complexes, including HCV particles, complement fragments, immunoglobulins with/without cryoprecipitation capability; frequently, double contour appearance of the capillary wall	Typically found
Mesangial proliferative GN	Diffuse mild mesangial matrix expansion and mesangial cells proliferation	Occasionally found
Tubulointerstitial nephritis ^a	Interstitial fibrosis and infiltrating leukocytes, usually focal, with negative immunofluorescence	Rare
Membranous GN	Subepithelial deposits of immune complexes and C3	Rare
IgA nephropathy	Mesangial IgA deposits	Rare
Thrombotic microangiopathy ^b	Arterioles showed intimal thickening, swollen endothelium, narrowed glomerular capillary lumen, and thrombi that may extend into afferent arterioles	Rare
Focal segmental glomerulosclerosis	Sclerosed glomeruli and tubular atrophy, negative immunofluorescence, deletion of podocytes of epithelial cells (electronic microscopy)	Anecdotal
Immunotactoid glomerulopathy fibrillary GN	Extracellular deposits of microfibrils within the mesangium and glomerular capillary walls; Ig (mainly IgG4) and C3 immunofluorescence	Anecdotal

Abbreviation: GN, glomerulonephritis.

^a Interstitial fibrosis and infiltrating leukocytes are associated with greater than 60% MPGN, whereas an isolated interstitial nephritis is rare.

^b Endoluminal thrombi are frequently associated with other pathologic patterns (>50% of MPGN); besides, a peculiar form in the context of a hemolytic uremic syndrome was rarely described in renal transplanted patients.