

## Research Article

# Tirbanibulin 1% Ointment Effectiveness for Actinic Keratosis Treatment Evaluated by Dynamic Optical Coherence Tomography

C. Cantisani <sup>1</sup>, N. Musolff,<sup>1</sup> G. Azzella,<sup>1</sup> L. Gargano,<sup>1</sup> A. Di Guardo,<sup>1</sup> C. Longo,<sup>2,3</sup> S. Guida,<sup>4</sup> G. Rossi,<sup>1</sup> E. Rovaldi,<sup>1</sup> F. Rega,<sup>1</sup> G. Cocci Grifoni,<sup>1</sup> N. Kiss,<sup>5</sup> L. Ambrosio,<sup>1</sup> and G. Pellacani<sup>1</sup>

<sup>1</sup>UOC of Dermatology, Policlinico Umberto I Hospital, Sapienza Medical School of Rome, Rome, Italy

<sup>2</sup>Skin Cancer Center, Azienda Unità Sanitaria Locale, IRCSS, Reggio Emilia, Italy

<sup>3</sup>Department of Dermatology, University of Modena and Reggio Emilia, Modena, Italy

<sup>4</sup>Dermatology, Vita-Salute San Raffaele University, Via Olgettina No. 60, Milano 20132, Italy

<sup>5</sup>Department of Dermatology, Venereology and Dermatocology, Semmelweis University, Budapest, Hungary

Correspondence should be addressed to C. Cantisani; [carmen.cantisani@uniroma1.it](mailto:carmen.cantisani@uniroma1.it)

Received 8 October 2023; Revised 25 March 2024; Accepted 28 March 2024; Published 15 April 2024

Academic Editor: Althea East-Innis

Copyright © 2024 C. Cantisani et al. This is an open access article distributed under the Creative Commons Attribution License, which permits unrestricted use, distribution, and reproduction in any medium, provided the original work is properly cited.

**Background.** Actinic keratosis (AK) is a common premalignant skin condition. Its diagnosis is based on a clinical and sometimes dermoscopic examination, but, in some situations, a skin biopsy may be necessary. Dynamic optical coherence tomography (D-OCT) can often bypass this need, by noninvasive evaluation of skin morphology. Early and effective treatment of AKs is important to prevent the progression to invasive squamous cell carcinoma (iSCC). Tirbanibulin 1% ointment, a new topical field therapy for AKs, has recently been introduced. **Objectives.** The aim of this study was to evaluate the efficacy and safety of tirbanibulin 1% ointment for the field treatment of nonhyperkeratotic, nonhypertrophic AKs (Olsen grade 1) on the face and/or scalp in adults, using D-OCT technology. **Methods.** Patients, presenting multiple, mild to moderate AKs on the face and scalp, in treatment with tirbanibulin 1% ointment for five consecutive days of an area measuring 25 cm<sup>2</sup>, were evaluated with videodermoscopy (V-track Vidix 4.0) and D-OCT (VivoSight Dx, Michelson Diagnostics Ltd., Kent, England, United Kingdom), as normal clinical practice. The lesions were staged according to the Olsen classification, excluding the most aggressive lesions. **Results.** We retrospectively evaluated 50 patients (27 males and 23 females, mean age 76 ± 7.9 years). At 57 days posttreatment, the complete clearance rate was 68% ( $n = 34$ ) and partial clearance rate was 76% ( $n = 38$ ). D-OCT showed markedly improved morphology, including a better recognizable dermal-epidermal junction (DEJ), associated with reduced inflammation. The most common adverse events reported were erythema and scaling, which were mostly mild and self-limiting. **Conclusions.** This study demonstrated that tirbanibulin may be considered an effective and well-tolerated treatment option for nonhyperkeratotic, nonhypertrophic AKs. It showed a favorable safety profile, with mostly mild adverse events. D-OCT can be considered a useful tool for personalizing AK treatment and monitoring.

## 1. Introduction

Actinic keratosis (AK) is a worldwide problem with continuously increasing incidence. It is a common intra-epidermal neoplasm found in chronically sun-damaged skin, characterized by variable abnormal keratinocyte proliferation and differentiation [1, 2]. Any subset of patients can develop AKs over a lifetime. They are more frequent in fair-skinned individuals, especially who have been chronically sun-exposed or had several sunburns [1].

Imunocompromised patients also have an increased risk of developing AKs. UV radiation is the primary cause of DNA damage in keratinocytes [1, 3]; the pathogenesis involves DNA damage to keratinocytes, leading to mutations that can result in the formation of AK lesions. The diagnosis is typically based on their clinical and dermoscopic appearance, although a skin biopsy may, sometimes, be necessary to confirm the diagnosis. Recently, additional diagnostic methods have been developed. Between them, dynamic optical coherence tomography (D-OCT) is a developing

noninvasive technology that utilizes low-power infrared laser light to provide high-resolution, enface, and cross-sectional in-vivo images of the skin. It offers higher power penetration (approximately 2 mm) compared to reflectance confocal microscopy, allowing the better characterization of papular lesions [4]. OCT is valuable in characterizing changes that may not be clinically visible, and it can be used in diagnosing difficult lesions, thereby reducing the number of unnecessary biopsies or facilitating treatment monitoring [5]. Treatment options for AK include a range of interventions: lesion-directed treatment and cancerization field treatment [6]. In summary, cryotherapy is used for single and hypertrophic lesions, conventional or daylight photodynamic therapy, imiquimod and 5-fluorouracil, or different combination of them [7], for multiple non-hypertrophic AKs, while surgical excision is typically reserved for more severe cases [8, 9]. In 2020, tirbanibulin 1% ointment was approved by the US Food and Drug Administration (FDA) for the treatment of AKs, while, in 2021, arrived in the Italian market. As a small molecule inhibitor of tubulin, it disrupts the microtubule network in keratinocytes. It is applied, directly to the affected skin area, once daily for 5 consecutive days, offering a convenient treatment option for AKs, showing promising results in clinical trials [10]. We evaluated its efficacy using dynamic optical coherence tomography (D-OCT).

## 2. Materials and Methods

Patients affected by 2 to 8 clinically visible, non-hypertrophic, and nonhyperkeratotic actinic keratosis lesions on the face or scalp, within a contiguous area measuring 25 cm<sup>2</sup> and treated with 1% tirbanibulin ointment, once daily for five consecutive days, have been evaluated, excluding most severe cases. They were chosen from the pool of patients presenting to the noninvasive diagnostic imaging and nonsurgery treatment for non-melanoma skin cancer (NMSC) outpatient clinic (Policlinico Umberto I Hospital of Rome, Italy). As normal clinical practice, and in accordance with previous trials, all patients underwent macroscopic evaluation, videodermoscopy (V-Track and VIDIX 4.0, Medici Medical Srl, Italy), and D-OCT (Michelson diagnostics, UK) before treatment (T0), between days 6 to 8 (T1) and at day 57 (T2). Safety and adverse outcomes were assessed at the same intervals. D-OCT was routinely used to acquire scans of AKs in every patient. A trained dermatologist, respectively, analyzed the scans for morphology of the skin, epidermal thickness, level of vertical (enface) and longitudinal vascularity, and appearance of the stratum corneum and dermo-epithelial junction (DEJ). VivoTools software (V1.1, Michelson Diagnostics, UK) was used to calculate vascular density and diameter, active plexus depth, and epidermal thickness for each lesion and scan. Vascular measurements were performed at 0.3 mm to give a good estimation of dermal vascularization. The primary efficacy outcome was the percentage of patients with complete clearance of all lesions, within the application area, at day 57. Complete clearance is defined as the clinical disappearance of the

entire lesion (100% reduction in lesion diameter). The secondary efficacy outcome was the percentage of patients with partial clearance at 57 days, defined as a reduction of at least 75% in the diameter of lesions. Safety assessments up to day 57 included the recording of Local Skin Reaction scores (LSR 0–4), the evaluation of the presence of pigmentation or scarring in the application area, and adverse events. The LSRs consist of 6 variables: erythema, flaking/scaling, crusts, swelling, vesicles/pustulation, and erosions/ulceration. Each variable was graded according to a 4-point scale (with scores of 0 [absent], 1 [mild], 2 [moderate], and 3 [severe]). A composite score was then calculated as the sum of the scores for all six signs (range 0 to 18, with higher scores indicating more severe reactions) at each visit.

## 3. Results

A total of 50 patients, consisting of 27 males and 23 females (mean age of 76 ± 7.9 years [range: 60–88 years]), treated with tirbanibulin 1% ointment, were retrospectively evaluated. The majority of patients had a Fitzpatrick skin type of II or III ( $n = 45$ , 90%). The treatment area was located on the face for 29 patients (58%) and on the scalp for 21 patients (42%) (Table 1). The evaluation of the dermoscopic images identified a red pseudo-network and background erythema. On D-OCT, AK lesions appeared as well-defined, round, or oval-shaped areas with a slightly raised or thickened surface corresponding to minimal hyperkeratosis and crusting. The dermo-epithelial junction (DEJ) could not be clearly demarcated and was fuzzy when compared to adjacent healthy skin. VivoTools analysis was not able to detect epidermis in 94% ( $n = 47$ ) of patients but showed increased vascularity when compared to adjacent healthy skin (vascular density at 0.3 mm 109 vs 87,  $p = 0.032$ ). Between days 6–8, patients were reevaluated, but estimation of the overall clearance rates was impossible due to the ongoing inflammatory process, as evidenced by the presence of erythema, crusting, and swelling. Upon D-OCT, inflammation was prevalent and seen as vesicles, and hyperreflective and hyporefective areas, presumably granulation and edema, respectively. Vascularity as calculated by VivoTools software showed an increase in vessel diameter, vascular density, and plexus depth ( $p = 0.021$ , 0.04, 0.023). At 57 days posttreatment, the complete clearance rate was 68% ( $n = 34$ ) and partial clearance was 76% ( $n = 38$ ). D-OCT showed markedly improved morphology, a clear dermo-epidermal junction (DEJ), and a reduction in inflammation (Figures 1 and 2). On enface mode, the untreated lesions exhibited irregular vessel shapes, that ranged from mesh to branching, with a high level of tortuosity, spiraling, and engorgement throughout (Figure 3). On day 57, most lesions that appeared fully healed (complete clearance) on the surface also displayed blood vessel patterns similar to those in normal, healthy skin, while lesions that showed no visible signs of improvement likewise exhibited no microscopic changes in their vascular structures (Figure 4). However, the vascular patterns did not always correspond to results on dermoscopy. After 57 days of treatment, 22 patients still had marked irregular morphology on enface D-OCT. These

TABLE 1: LSR score results before treatment, at days 6–8, at 1 month, and at day 57 (0 = none and 3 = severe).

LSR	Day 6–8	1 month	Day 57
<b>Erythema</b>			
0	0	34 (68%)	0
1	27 (54%)	9 (18%)	0
2	13 (26%)	7 (14%)	0
3	10 (20%)	0	0
<b>Swelling</b>			
0	13 (26%)	46 (92%)	0
1	26 (52%)	4 (8%)	0
2	11 (22%)	0	0
3	0	0	0
<b>Scales</b>			
0	29 (58%)	41 (82%)	0
1	12 (24%)	9 (18%)	0
2	9 (18%)	0	0
3	0	0	0
<b>Vesicles</b>			
0	13 (26%)	49 (98%)	0
1	32 (64%)	1 (2%)	0
2	5 (10%)	0	0
3	0	0	0
<b>Erosions/ulcerations</b>			
0	21 (42%)	48 (86%)	0
1	18 (36%)	2 (4%)	0
2	11 (22%)	0	0
3	0	0	0
<b>Crusts</b>			
0	19 (38%)	40 (80%)	0
1	20 (40%)	5 (10%)	0
2	5 (10%)	5 (10%)	0
3	6	0	0
LSR composite score (mean)*	5.82	1.08	0

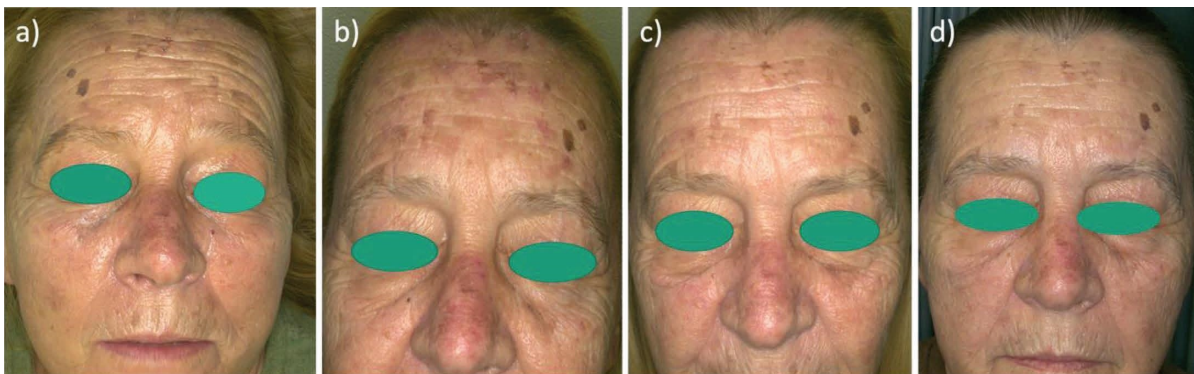
\* $p < 0.001$ .

FIGURE 1: Clinical evaluation. (a) Pretreatment. (b) Day 6. (c) Day 30. (d) Day 57.

included the 12 individuals with little to no clinical response but also 10 that reached at least partial, if not complete, clearance. VivoTools analysis was able to detect epidermis in 84% of patients ( $n = 42$ ). Vessel diameter and density decreased compared to T0, while plexus depth increased further ( $p = 0.01, 0.033, 0.04$ ) (Figure 5). Safety and adverse effects were assessed at 6–8 days, at 30 days, and at 57 days, utilizing the LSR score (Table 1). No serious adverse events were reported.

#### 4. Discussion

Given the high prevalence of AKs in the aging population, it is not surprising that managing AKs and field cancerization (FC) comes with significant economic and social costs. According to recent literature, lesions do not always follow the classic Rowert-Huber histologic classification before acquiring the ability to invade the dermis. In fact, invasion can occur directly from atypical clones at the basal layer,

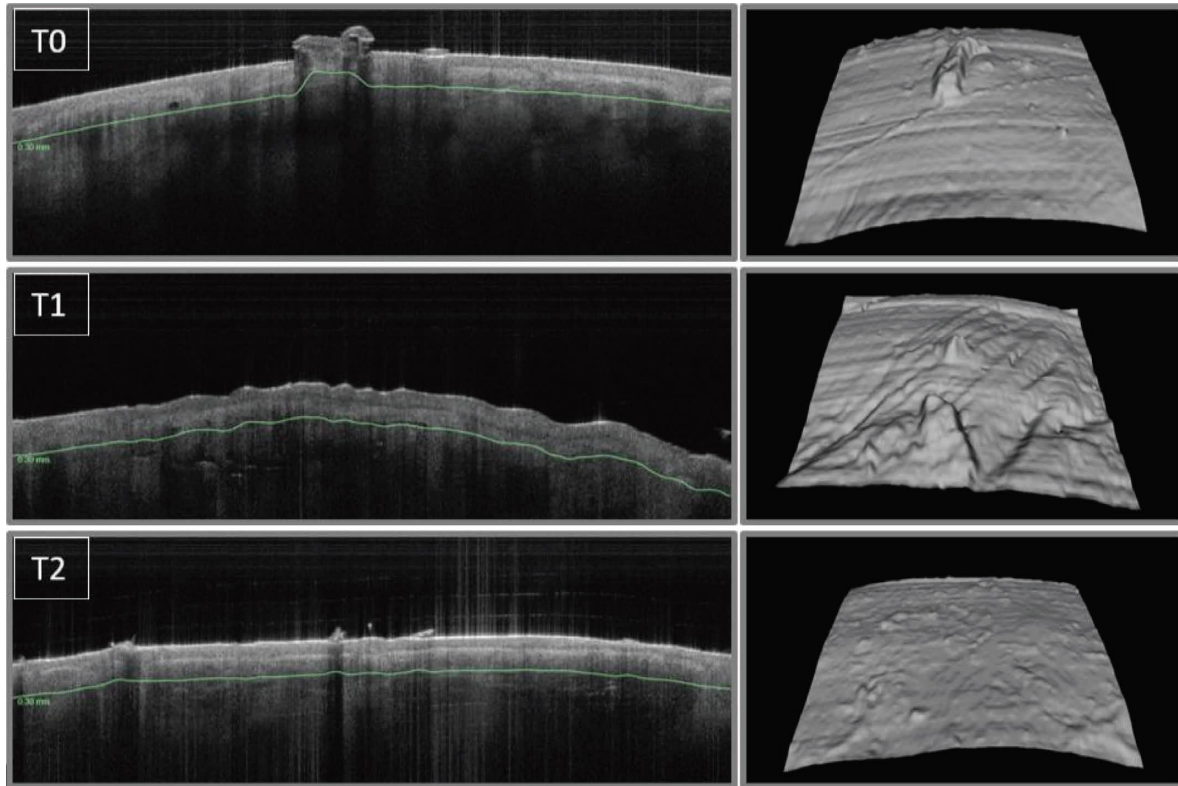


FIGURE 2: D-OCT scans at T0, T1 (days 6–8), and T2 (day 57). D-OCT showed markedly improved morphology, a clear DEJ, and a flattening of the skin surface in the 3D reconstruction.

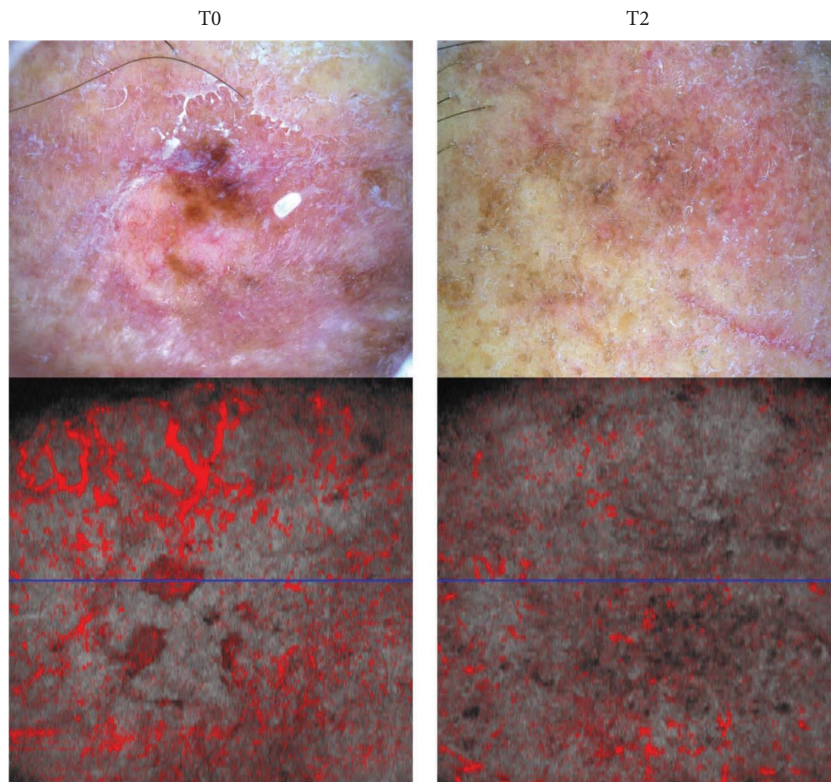


FIGURE 3: Clinic and corresponding D-OCT evaluation at T0 and T2 (day 57). D-OCT showed complete clearance. D-OCT enface scan showed normalization of vascularity.

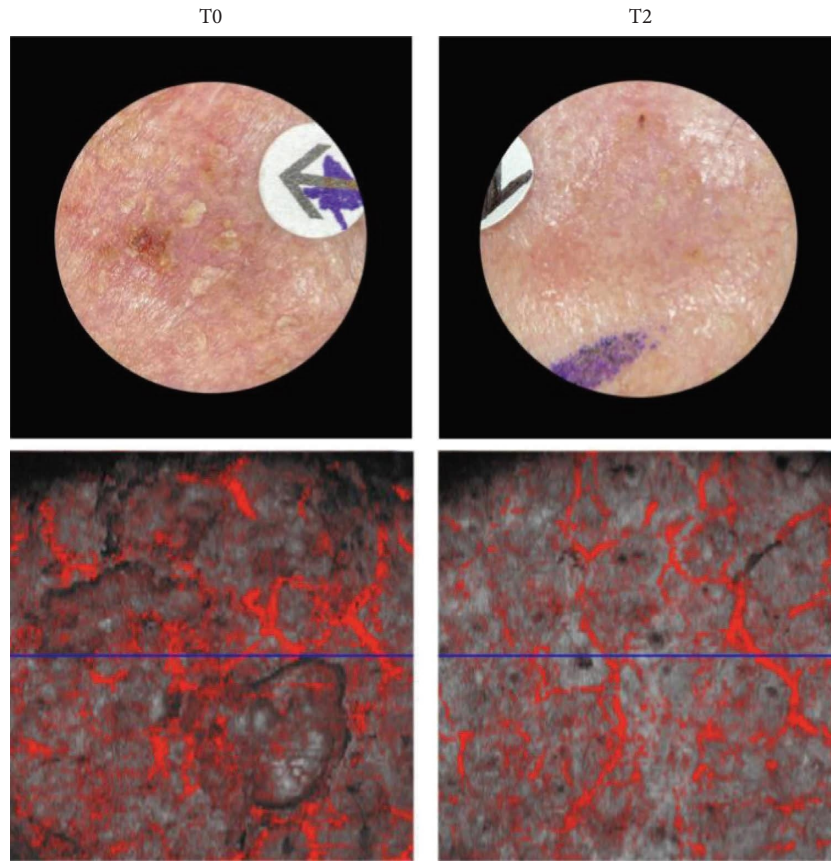


FIGURE 4: Clinical clearance was observed alongside corresponding D-OCT enface scans at T0 and T2 (day 57). D-OCT reveals persistent vascular irregularities.

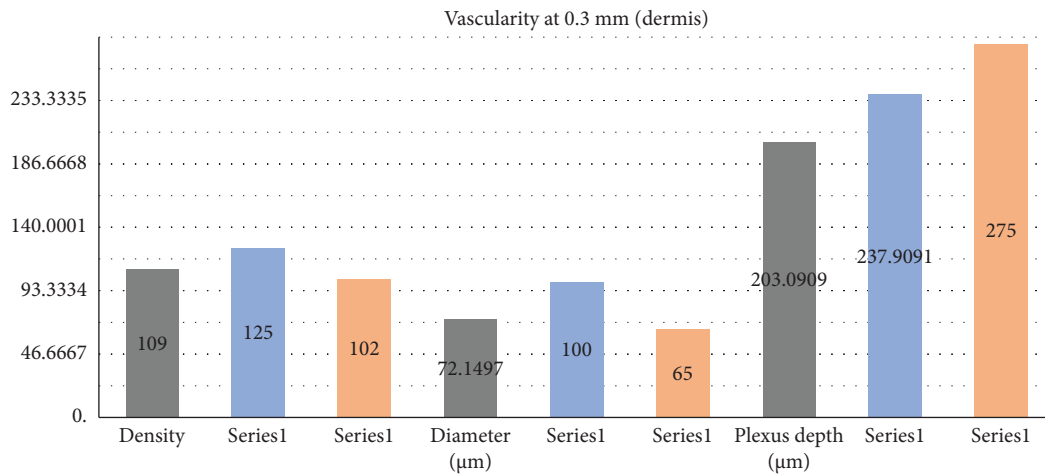


FIGURE 5: Average vascular parameters on VivoTools analysis. T1 = days 6–8 and T2 = day 57.

becoming locally invasive SCC (iSCC) with the potential to cause systemic metastases [11–13]. AK is a chronic relapsing disease; therefore, the goal is not to cure it but to control it. By treating all lesions, we do not have a direct benefit, consisting of avoiding the evolution to more aggressive lesions, but there is an indirect benefit stemming from the selection of nonresponsive or more aggressive lesions [14]. The ideal treatment, unfortunately, does not exist yet; therefore, there are still unmet needs. The goal is to find

a short-duration treatment, with long-lasting results, and less LRS which will increase compliance. In this view, in recent years, tirbanibulin was approved for the treatment of AKs and received a strong recommendation for its use in field therapy limited to 25 cm<sup>2</sup> [15]. Tirbanibulin is a synthetic, first-in-class Src kinase signaling and tubulin polymerization inhibitor, which has antiproliferative and antitumoral effects by inducing cell cycle arrest and apoptotic cell death, reducing metastasis with a low rate of

severe local skin reactions (LSRs). Our study demonstrates the clear benefits of tirbanibulin used in patients with mild to moderate AKs [10]. More aggressive AKs, identified with D-OCT, were excluded from this evaluation, according to the therapeutic indications of tirbanibulin 1% ointment. Considering its short application period, tirbanibulin demonstrated significant complete and partial clearance rates, supporting its recommendation as a viable treatment option. Furthermore, LSRs were mild to moderate, but always easily managed, especially evident at day five, but cleared up without treatment within 20 days posttreatment. The mild nature of the side effects, along with the short duration of therapy, boosted patient compliance, one of the greatest challenges in chronic relapsing diseases. Clinical observation in dermatology is crucial for diagnosis and monitoring conditions, but its use alone, partly due to interindividual variability, does not suffice in all cases. D-OCT offers noninvasive detailed assessment of skin lesions in real time. Scans visualize the morphology of the epidermis, DEJ, dermis, blood vessels, and 3D surface structure. In Olsen grade I lesions, which are more easily felt than seen, D-OCT technology makes their extent visible, enabling the evaluation of more aggressive lesions [4, 5, 16]. Of particular interest was the analysis of the vascular morphology as seen in enface mode [17]. As expected, the vascular patterns underwent significant changes over the treatment period, but they did not always correspond to results on dermoscopy. We suggest that the use of D-OCT can provide crucial additional information for treatment decisions. Lesions, that show normalization of both vascularity and clinical appearance after 57 days, can be considered as better responding to treatment. When lesions appear to regress clinically, but still exhibit ongoing pathological vascular patterns beneath the surface, there might be a risk of quick relapse, indicating the potential necessity for an alternative treatment strategy, and sometimes, even for different lesions in the same patient. Finally, VivoTools algorithms produced valuable information regarding AK's vascularity. 57 days after treatment, vascular density and mean vessel diameter decreased, while they increased at 5 days, hinting at the inflammation process. Active plexus depth gradually increased from T0 to T2, reaching normal depths found in healthy skin. However, the main limitation is that D-OCT is an expensive tool, available only in a few academic hospitals or research centers. Ultimately, we can suggest tirbanibulin as a first-line treatment in patients with AK, of the face and scalp that have not been previously treated. Further studies are needed, focusing on early identification of the field of cancerization, risk factors, and prediction of progression. Combining noninvasive tools such as D-OCT, with greater knowledge of genetic markers, especially those of aggressive forms, could allow us in the future to completely change the therapeutic armamentarium towards a more individualized form of medicine [4].

### Data Availability

The data used to support the findings of this study are included within the article.

### Ethical Approval

The study was a retrospective evaluation conducted in accordance with the principles of the Declaration of Helsinki and the International Council for Harmonization and Good Clinical Practice guidelines.

### Consent

Written informed consent has been obtained from the patients to publish this paper.

### Conflicts of Interest

The authors declare that they have no conflicts of interest.

### Authors' Contributions

Carmen Cantisani conceptualized and validated the study; Carmen Cantisani, Noah Musolff, and Antonio di Guardo wrote the original draft of the study; Rovaldi Emanuele, Luca Gargano, Guida S., Federica Rega, Luca Ambrosio, Giovanni Rossi, Coci Grifoni Giulia, Giulia Azzella, and Norbert Kiss wrote the review and edited the manuscript; Giovanni Pellacani and Longo Caterina supervised the study.

### Acknowledgments

The authors would like to thank Jon Holmes CEO of Michelson Diagnostics Ltd and our nurse Mrs Sonia Tofani for their precious help.

### References

- [1] C. Cantisani, G. Paolino, M. Melis et al., "Actinic keratosis pathogenesis update and new patents," *Recent Patents on Inflammation and Allergy Drug Discovery*, vol. 10, no. 1, pp. 40–48, 2016.
- [2] D. Didona, G. Paolino, U. Bottoni, and C. Cantisani, "Non melanoma skin cancer pathogenesis overview," *Biomedicine*, vol. 6, no. 1, p. 6, 2018.
- [3] T. Dirschka, G. Gupta, G. Micali et al., "Real-world approach to actinic keratosis management: practical treatment algorithm for office-based dermatology," *Journal of Dermatological Treatment*, vol. 28, no. 5, pp. 431–442, 2017.
- [4] C. Lenoir, E. Cinotti, L. Tognetti et al., "Line-field confocal optical coherence tomography of actinic keratosis: a case series," *Journal of the European Academy of Dermatology and Venereology: JEADV*, vol. 35, no. 12, pp. e900–e902, 2021.
- [5] K. B. E. Friis, L. Themstrup, and G. B. E. Jemec, "Optical coherence tomography in the diagnosis of actinic keratosis-A systematic review," *Photodiagnosis and Photodynamic Therapy*, vol. 18, pp. 98–104, 2017.
- [6] N. Lampley, R. Rigo, T. Schlesinger, and A. M. Rossi, "Field therapy for actinic keratosis: a structured review of the literature on efficacy, cost, and adherence," *Dermatologic Surgery*, vol. 49, no. 2, pp. 124–129, 2023.
- [7] C. Cantisani, G. Paolino, M. Scarnò et al., "Sequential methylaminolevulinate daylight photodynamic therapy and diclofenac plus hyaluronic acid gel treatment for multiple actinic keratosis evaluation," *Dermatologic Therapy*, vol. 31, no. 6, Article ID e12710, 2018.

- [8] C. M. Cornejo, A. Jambusaria-Pahlajani, T. J. Willenbrink, C. D. Schmults, S. T. Arron, and E. S. Ruiz, "Field cancerization: treatment," *Journal of the American Academy of Dermatology*, vol. 83, no. 3, pp. 719–730, 2020.
- [9] T. Steeb, A. Wessely, U. Leiter, L. E. French, C. Berking, and M. V. Heppt, "The more the better? An appraisal of combination therapies for actinic keratosis," *Journal of the European Academy of Dermatology and Venereology*, vol. 34, no. 4, pp. 727–732, 2020.
- [10] A. C. Miller, S. Adjei, L. A. Temiz, and S. K. Tyring, "Tirbanibulin for the treatment of actinic keratosis: a review," *Skin therapy letter*, vol. 27, no. 4, pp. 4–7, 2022.
- [11] R. Marks, G. Rennie, and T. S. Selwood, "Malignant transformation of solar keratoses to squamous cell carcinoma," *The Lancet*, vol. 331, no. 8589, pp. 795–797, 1988.
- [12] V. D. Criscione, M. A. Weinstock, M. F. Naylor, C. Luque, M. J. Eide, S. F. Bingham et al., "Actinic keratoses: natural history and risk of malignant transformation in the veterans affairs topical tretinoin chemoprevention trial," *Cancer*, vol. 115, no. 11, pp. 2523–2530, 2009.
- [13] M. Fernandez Figueras, "From actinic keratosis to squamous cell carcinoma: pathophysiology revisited," *Journal of the European Academy of Dermatology and Venereology*, vol. 31, no. S2, pp. 5–7, 2017.
- [14] D. Berker, J. M. McGregor, M. F. Mohd Mustapa et al., "British Association of Dermatologists' guidelines for the care of patients with actinic keratosis 2017," *British Journal of Dermatology*, vol. 176, no. 1, pp. 20–43, 2017.
- [15] A. Blauvelt, S. Kempers, E. Lain et al., "Phase 3 trials of tirbanibulin ointment for actinic keratosis," *New England Journal of Medicine*, vol. 384, no. 6, pp. 512–520, 2021.
- [16] M. A. Boone, S. Norrenberg, G. B. Jemec, and V. Del Marmol, "Imaging actinic keratosis by high-definition optical coherence tomography. Histomorphologic correlation: a pilot study," *Experimental Dermatology*, vol. 22, no. 2, pp. 93–97, 2013.
- [17] M. Ulrich, L. Themstrup, N. de Carvalho et al., "Dynamic optical coherence tomography of skin blood vessels- proposed terminology and practical guidelines," *Journal of the European Academy of Dermatology and Venereology*, vol. 32, no. 1, pp. 152–155, 2018.