

This is the peer reviewed version of the following article:

Classification of EEG abnormalities in partial epilepsy with simultaneous EEG-fMRI recordings / Pedreira, C.; Vaudano, Anna Elisabetta; Thornton, R. C.; Chaudhary, U. J.; Vulliemoz, S.; Laufs, H.; Rodionov, R.; Carmichael, D. W.; Lhatoo, S. D.; Guye, M.; Quiñero, R.; Lemieux, L. - In: NEUROIMAGE. - ISSN 1053-8119. - 99:(2014), pp. 461-476. [10.1016/j.neuroimage.2014.05.009]

Terms of use:

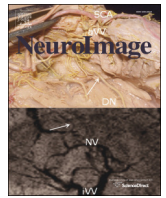
The terms and conditions for the reuse of this version of the manuscript are specified in the publishing policy. For all terms of use and more information see the publisher's website.

08/05/2026 19:48



Contents lists available at ScienceDirect

NeuroImage

journal homepage: www.elsevier.com/locate/ynimg

Classification of EEG abnormalities in partial epilepsy with simultaneous EEG–fMRI recordings

Q1 C. Pedreira^{a,1}, A.E. Vaudano^{b,c,1}, R.C. Thornton^c, U.J. Chaudhary^c, S. Vulliemoz^d, H. Laufs^e, R. Rodionov^c,
 4 D.W. Carmichael^{c,f}, S.D. Lhatoo^g, M. Guye^{h,i}, R. Quian Quiroga^{a,j}, L. Lemieux^{c,*}

^a Centre for Systems Neuroscience, The University of Leicester, UK

^b Department of Neuroscience, NOCSAE Hospital, University of Modena e Reggio Emilia, Modena, Italy

^c Department of Clinical and Experimental Epilepsy, UCL Institute of Neurology, London, UK

^d Department of Neurology, University Hospital of Geneva, CH-1211 Genève 14, Switzerland

^e Department of Neurology, Schleswig Holstein University Hospital, Kiel, Germany

^f Imaging and Biophysics Unit, UCL Institute of Child Health, London, UK

^g Division of Medical Informatics, Case Western Reserve University, Cleveland, OH, USA

^h Aix-Marseille Université, CNRS, CRMBM UMR 7339, Marseille, France

ⁱ APHM, Hôpitaux de la Timone, Service de Neurophysiologie Clinique & CEMEREM, Marseille, France

^j Leibniz Institute for Neurobiology, Magdeburg, Germany

ARTICLE INFO

Article history:
 Accepted 2 May 2014
 Available online xxxx

Keywords:
 IED
 EEG–fMRI
 Automatic classification
 Focal epilepsy
 icEEG

ABSTRACT

Scalp EEG recordings and the classification of interictal epileptiform discharges (IED) in patients with epilepsy provide valuable information about the epileptogenic network, particularly by defining the boundaries of the “irritative zone” (IZ), and hence are helpful during pre-surgical evaluation of patients with severe refractory epilepsies. The current detection and classification of epileptiform signals essentially rely on expert observers. This is a very time-consuming procedure, which also leads to inter-observer variability. Here, we propose a novel approach to automatically classify epileptic activity and show how this method provides critical and reliable information related to the IZ localization beyond the one provided by previous approaches. We applied *Wave_clus*, an automatic spike sorting algorithm, for the classification of IED visually identified from pre-surgical simultaneous Electroencephalogram–functional Magnetic Resonance Imaging (EEG–fMRI) recordings in patients affected by refractory partial epilepsy candidate for surgery. For each patient, two fMRI analyses were performed: one based on the visual classification and one based on the algorithmic sorting. This novel approach successfully identified a total of 29 IED classes (compared to 26 for visual identification). The general concordance between methods was good, providing a full match of EEG patterns in 2 cases, additional EEG information in 2 other cases and, in general, covering EEG patterns of the same areas as expert classification in 7 of the 8 cases. Most notably, evaluation of the method with EEG–fMRI data analysis showed hemodynamic maps related to the majority of IED classes representing improved performance than the visual IED classification-based analysis (72% versus 50%). Furthermore, the IED-related BOLD changes revealed by using the algorithm were localized within the presumed IZ for a larger number of IED classes (9) in a greater number of patients than the expert classification (7 and 5, respectively). In contrast, in only one case presented the new algorithm resulted in fewer classes and activation areas. We propose that the use of automated spike sorting algorithms to classify IED provides an efficient tool for mapping IED-related fMRI changes and increases the EEG–fMRI clinical value for the pre-surgical assessment of patients with severe epilepsy.

© 2014 Published by Elsevier Inc.

Introduction

Non-invasive techniques for recording brain activity are widely used to assess neurological conditions and improve the understanding of

healthy brain function (Emerson and Pedley, 2000). In patients affected by epilepsy, scalp Electroencephalography (EEG) recordings represent a fundamental tool for identifying pathological brain activity and hence support epileptic syndrome diagnosis (Hogan, 2011). Interictal epileptiform discharges (IED; commonly referred to as ‘epileptic spikes’) are seen in recordings from patients with focal and generalised epilepsies and their recognition and classification provide information about the mechanisms of ictogenesis (Ebersole, 1997). Furthermore, experimental studies have suggested that interictal spikes might precede the

* Corresponding author at: MRI Unit, National Society for Epilepsy, Chesham, Lane, Chalfont St Peter, Buckinghamshire SL9 0RJ, UK. Fax: +44 1494 875 666.

E-mail address: louis.lemieux@ucl.ac.uk (L. Lemieux).

¹ Equal contribution.

64 occurrence of spontaneous seizures and might contribute to the devel-
65 opment and maintenance of the epileptic state (Staley et al., 2011;
66 White et al., 2010). Finally, IED and their topographic distributions
67 define the boundaries of the “irritative zone” (IZ; area from which IED
68 arise) and hence can be used during the pre-surgical evaluation of
69 patients with severe drug-resistant epilepsy (Luders, 1993).

70 Simultaneous recording of EEG and functional MRI (EEG–fMRI) is a
71 technique capable of revealing the brain regions hemodynamically
72 involved by the epileptic discharge based on local blood oxygenation
73 level dependent (BOLD) signal variations. In patients with refractory
74 focal epilepsy the significant clinical question is how the EEG–fMRI
75 results can contribute to localize the seizure onset zone (SOZ), the
76 brain region that is thought to be responsible for generating seizures.
77 To date, the intracranial EEG recordings (icEEG) are considered the
78 gold standard for identifying the SOZ (Rosenow and Luders, 2001),
79 although it is expensive and has associated morbidity (Hamer et al.,
80 2002). There has been great effort in the study of IED, which are gener-
81 ally much more abundant than ictal events, as marker of the SOZ by
82 non-invasive means; in particular there have been attempts to identify
83 whether a specific type of IED is a specific marker of the SOZ (or epilep-
84 togenic zone). This is one of the motivations for performing EEG–fMRI of
85 IED by the study of the associated BOLD patterns (Pittau et al., 2012;
86 Thornton et al., 2010, 2011). More importantly, it has been demonstrat-
87 ed that when the surgical resection completely removed the region in
88 which IED correlated BOLD signal change, it is associated with a better
89 outcome and seizure freedom (Thornton et al., 2010). Similar conclu-
90 sions have been reached by using the Electrical Source Imaging (ESI)
91 approach on high-density scalp EEG during the pre-surgical evaluation
92 protocol (Mégevand et al., 2013). This evidence further supports the im-
93 portance of a correct definition of IED generators in order to improve
94 surgery outcome. However, caution must be required in extrapolating
95 the results of any interictal investigation to make inferences about the
96 epileptogenic zone. The definition of the irritative zone is indeed an
97 important aspect in the evaluation of the SOZ, but not equivalent to it
98 (Dworetzky and Reinsberger, 2011).

99 In routine clinical practice, the detection and classification of IED
100 continue to be based on visual inspection by expert observers using
101 waveform morphology and field distribution. Similarly, the modelling
102 of epileptic activity-related hemodynamic changes using fMRI relies
103 mostly on visual identification, classification and marking of the epilep-
104 tic EEG patterns (Al-Asmi et al., 2003; Salek-Haddadi et al., 2006).
105 The detection and classification of IEDs can be a time-consuming procedure,
106 especially in the case of (continuous) long-term EEG monitoring
107 (Ramabhadran et al., 1999) and requires experienced reviewers for
108 visual identification and quantification of epileptic discharges (Scherg
109 et al., 2012). Additionally, the subjectivity and poor reproducibility of
110 IED detection and classification are well documented (Hostetler et al.,
111 1992; Webber et al., 1993). In the EEG–fMRI studies the presence of
112 artefacts on the EEG, caused by electromagnetic gradients and physio-
113 logical noise, may indeed alter the quality of the recordings and hence
114 influence the IED identification (Siniatchkin et al., 2007). The inaccurate
115 or inconsistent labelling of IEDs in simultaneous EEG–fMRI recordings
116 was shown to be an important source of error on the related hemody-
117 namic maps (Flanagan et al., 2009). Particularly, a linear correlation
118 between the proportions of IED included in the analysis and the per-
119 centage of voxels within the fMRI maps above a significant statistical
120 threshold has been shown (Flanagan et al., 2009). Correct IED identifica-
121 tion and classification clearly reduce the percentage of false positive and
122 false negative BOLD results improving the scientific and clinical inter-
123 pretation of the results of fMRI studies in epileptic patients, especially
124 in those cases where a correct localization of the SOZ and IZ is crucial
125 for patients' management as refractory epilepsies candidate for surgery.
126 Furthermore, quantitative approaches to EEG interpretation for the pur-
127 pose of mapping epileptic hemodynamic changes can lead to signifi-
128 cantly increased sensitivity (Grouiller et al., 2011; Liston et al., 2006;
129 Vulliemoz et al., 2011).

130 Here, we propose a pilot study presenting a novel approach to the
131 problem of IED classification for posterior analysis in scalp EEG record-
132 ings with synchronous fMRI: the use of *Waveclus* (Quian Quiroga
133 et al., 2004), a spike sorting algorithm, for the classification of the visu-
134 ally identified events. This algorithm exploits the statistical properties of
135 the IEDs (in contrast to random variance due to noise in the recorded
136 signal) to identify the intrinsic characteristic of each class. We hypothe-
137 size that this analysis can provide additional information regarding the
138 identification of IZ and the epileptic network, providing further clinical
139 insight valuable for diagnosis and hence subsequent surgical treatment
140 when indicated. We also assess the performance of the automatic IED
141 classification by estimating the level of agreement with the results of
142 expert classification, based on the fMRI data analysis findings obtained
143 for both methods.

144 Materials and methods

145 Patients

146 76 patients with refractory partial epilepsy were recruited as part
147 of an EEG–fMRI study at University College London (Thornton et al.,
148 2010). The patients were undergoing pre-surgical evaluation at three
149 centres: National Hospital for Neurology and Neurosurgery, London,
150 UK; Frenchay Hospital, North Bristol NHS Trust, UK; and Hôpital la
151 Timone, Marseille, France, to identify the SOZ and IZ, included a detailed
152 clinical history, full neurological examination, Video-EEG telemetry,
153 structural MRI scanning, neuropsychological assessment and other
154 non-invasive investigations such as PET, MEG and ictal SPECT when
155 available. The definition of the IZ is based on the Video-EEG monitoring
156 and MEG when available (Rosenow and Luders, 2001). icEEG recordings
157 were considered based on the availability of hypotheses derived from
158 spatial localization of ictal and interictal discharges recorded non-
159 invasively. In patients who underwent icEEG, this was used to define
160 the IZ and SOZ; in the other patients they were defined (qualified as
161 ‘presumed’) based on the Video-EEG monitoring and MEG when avail-
162 able (Rosenow and Luders, 2001). The EEG–fMRI recordings took
163 place at University College London. In this article we report on the 8/
164 76 patients in whom at least 200 IED were recorded during the EEG–
165 fMRI session (6 males, age range: 19–41 years, mean: 27 years).

166 All procedures were subject to local Research and development di-
167 rectorate guidelines in addition to National Research Ethics Committee
168 Approval in the UK and France.

169 EEG–fMRI acquisition

170 The patients were asked to remain still during the scanning, fitted
171 with ear-plugs, with their head immobilized using a vacuum cushion.
172 32 or 64 EEG channels were recorded at a sampling rate of 5000 Hz
173 using a commercial MR-compatible system (BrainAmp MR and Vision
174 Analyzer, Brain Products GmbH, Munich, Germany); the ECG was
175 recorded using a single lead (Allen et al., 1998; Vulliemoz et al., 2011).
176 EEG was recorded for 5–20 min with eyes closed outside the scanner
177 immediately prior to scanning. At least two 20-minute sessions of
178 resting-state EEG–fMRI were acquired separated by a short break. A
179 third 20-minute session was recorded in some patients if tolerated.
180 Each session consisted of 404 T2*-weighted single-shot gradient-echo
181 echo-planar images (EPI; TE/TR 30/3000 ms, flip angle 90: 43 2.5 mm
182 interleaved slices, FOV: 24 × 24 cm², matrix: 64 × 64) acquired contin-
183 uously on a 3 Tesla Signa Excite HDX MRI scanner (General Electric,
184 Milwaukee, WI, USA). A 5-minute finger tap task was also recorded
185 during fMRI for each case. T1-weighted MRI scans were also acquired
186 at the same time (imaging parameters: TE = 3.1 ms, TR = 8.3 ms, inver-
187 sion time = 450 ms, flip angle = 20°, slices = 170, slice thickness =
188 1.1 mm, filed of view = 24 × 18 and matrix = 256 × 256 cm²) to
189 allow accurate anatomical localization of BOLD signal changes.

190 EEG pre-processing and analysis

191 EEG artefacts induced by the MR scanning gradients and heartbeats
 192 were corrected (Allen et al., 1998, 2000) using a commercial EEG
 193 processing package (Brain Analyzer; Brain Products). For each EEG re-
 194 cording, IED were identified, marked and labelled by an expert (AEV,
 195 SV, UC or RT) to reflect distinct generators based on IED morphology
 196 and field distribution.

197 IED sorting and classification

198 Spike sorting algorithms are typically used for the analyses of extra-
 199 cellular recordings (Quian Quiroga, 2007). Advances in electrode designs
 200 have proven that these algorithms are especially effective for extracting
 201 information from multiple site recordings, resulting in high quality clas-
 202 sification of signal sources (Blanche et al., 2005; Gray et al., 1995).

203 The solution to the problem of classifying multichannel scalp EEG
 204 events presented here is based on *Wave_clus*, a spike sorting algorithm
 205 that performs a wavelet decomposition of the signals in combination
 206 with superparamagnetic clustering, a clustering method from statistical
 207 mechanics (Quian Quiroga et al., 2004). This combination allows identi-
 208 fying small but consistent differences in the analysed signals. Further-
 209 more, the superparamagnetic clustering algorithm does not assume
 210 any a priori number of classes or cluster shape in the feature space.
 211 Therefore, *Wave_clus* is an ideal candidate for the analysis of IED and
 212 their classification according to the waveforms provided by different
 213 electrodes.

214 Fig. 1 shows a summary of the steps followed for IED processing in a
 215 representative case (#7). For the automated processing of the IED we

band passed the recorded signals. We heuristically explored a range of 216
 low cut frequencies the recorded signals between 0.5 and 10 Hz, 217
 reaching best performance at 4 and high cut frequency of 50 Hz using 218
 an 8 order elliptic band pass filter. Next, we selected a subset of between 219
 8 and 12 most active channels for each patient based on the clinical 220
 evidence (Fig. 1A). EEG channel selections are described in Table 1. 221
 Next, for each IED visually identified by the expert a window of 222
 300 ms around the marked time (from 80 ms pre-peak to 220 ms 223
 post-peak) was used for processing each of the channels selected. To 224
 provide robustness against possible jitter sources for each event in the 225
 signal of different channels, the IED were aligned at their negative 226
 peak found within a 40 ms window centred at the time of the channel 227
 presenting larger amplitude of the IED. For each IED, the signals from 228
 the selected channels were then concatenated to form what we call a 229
 'meta-IED' (Fig. 1B). 230

Each dataset (2 or 3 EEG–fMRI sessions), consisting of all the meta- 231
 IED for a given patient's recording, was then analysed with *Wave_clus* 232
 independently from the expert classification. First, the algorithm 233
 performed a wavelet transform of the meta-IED using Haar wavelets, 234
 which are ideal to capture small variations in the signal. Then, the coef- 235
 ficients obtained were tested for multimodality to distinguish between 236
 the variances due to noise (supposing this is normally distributed) 237
 and the ones reflecting two or more consistent values (multimodal 238
 distributions), using a Kolmogorov–Smirnov test (see Quian Quiroga 239
 et al., 2004 for details), thus providing coefficients that potentially sepa- 240
 rate the spikes into different clusters. In our case we selected a total 241
 number of coefficients equal to 8 times the number of channels of the 242
 meta-IED data (i.e. 8 wavelet coefficients per 75 data points). The 243
 obtained coefficients were then introduced in the superparamagnetic 244

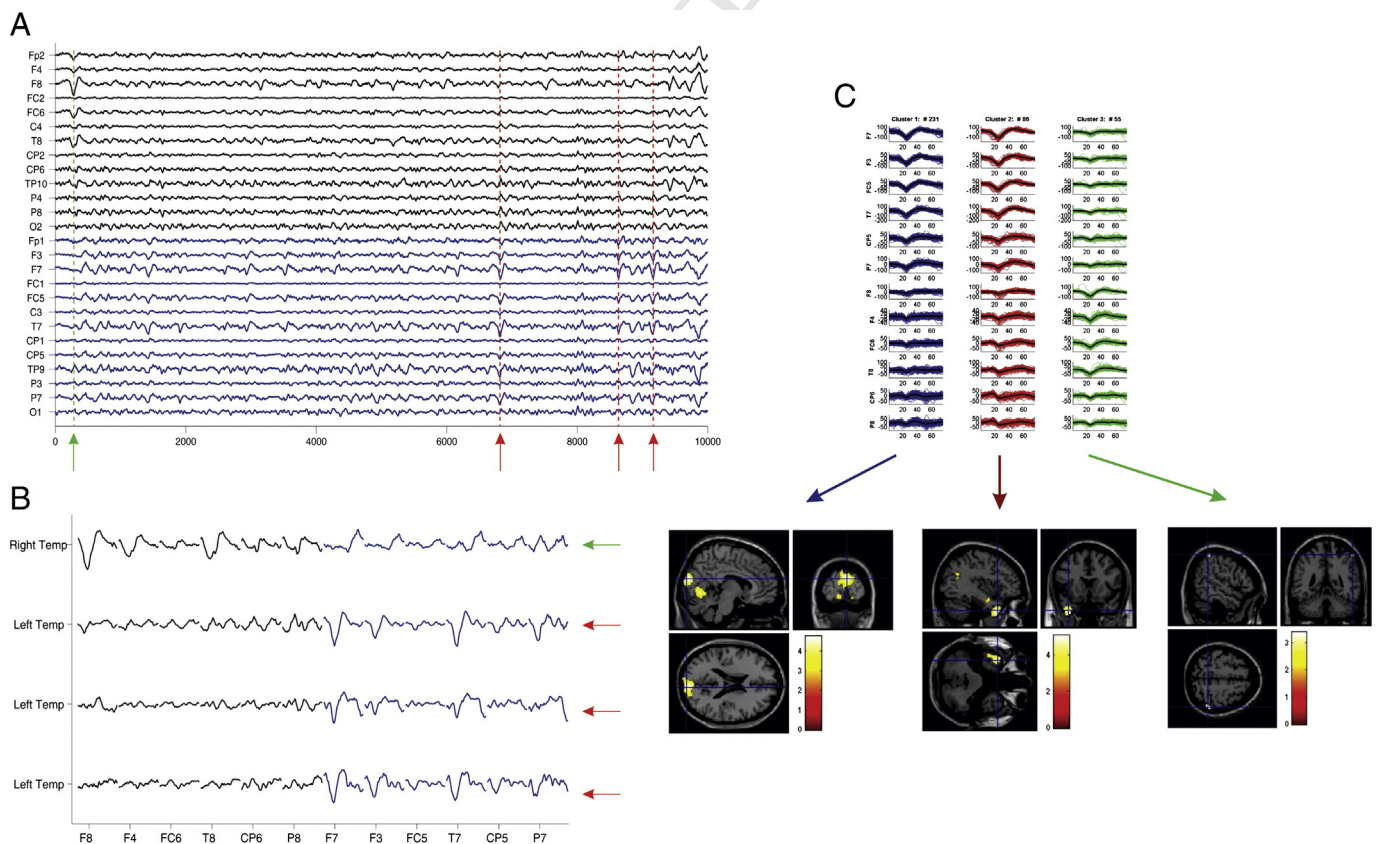


Fig. 1. Summary of cluster sorting process for EEG recordings with *Wave_clus*, example from case #7. Panel A: The continuous signal was filtered and the events marked by the expert. In the example, the green arrow indicates a right temporal event and the red arrows the left temporal events. Panel B: Composition of the meta-IED using the selected channels based on clinical criteria. Panel C: Clusters obtained with *Wave_clus* and associated fMRI maps. For Class 1 there was a cluster of BOLD signal increase over the bilateral cuneus and the mesial occipital cortex (left). Class 2 presented a cluster of activation in the left temporal pole (middle). Class 3 presented a cluster of activation in the right parietal lobe, BA40 (right). Results are displayed on the canonical T1-weighted image ($p < 0.001$ uncorrected for FWE). R = right; L = left.

Table 1
IED classification results.

Case	Epilepsy syndrome and localisation	Visual IED classification/n° of IED	EEG channels selection	Wave_clus IED classification/no of IED
#1	R TLE	<u>IED1</u> . L T/666 <u>IED2</u> . R T/468	F8, T8, FC6, CP6, FT8, T7, P7, CP5, TP9, TP7	<u>C1</u> . Low amplitude L FT/390 <u>C2</u> . Low amplitude R FT/210 <u>C3</u> . High amplitude L FCT/127 <u>C4</u> . Low amplitude B O Slow wave/149 <u>C5</u> . High amplitude L TP spikes with R FT diffusion/84 <u>C6</u> . High amplitude B FT(>L)/85 <u>C7</u> . High amplitude R FCT/89 <u>C1</u> . High amplitude R F/1329 <u>C2</u> . Low amplitude diffuse/378 <u>C3</u> . High amplitude diffuse/553
#2	R FLE	<u>IED1</u> . R F/2260	Fp2, F4, F8, P8, O2, Fp1, P7, O1	<u>C1</u> . Low amplitude B FC (>R)/227 <u>C2</u> . Low amplitude L FT/20 <u>C3</u> . High amplitude diffuse (>CT)/58 <u>C4</u> . Low amplitude diffuse/61
#3	R FLE	<u>IED1</u> . B F (>R)/253 <u>IED2</u> . R F/71 <u>IED3</u> . L T/21 <u>IED4</u> . L F/18 <u>IED5</u> . R T/2	Fp2, F4, FC6, T8, CP6, P8, Fp1, F3, FC5, T7, CP5	<u>C1</u> . Low amplitude B FC (>R)/227 <u>C2</u> . Low amplitude L FT/20 <u>C3</u> . High amplitude diffuse (>CT)/58 <u>C4</u> . Low amplitude diffuse/61
#4	L PLE	<u>IED1</u> . L P Sh-W/139 <u>IED2</u> . L P/94 <u>IED3</u> . L P-T/20 <u>IED4</u> . L P PP/12	F4, C4, P4, FC2, CP2, F3, C3, P3, FC1, CP1	<u>C1</u> . High amplitude L CPT/187 <u>C2</u> . Low amplitude L CPT/56 <u>C3</u> . High amplitude L CP/23
#5	L FLE	<u>IED1</u> . L F/114 <u>IED2</u> . L F Sh-W/74 <u>IED3</u> . L F PP/64 <u>IED4</u> . L F ant/60 <u>IED5</u> . L F inf/38 <u>IED6</u> . L F SW/19 <u>IED7</u> . L F Sh-Th/3	Fp2, F4, F8, T8, P8, Fp1, F3, F7, T7, P7	<u>C1</u> . Low amplitude diffuse/138 <u>C2</u> . Low amplitude B F(>L)/67 <u>C3</u> . High amplitude diffuse(>F)/127 <u>C4</u> . Low amplitude L F/44
#6	L TLE	<u>IED1</u> . L T/225	Fp1, F7, F3, FC5, T7, C3, FC5, P7, P3, O1	<u>C1</u> . High amplitude L Hemisphere (>T)/186 <u>C2</u> . Medium amplitude L Hemisphere (>CT)/39 <u>C1</u> . High amplitude L FT/231 <u>C2</u> . High amplitude L FT with diffusion to R CP/86 <u>C3</u> . Low amplitude R T/55
#7	L OLE	<u>IED1</u> . L T/311 <u>IED2</u> . R T/60 <u>IED3</u> . B T/1	F7, F3, FC5, T7, CP5, P7, F8, F4, FC6, T8, CP6, P8	<u>C1</u> . Low amplitude B FCP/210 <u>C2</u> . High amplitude B FC/60 <u>C3</u> . Low amplitude B F(>r)/67
#8	R PLE	<u>IED1</u> . Midline Cz/206 <u>IED2</u> . R FC/121 <u>IED3</u> . R F/10	Fp1, AF3, FC1, CP1, Fp2, AF4, FC2, CP2	

Legend Table 1: IED: Interictal Epileptic Discharges; C: Classes according to Wave_clus; L: left; R: right; B: bilateral; F: Frontal; T: Temporal; P: Parietal; O: Occipital; PT: Parieto-Temporal; FC: Fronto-Central; CT: centro-temporal; FCP: fronto-centro-parietal; FCT: fronto-centro-temporal; sup: superior; ant: anterior; inf: inferior; post: posterior; Sh-W: Sharp-Waves; PP: polyspikes; SW: Spike-Waves; inf: inferior; ant: anterior; Sh-Th: Sharp-Theta. See text for details. The black colour underlining identifies the IED classes (for both visual and automatic labelling) more clinically relevant.

clustering algorithm, obtaining the proposed automatic classification of IEDs. When the automatic solution was not fully satisfactory the user could use the provided interface to merge or reject the automatically obtained clusters candidates to reach a better solution. This process was performed with the results of the manual classification hidden from the user performing the clustering. The upper part of Fig. 1C shows the 3 classes obtained from the selected channels. We then obtained the fMRI localization of each class, as shown in the bottom of Fig. 1C.

After classification, we computed the mean (over 1 s) of the signal across all EEG channels for each class. We then labelled the Wave_clus classes based on the scalp localization and amplitude of the events. In section S1 of the Supplementary Material the level of agreement between the non-invasive defined IZ localization and IED type is quantified for both classification methods.

In addition, we compared the visual-based classification with the automatic approach in terms of number of IED classes and their topographic distribution on the scalp (see Supplementary Material S1).

fMRI data analysis

In order to map BOLD changes related to the IEDs, we analysed fMRI data within the General Linear Model (GLM) framework.

For each patient, two fMRI models were employed, one correlated to IED as classified visually (GLM1), the second using IED classes labelled using Wave_clus (GLM2). All fMRI data were pre-processed and analysed using SPM8 (<http://www.fil.ion.ucl.ac.uk/spm/>). After discarding the first four image volumes (T1 saturation effects), the EPI time series

were realigned, and spatially smoothed with a cubic Gaussian Kernel of 8 mm full width at half maximum. fMRI time-series data were then analysed to determine the presence of regional IED-related BOLD changes. Motion-related effects were modelled in the GLM by 24 regressors derived from the 6 scan realignment parameters (Friston et al., 1996). An additional set of confounds was included to account for large head movements (Lemieux et al., 2007) and cardiac-related signal changes (Liston et al., 2006). The stick functions representing the IED onsets were convolved with the canonical hemodynamic response function (HRF) plus its temporal and dispersion derivatives testing for IED-related BOLD signal changes.

Two T contrasts were specified to test for significant IED-related BOLD increases and decreases respectively; the resulting SPM were thresholded at $p < 0.001$ (uncorrected for multiple comparisons) with an additional extent threshold of five voxels. In cases where no significant change was related for T contrasts over the individual IED types, we used an F contrast across all IED types to assess the presence of BOLD change related to any linear combination of the various IED classes. The results were overlaid onto the subject's structural MRI (T1 image) or mean EPI for illustration purposes.

Comparison of the EEG–fMRI results with electro-clinical information and intracranial EEG recordings

To test our main hypothesis, the BOLD maps resulting from the two GLMs were compared for each IED class. More specifically, the following BOLD map features were considered for the comparison: 1) the BOLD cluster containing the statistically most significant change (global

297 maximum: GM); 2) other, less significant, BOLD clusters, except those
 298 located in the ventricular system, vascular tree and confined to the
 299 edges of the brain. For patients who underwent invasive EEG recording
 300 during the pre-surgical workout, we compared the BOLD maps with the
 301 invasively-defined IZ. For patients who did not undergo icEEG, we
 302 compared the BOLD maps with the presumed IZ, which was defined at
 303 the lobar level on the basis of non-invasive electro-clinical information
 304 (epileptiform discharges recorded on clinical long term video EEG
 305 recordings, seizures semiology, radiological findings, PET and ictal
 306 SPECT if available) (Pittau et al., 2012).

307 For both subgroups of patients, the degree of concordance of the
 308 EEG–fMRI results with the IZ was determined by visual inspection of
 309 the SPM for each IED class. Following our previous work (Chaudhary
 310 et al., 2012), for each IED class, the level of concordance of the positive
 311 and negative BOLD maps was classified in the following categories:

- 312 • Concordant [C]: all BOLD clusters within the IZ (within 2 cm around
 313 the IZ and in the same lobe).
- 314 • Concordant plus [C +]: GM BOLD cluster within the IZ (within 2 cm
 315 around the IZ in the same lobe), and at least one cluster remote
 316 from the IZ.
- 317 • Discordant plus [D +]: GM BOLD cluster remote from the IZ and at
 318 least one cluster in the IZ (within 2 cm around the IZ in the same lobe).
- 319 • Discordant [D]: all clusters remote from the IZ.
- 320 • Null [N]: no significant clusters.

321 In addition, the algorithm-derived fMRI maps were compared to
 322 check for over-classification of IED. A sign of over-classification would
 323 be (practically) identical maps for different IED classes. This was noted
 324 if present, on the basis of the fMRI results only, without considering
 325 the expert's visual IED classification.

326 Results

327 **Table 2** summarises the clinical data obtained using conventional as-
 328 sessment methods. Structural MRI scans revealed right frontal atrophy
 329 without any clear focal lesion in one patient (#2), FCD in 3 patients
 330 (#4, #7 and #8) and no anatomical abnormality in the rest. Four out
 331 of eight patients subsequently underwent icEEG (#2, #4, #7 and #8).
 332 In one subject icEEG was not performed due to seizure onsets at several
 333 discrete sites. In all cases there was good correspondence between SOZ
 334 and IZ. For the four patients in whom surgery was performed, surgical
 335 outcome at 12 months post-operatively was assessed: three patients
 336 (#4, #7, #8) were seizure-free after resection (ILAE 1) and in the
 337 other (#2) there was a poor outcome (ILAE 5).

t2.1 **Table 2**
 t2.2 Patients' electro-clinical details.

t2.3	PT	Epilepsy syndrome	Gender/age	IEDs	Ictal EEG	Structural MRI	Intracranial EEG	Surgical outcome at 12 months
t2.4	#1	R TLE	M/24 years	Independent R FT, mid-T, Spikes; L T spikes	R hemisphere onset, probably multifocal	Normal	N/A (Multifocality)	N/A
t2.5	#2	R FLE	M/25 years	Bi-F spike wave discharge. (Max: F4-C4)	Continuous bi-F rhythmic spike-wave discharges max F4-C4	R F atrophy	SOZ = IZ: R pre-F cortex, ACC, mesial SMA	Class 5
t2.6	#3	R FLE	M/25 years	SWD 3–4hz, anterior predominant R > L	fast activity over right hemisphere	Normal	Awaiting	N/A
t2.7	#4	L PLE:	F/29 years	L P and L PT sharp waves and slow wave	LP fast activity with spread to anterior leads	FCD over L angular gyrus	SOZ = IZ: L angular gyrus	Class 1
t2.8	#5	L FLE	F/41 year	L F (F3) Spikes, Bilat SWD (LF emphasis)	bifrontal theta, bilat SWD	Normal	Declined	N/A
t2.9	#6	L TLE	M/19 years	L T Spikes	L T rhythmic theta	Normal	Declined	N/A
t2.10	#7	L OLE	M/24 years	L mid-post sharp-waves (max T3–T5)	Left posterior TP;	L O FCD	SOZ = L medial OL IZ = L OL, R OL, L medial PL	Class 1
t2.11	#8	R PLE	M/31 year	RP and R central spikes	Not specific	R P FCD	SOZ = IZ: R pericentral cortex	Class1 (5 months)

t2.12 Legend: R = right, L = left, IZ = irritative zone, SOZ = ictal onset zone, T = Temporal, F = Frontal, O = Occipital, P = Parietal, TLE = temporal lobe epilepsy, PLE = parietal lobe epilepsy,
 t2.13 FLE = frontal lobe epilepsy, Inf = inferior, Sup = superior, EEG = electroencephalogram, FCD = Focal cortical dysplasia, ACC = anterior cingulate cortex, SMA = supplementary motor
 t2.14 area, N/A = not available, SWD = spike-wave discharges, M = male, F = female, FCD = focal cortical dysplasia, OL: occipital lobe, PL: parietal lobe.

IED classification

338

The average number of IED identified per patient during EEG–fMRI 339 was 411 events (range: 225–2260). **Table 1** describes the IED classifica- 340 tions for the two methods for each patient. The most clinically relevant 341 IED classes (in terms of concordance with the clinical hypothesis, not 342 considering invasive procedures) for both classification methods are 343 underlined in the table. In the Supplementary Material S1 we provide 344 a more detailed description and comparison of the topographical results 345 for both classification methods. Additionally, Supplementary Fig. S1 346 illustrates the algorithmic classification results and plots of the mean 347 IED waveform for each class and Supplementary Figs. S2–S9 show the 348 topographic distribution of amplitudes for each class at the time of the 349 spike peak. 350

Visual IED classification

351

352 Across all subjects a total of 26 IED types were visually identified. 353 There was a single IED type identified in 2 patients (#2 and #6), and 354 two or more IED types in the other cases (#1, #3, #4, #5, #7 and #8). 355 The differentiating IED feature was related to localization in 4 patients 356 (patients #1, #3, #7 and #8), morphology in one (#5) and a combina- 357 tion of both in another (#4).

Algorithmic (Wave_Clus) IED classification

358

359 A total of 29 IED classes were identified by the automatic approach 360 across the group; for each subject at least two (#6) or more (#1, #2, 361 #3, #4, #5, #7 and #8) IED types were found. The differentiating IED 362 trait was related to localization in 3 patients (patients #1, #7 and #8), 363 spike amplitude in one (#6) and a combination of both in the remaining 364 (#2, #3, #4 and #5).

IED-related BOLD changes

365

We compared the EEG–fMRI results for the models derived from the 366 visual (GLM1) and the algorithmic (GLM2) IED classifications. **Table 3** 367 summarises the EEG–fMRI results for the two IED classifications. In 368 the following, we describe the BOLD changes for all cases, followed by 369 a comparison of the GLM2 and GLM1 results. 370

Comparison of interictal BOLD changes with the invasively-defined IZ

371

372 In the four patients (#2, #4, #7, #8) who underwent icEEG record- 373 ings, the structural MRI scan revealed brain abnormalities in all of them.

374 **GLM1.** The BOLD global maximum was located within the IZ (concor- 375 dance classified as C or C+) related to one type of visually labelled

Table 3
fMRI data analysis results.

Case	Clinical IZ localization	FMRI results (visual IED classification)				FMRI results (<i>Wave_clus</i> IED classification)			
		BOLD Signal Changes (sign of peak change)		Level of concordance		BOLD signal changes (sign of peak change)		Level of concordance	
		C	C+	D+	D	C	C+	D+	D
#1	Uncertain, probably R T lateralized	IED1: B TL mid-post (d)(GM) + L TL pole (i) IED2: R post cingulate (d)(GM)				C1. R SMA(i)(GM) + R sup F gyrus(i/d) C2. C3. L TL mid-post(d) (GM) + L TL pole(i) C4. C5. C6. C7. R middle T gyrus(i)(GM)			
#2	SOZ = IZ: R pre-F cortex, ACC, mesial SMA	IED1: DMN(d)(GM) + R ACC(i) + R sup T gyrus(i) + R Medial F gyrus(i) + R SMA(BA6) (i) + Brainstem(d)				C1. R orbitofrontal(i)(GM) + ACC(i) + R SMA(i) + R prefrontal (i) + DMN(d) + Brainstem(d) + BG(d) C2. C3. R sup T gyrus(GM) (i) + R orbito-frontal(i) + DMN(d) + Brainstem(d) + BG(d)			
#3	Uncertain, probably R F lateralized	IED1: B Sup F Gyrus (>R)(i)(GM) + L perisylvian (i) + Posterior DMN (d) IED2: L cerebellum (GM) IED3				C1. B cerebellum (>L) (i/d)(GM) + R Sup F gyrus(i) + post T cortex(i) + L perisylvian(d) C2. C3–C4. B perisylvian(i)(GM) + L medial F gyrus(i) + R PC(i) + L precentral F(i)			
#4	SOZ = IZ: L angular gyrus	IED1: L PL (i)(GM) IED2 IED3: L medial F gyrus (i) (GM)				C1. B PL(>L)(i)(GM) + L cerebellum(d) C2. L medial F gyrus(i) (GM) + L orbitofrontal cortex + B (>L) T pole(i) C3. R orbitofrontal cortex(GM) + B(>L) medial F gyrus(i) + B T (>R) pole(i) + B O cortex			
#5	Uncertain, probably LF lateralized	IED4: L precentral cortex (i)(GM) (IED1 + 2 + 3 + 4*); L Sup F Gyrus (i)(GM) IED5 IED6 IED7				C1–C4. L Sup F Gyrus(i)(GM) C2. C3.			
#6	Uncertain, probably L T lateralized	IED1: Pc(d)(GM) + L F precentral(i) + B TL(d)				C1. L F precentral(i)(GM) + B TL(d) + Pc(d) C2. L T pole(i) + Post TL (i)(GM)			
#7	IZ = L OL, R OL, L medial PL	IED1: B Mesial O cortex (i) (GM) + L O Pole (i) IED2 IED3				C1. B Mesial O cortex(i)(GM) + B cuneus + brainstem(d) C2. L T pole(i)(GM) C3. R P lobe(i)(GM)			
#8	SOZ = IZ: R pericentral cortex	IED1: R Middle F gyrus (i) (GM) IED2: R Medial F gyrus (i) (GM) IED3				C1. R Medial F gyrus(i)(GM) C2. R Middle F gyrus(i)(GM) C3. L Prefrontal cortex(i)(GM)			

Legend table 3 IED: Interictal Epileptic discharges; L: left; R: right; SOZ: Seizure Onset Zone; IZ: Irritative Zone; B: bilateral; F: Frontal; T: Temporal; P: Parietal; O: Occipital; PT: Parieto-Temporal; FC: Fronto-Central; sup: superior; ant: anterior; inf: inferior; post: posterior; Sh-W: Sharp-Waves; PP: polyspikes; SW: Spike-Waves; inf: inferior; ant: anterior; Sh-Th: Sharp-Theta. ACC = Anterior Cingulate Cortex ; SMA: Supplementary Motor Area; BG: basal Ganglia; Pc: precuneus; th: thalamus; DMN: Default Mode Network; TLE Temporal Lobe Epilepsy; (d): deactivation; (i): activation; N/A: not available; SOZ: Seizure Onset Zone; IZ: Irritative Zone. BOLD: blood oxygen level-dependent signal; WC: wave_clus *: F contrast across all the IED classes. C: concordant; C+: concordant Plus; D: discordant; D+: discordant plus; N: null. GM: cluster of global maxima on fMRI maps. The black underlining shown the most clinically relevant IED classes related to both classification methods (see text for details).

IED in each case (IED1 for patients #4 and #7; IED2 for patient #8) and hemodynamic changes found within the brain lesion in three patients (75%). The other IED types were correlated with [N] results (IED2 for patients #4; IED 2 and 3 for patient #7; IED3 for patient #8) or discordant (IED3 and IED4 in #4, IED 1 in #8). For patient #2, the BOLD maps were classified as discordant plus [D+]. Interestingly, this patient is the only with poor surgery outcome (Class 5) and further surgery is planned.

With respect to the most clinically relevant IED types (Tables 1 and 3), there was a good correspondence between the GM-BOLD localization within IZ and the IED classification in two cases (50%): in patient #4, among the four IED types considered congruent with the IZ, only IED type 1 revealed [C] results. In patient #8, the fMRI map for IED type 2 was [C], and [D] for IED type 1. For patient #2, the BOLD map for the only visually labelled IED type (congruent with clinical hypothesis) was [D+]. Finally, in patient #7 the BOLD for IED type 1 (left temporal spikes) was found to be [C+].

GLM2. The BOLD global maximum related to one IED class (C1 for patients #2, #4, #7, #8) was located within the IZ (concordance classified

as C or C+) in all patients (100%) and hemodynamic changes found within the brain lesion. The BOLD changes for the other IED types (C2–C3 for patients #4; C2–C4 for patient #7; C2–C3 for patient #8), [D+] (C3 in #2) or [N] (C2 in #2) were classed [D].

With respect to the IED types considered most clinically relevant, the BOLD map was classed as [C] or [C+] in 3/4 cases (75%): in patient #2, the only IED class considered congruent with the clinical hypothesis revealed a [C+] BOLD map; in patient #4, the BOLD map for only one IED class among the 3 considered to be clinically significant had a good degree of concordance [C+]; in patient #8, the only IED class considered congruent with the clinical hypothesis (C1) was associated with a concordant [C] BOLD map.

Comparison of interictal BOLD changes with the non-invasively defined (presumed) IZ

In the four cases (#1, #3, #5, #6) who did not undergo icEEG recordings, no structural abnormality was detected on MRI.

GLM1. The GM was located within the IZ in two cases (50%): in patient #3 both IED types 1 and 2 revealed concordant plus [C+] results; in

patient #5, the fMRI maps obtained when IED types 1,2,3,4 were considered together were classified as concordant [C]. For both cases the other IED types did not show any significant BOLD cluster (classified as [N]). The maps were discordant [D] and discordant plus [D+] in patient #1 and discordant in patient #6.

Regarding the most clinically relevant IED types, there was good concordance in two patients (50%): in subject #3, both congruent IED types revealed [C+] findings; in patient #5, as previously observed, the four clinically significant IED types were associated with concordant [C] fMRI maps when considered together (F contrast across the four sets of regressors). Finally, for patient #1 and #6, the maps were discordant [D] for each of the most clinically relevant IED types (one per patient).

GLM2. The BOLD maps had a good degree of concordance in three cases (75%): in patient #1, the C7-related BOLD map was classed as concordant [C]; for patient #5, classes C1 and C4 were associated with concordant [C] BOLD maps; finally in patient #6, the BOLD map associated with the C2 IED was classed as concordant plus [C+]. The remaining IED classes were associated with discordant plus [D+] (classes C1, C3–C4), discordant [D] (C1 in patient #1, C1 in patient #6), [D+] (C3 patient #1) or Null [N] (C2, C4, C5, C6 for patient #1; C2–C3 for patient #5) or null [N] (class C2) BOLD maps.

Regarding the most clinically meaningful IED types, the BOLD maps had a good degree of concordance in three of the patients (75%): in case #1 two IED classes (C2, C7) had topographic distribution concordant with the electro-clinical hypothesis and the associated BOLD maps were discordant [D] for C2 and concordant plus [C+] for C7. In patient #5 class C1 was associated with a concordant BOLD map. Finally for patient #6, C2 IED were associated with a concordant BOLD pattern. For patient #3, the low amplitude bilateral fronto-central spikes (C1) considered congruent with clinical hypothesis were associated with a discordant [D] BOLD map.

Comparison of the GLM1 and GLM2 BOLD results

In summary, 13/26 (50%) visual IED types were associated with one or more regions of significant BOLD signal increase or decrease. At least one cluster of significant BOLD signal increase was detected in every patient, although not for all IED types. No region of significant BOLD change was revealed for one (patients #4 and #8), two (#7) or three (#3 and #5) IED types. In addition, in one patient (#5) in whom 5 out of the 7 IED types had a similar distribution on the scalp, regions of significant BOLD signal changes were revealed only when an SPM{F} contrast across the first four IED types was used. For the Wave_clus IED classification results, 21/29 IED classes were associated with significant BOLD signal changes (72%, compared to the 50% of visual classification), corresponding to a substantial increase in sensitivity. In all the classes a significant BOLD signal change was revealed except for the following: for patient #1, IED classes C2, C4, C5 and C6; C2 for patients #2 and #3; C2 and C3 for patient #5.

In the cases #7 and #8, in whom the algorithm IED classification matched completely (see Supplementary Material S1) with the one provided by the expert, GLM1 and GLM2 revealed maps with similar degrees of concordance; GLM2 revealed the same BOLD clusters as GLM1, plus 3 additional clusters (Table 3).

In cases when the algorithmic process demonstrated more IED classes than visual labelling (patients #1, #2 and #6), the degree of concordance was greater for GLM2 than for GLM1. Specifically, the GLM2 maps revealed additional clusters than the GLM1 maps (C7 in patient #1 and C2 in #6) or were similar to the GLM1 result but with greater concordance (for C1 in patient #2). There was only one BOLD cluster revealed by GLM1 that was not revealed by GLM2: the right posterior cingulate BOLD signal decrease related to IED2 in patient #1.

In cases when the algorithmic clustering identified fewer IED classes than the expert (patients #3, #4 and #5), the GLM2 and GLM1 were similarly concordant [C or C+] in two (#4 and #5). In these two cases, no BOLD clusters were lost. Furthermore, four additional clusters

were revealed by GLM2 in patient #4 (see Table 3). In patient #3, in whom the algorithmic labelling failed to recognize as independent the right frontal, right temporal and left frontal IED, the GLM2 maps were classified as [D] in contrast to the GLM1 results. However, no BOLD clusters were lost and five additional clusters were revealed by GLM2 (see Table 3).

Representative examples

In the following, we present five particular cases to illustrate the characteristics of the algorithmic sorting. The cases presented represent two outcomes where the algorithm provides a better outcome (cases #1 and #6), one case in whom the two classification approaches revealed overlapping results, although with different SPM contrasts (case #5), the case where the reached solution did not match the expert solution and the outcome was not satisfactory in general terms (case #3) and finally one patient in whom the visual and the algorithm solutions gave similar findings in term of BOLD changes (cases #8). The results for the other cases are described and illustrated in the Supplementary Material (Supplementary Material S2, Supplementary Figs. 3, 4, 5).

Case 1 (Fig. 2)

Clinical background. Patient with pharmaco-resistant focal epilepsy, probably arising from the right temporal lobe. Video telemetry showed independent right fronto-temporal and mid-temporal spikes, left temporal spikes as well as bilateral spike-and-wave discharges. In the majority of seizures recorded, the EEG demonstrated fast waves and then epileptic discharges in right temporal regions (mid-temporal and posterior) followed by rapid spread over the left temporal cortex. Ictal semiology pointed towards a right neocortical origin. Nevertheless, this pattern was not consistent through the time and a more mesial origin with rapid spread over the neo-cortex wasn't excluded as well as a multifocal epileptogenic zone with the involvement of the left mesial temporal hemisphere. In term of IZ localization, the presence of two asynchronous IED types, the absence of MRI lesion and the not definitive localization of the SOZ did not allowed to exclude a complex interictal network, even multifocal. An interictal PET study showed left and right sided abnormalities, however the right temporo-parietal hypometabolism was the most prominent; a multifocal IZ (involving the right and the left temporal cortex) was suspected and the patient did not undergo intracranial recordings or surgery.

IED classification. The expert visually identified two IED types: right (N = 468) and left (N = 666) temporal spikes (Fig. 2A). The algorithmic sorting identified 7 IED classes (Fig. 2C): 3 with mostly left temporal localisation and which were differentiated by either amplitude [class #1 (N = 390; shown in blue in Fig. 2C) and class #3 (N = 127; green)] or the involvement of the right fronto-temporal region for class #5 (N = 84; magenta). Classes #2 and #7 consisted of right temporal spikes (N = 210; red and N = 89; grey). Class #6 consisted of high amplitude bilateral fronto-temporal spikes with emphasis on the left (N = 85; yellow). Class #4 consisted of very low amplitude bilateral occipital slow waves (N = 149; cyan). See Supplementary Material S1 for a quantification of the level of agreement between the two methods of IED classification.

EEG–fMRI results. The GLM1 maps corresponding to the two IED types were classified as discordant plus [D+] for the left IED and discordant [D] for the right IED. The left temporal IEDs were associated with a region of BOLD increase in the left temporal pole and decrease in the mid-posterior temporal lobe (GM) (Fig. 2B). The right temporal events were associated with a region of decrease in the right posterior cingulate (GM) (Fig. 2B).

GLM2 revealed BOLD signal changes over the right SMA (GM; increase) and the right superior frontal gyrus (clusters corresponding

Visual IED classification based fMRI analysis

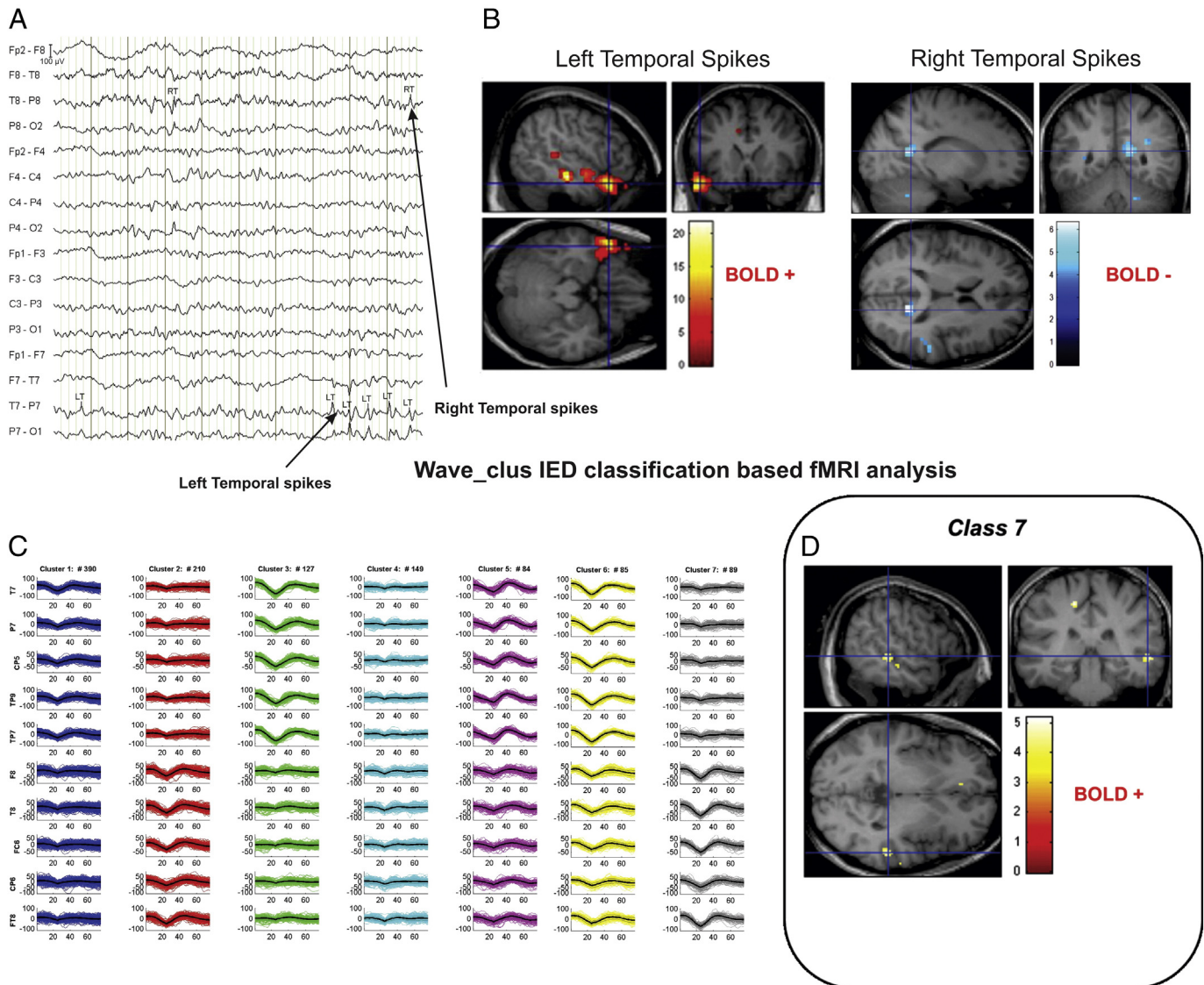


Fig. 2. Visual and algorithmic classification for the IED of case #1. The top of the figure (Panel A) presents the result of the classification of the IEDs according to the visual classification performed by the expert. The EEG was recorded during scanning after scanning and pulse artefact subtraction. The EEG trace is displayed as bipolar montage (64 channels). Two main classes of IED were marked: LT = Left Temporal Spikes; RT = Right Temporal Spikes. Panel B: EEG–fMRI data analysis results based on visual-IED labelling (T contrast, $p < 0.001$ uncorrected). See text for a detailed description of the IED-related BOLD changes. Panel C shows the 7 classes identified by the algorithmic solution. On the right hand side (Panel D) the result of the EEG–fMRI data analysis (T contrast, $p < 0.001$ uncorrected) associated to the class7 are displayed: a right middle temporal gyrus (BA22) BOLD signal increase is noted (crosshairs at the GM). All the fMRI results are overlaid on the subject's T1 image. BA: Brodmann Area. R = right; L = Left.

537 to increase and decrease) associated with the low amplitude left fronto-
 538 temporal spikes (C1); high amplitude left fronto-centro-temporal
 539 events (C3) were associated with a left temporal pole region of BOLD in-
 540 crease and a left mid-posterior temporal lobe region (GM) of decrease;
 541 high amplitude right fronto-centro-temporal spikes (C7) were associat-
 542 ed with a global maximum cluster in the right middle temporal gyrus
 543 increase (region BA22; Fig. 2D). No significant clusters were found for
 544 C2, C4, C5 and C6 (hence classified as [N]). The degree of BOLD concor-
 545 dance was [C] for C7, [D] for C1 and [D+] for C3. Supplementary Fig. 2
 546 shows the GLM2 results related to all IED classes. In summary, for
 547 patient #1 the algorithmic solution revealed a cluster of BOLD signal
 548 increase in the right temporal lobe probably representing the correct
 549 IZ, not previously observed.

Case 3 (Fig. 3)

550

Clinical background. Patient with right frontal lobe epilepsy. Interictal 551
 EEG showed diffuse Spike-Wave discharges with anterior and right pre- 552
 dominance. Sleep is associated with increased IED occurrence. Left tempo- 553
 ral IEDs were also recorded. Ictally, the EEG demonstrated a right 554
 frontal seizure onset in keeping with semiology. Based on the available 555
 electro-clinical data the presumed SOZ was located in the right frontal 556
 lobe; the IZ was less well localized, involving the right frontal area. 557

IED classification. The expert visually identified 5 classes: bifrontal 558
 (N = 253), right frontal (N = 71), left temporal (N = 21), left frontal 559
 (N = 18) and right temporal (N = 2) spikes (Fig. 3A). The algorithmic 560

Visual IED classification based fMRI analysis

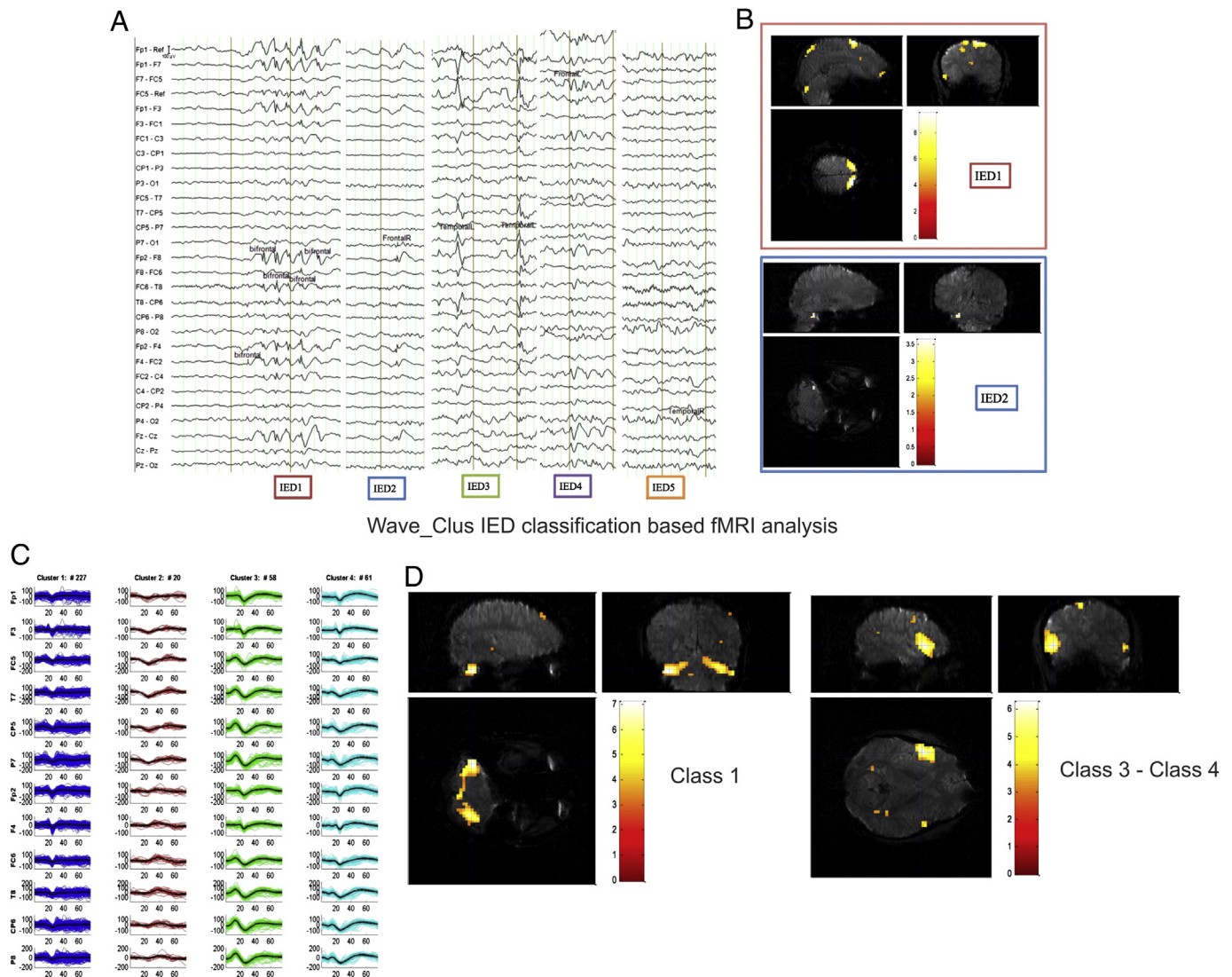


Fig. 3. Visual and algorithmic classification for the IED of case #3. The top of the figure (Panel A) presents the result of the classification of the IEDs according to the visual classification performed by the expert. The EEG was recorded during scanning after scanning artefact subtraction. The EEG trace is displayed as bipolar montage (32 channels). Five main classes of IED were marked (see main text for details). Panel B: EEG–fMRI data analysis results based on visual-IED labelling (T contrast, $p < 0.001$ uncorrected): BOLD increases were observed in the bilateral (more right) superior frontal gyrus (crosshairs at the GM) and left perisylvian cortex related to bifrontal IEDs while a widespread posterior BOLD decrease was observed covering the posterior DMN (data not shown). Right frontal Spikes were related to left cerebellum BOLD changes as increase; no hemodynamic decreases were detected. Left frontal, temporal and right temporal IEDs were not associated with significant BOLD changes. Panel C shows the 4 classes identified by the algorithmic solution. Panel D displayed the result of the EEG–fMRI data analysis associated to the *Wave_clus* IED classification algorithm (T contrast, $p < 0.001$ uncorrected): regions of significant BOLD change as increases were observed in the right left cerebellum (crosshairs at the GM), bilateral right superior frontal gyrus and left posterior temporal cortex associated with C1 events; C3 and C4 events correlated with a bilateral (more left) perisylvian cortex (crosshairs at the GM), left medial frontal gyrus, left precentral gyrus and right precuneus activations. A cluster of BOLD decrease was revealed over the left perisylvian cortex and right cerebellum for IED-C1 (data not shown). All the fMRI results are overlaid on the subject's high resolution T1 image. R = right; L = Left.

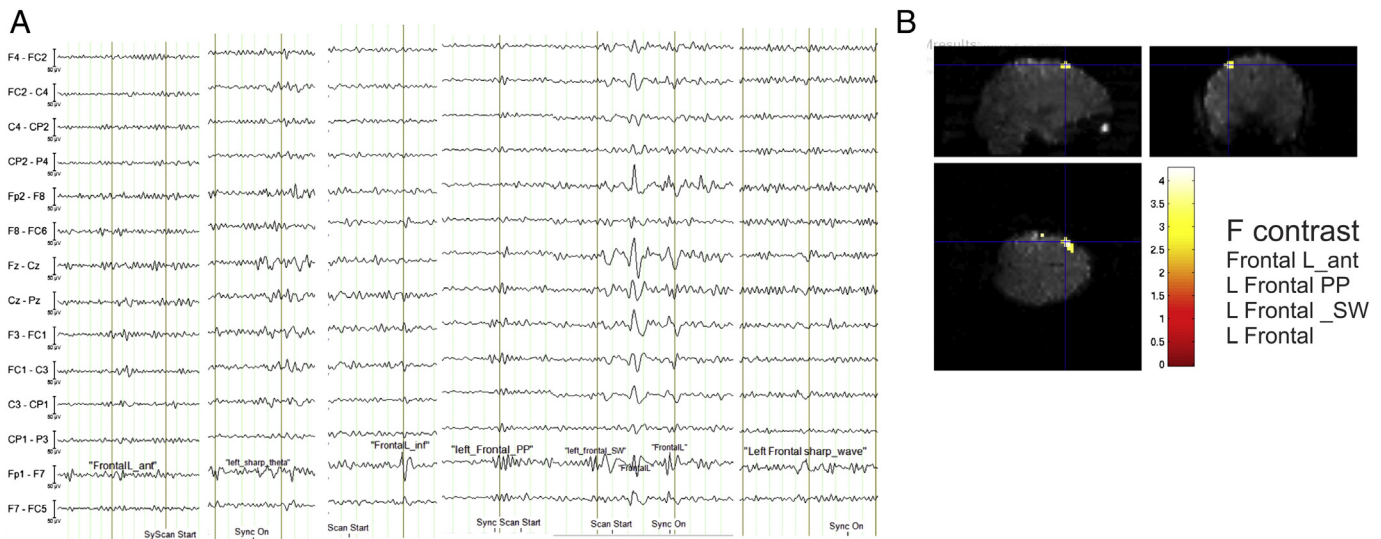
561 solution identified four classes, one corresponding to bilateral frontal
 562 events (C1, $N = 227$), one to the left fronto-temporal IED (C2; $N =$
 563 21), one to high amplitude diffuse events (more centro-temporal)
 564 (C3; $N = 56$) and the last to low amplitude diffuse events (C4; $N =$
 565 61) (Fig. 3C). We classified the level of agreement between the visual
 566 and the algorithmic classification as PM – (Supplementary Material S1).

567 **EEG–fMRI results.** GLM1 revealed a region of BOLD increase in the bilat-
 568 eral (more right) superior frontal gyrus (GM) related to the bifrontal
 569 IEDs (Fig. 3B). A cluster of activation over the left perisylvian cortex
 570 was also detected. Widespread posterior BOLD decrease covering the
 571 posterior part of the DMN was observed linked to the bifrontal IEDs.
 572 Right frontal Spikes were related to a left cerebellum BOLD changes
 573 as increase; no hemodynamic decreases were detected (Fig. 3B). The

574 degree of BOLD concordance was [C+] for IED type1 (Bifrontal spikes)
 575 and [D] for IED type 2 (R frontal spikes). Left frontal, temporal and
 576 right temporal IEDs were not associated with significant BOLD changes
 577 (hence classified as [N]).

578 GLM2 revealed regions of significant BOLD change as increases in the
 579 left cerebellum (GM), right superior frontal gyrus and left posterior
 580 temporal cortex associated with low amplitude bilateral fronto-central
 581 spikes (C1); diffuse high amplitude (C3) and low amplitude (C4) events
 582 correlated with a bilateral (more left) perisylvian cortex (GM), left medial
 583 frontal gyrus, left precentral gyrus and right precuneus activations
 584 (Fig. 3D). A cluster of BOLD decrease was revealed over the left
 585 perisylvian cortex and right cerebellum for IED-C1 (data not shown).
 586 The level of concordance was [D+] for all of these IED classes. Finally,
 587 low amplitude left fronto-temporal events (C2) did not show any

Visual IED classification based fMRI analysis



Wave_Clus IED classification based fMRI analysis

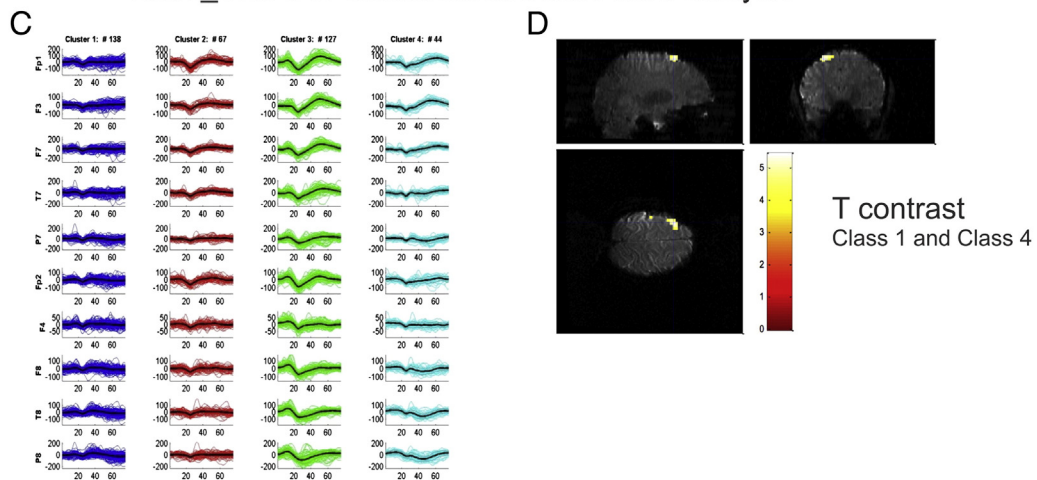


Fig. 4. Visual and algorithmic classification for the IED of case #5. Panel A presents the result of the classification of the IEDs according to the visual classification. The EEG was recorded during scanning after scanning artefact and pulse artefact subtraction. The EEG trace is displayed as bipolar montage (32 channels). Visual IED labelled 7 types of IED as described in the main text. Panel B: EEG–fMRI data analysis results based on visual-IED labelling (T contrast, $p < 0.001$ uncorrected): an increase in BOLD signal over the left superior frontal gyrus (crosshairs at the GM) was detected by means of an F contrast across the IED1, IED2, IED3 and IED4. Panel C shows the IED classification result as performed by the algorithm: four clusters of events were detected (see text for details). Panel D displayed the result of the EEG–fMRI data analysis based on the *Wave_clus* IED classification (T contrast, $p < 0.001$ uncorrected): a focal activation over the left superior frontal gyrus (GM) correlated with C1 and C4 independently (crosshairs at the GM). All the fMRI results are overlaid on the subject's high resolution T1 image. R = right; L = left.

588 significant increase or decrease in BOLD signal [N]. The patient is due to
589 undergo intracranial EEG recordings.

590 This case represents the example in which the algorithms did not
591 lead to concurrent results with the clinical evidence, resulting in fewer
592 BOLD clusters than the visual inspection method and a lower degree
593 of concordance based on the available non-invasive clinical evidence.

594 Case 5 (Fig. 4)

595 *Clinical background.* Patient with left frontal lobe epilepsy. EEG showed
596 left frontal IEDs and bilateral SWD with left predominance. Ictally the
597 EEG showed left theta activity and SWD over bilateral frontal regions.
598 Based on the available electro-clinical data a left frontal cortex SOZ
599 and IZ was hypothesized.

600 *IED classification.* Visual IED labelled 7 types of IED as left frontal spikes
601 (IED1-N = 114), left frontal sharp-wave (IED2-N = 74), left frontal
602 poly-spikes (IED3-N = 64), left frontal anterior spikes (IED4-N = 60),

left frontal inferior spikes (IED5-N = 38), left frontal spike-wave 603
(IED6-N = 19) and left frontal sharp theta activity (IED7-N = 3) 604
(Fig. 4A). The algorithmic solution identified four IED classes, one 605
corresponded to low amplitude diffuse events [C1-N = 138], one to 606
low amplitude bilateral frontal events, more left [C2-N = 67], one to 607
high amplitude diffuse (more frontal) IED [C3-N = 127] and the last 608
to low amplitude left frontal spikes [C4-N = 44] (Fig. 4C). We classified 609
the level of agreement between the visual and algorithmic classification 610
as PM-. 611

EEG–fMRI results. Visually identified IED-based EEG–fMRI analysis dem- 612
onstrated an increase in BOLD signal over the left superior frontal gyrus 613
(GM) only when IED1, IED2, IED3 and IED4 were merged together with 614
{F} contrast (Fig. 4B) classed as concordant [C]. IED5 to IED7 were not 615
associated with significant BOLD signal changes [N]. 616

The algorithmic EEG–fMRI analysis for C1 and C4 showed a focal 617
activation (GM) over the left superior frontal gyrus (Fig. 4D). The level 618
of concordance was assessed as [C] for both IED classes. C2 and C3 619

Visual IED classification based fMRI analysis

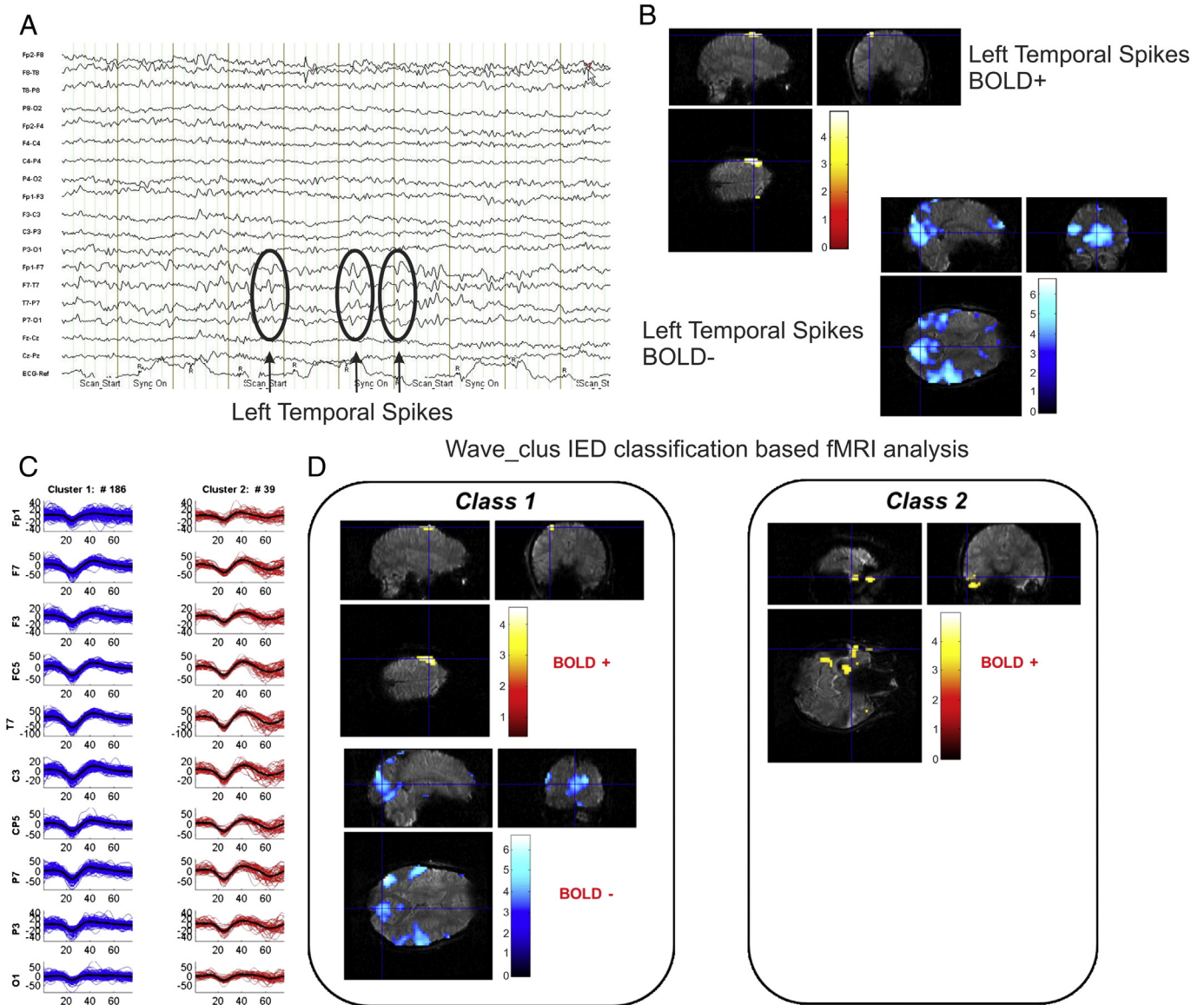


Fig. 5. Visual and algorithmic classification for the IED of case #6. The top of the figure (Panel A) presents results for the visual classification. EEG recorded during scanning after scanning artefact subtraction. The EEG trace was analysed following pulse (marked by R) and image artefact subtraction; the EEG trace is displayed as bipolar montage (32 channels). Note the presence of IED over left fronto-temporal regions. Panel B: EEG–fMRI data analysis results based on visual-IED labelling (T contrast, $p < 0.001$ uncorrected): an increase in the BOLD signal was found in the left precentral cortex and a decrease was seen over bilateral temporal lobes and the precuneus. Panel C shows the results of algorithmic labelling: 2 main classes were detected based on IED amplitude. Panel D: EEG–fMRI data analysis results based on algorithmic labelling: Class1 mapped over similar areas as the class from the visual classification did. Class2 was associated with a previously unseen activation in left temporal pole and posterior temporal lobe. No deactivation clusters were observed associated to Class2. All the fMRI results are overlaid on the subject's high resolution T1 image. R = right; L = left.

620 were not associated with significant BOLD changes [N]. The patient
621 declined icEEG recording.

622 *Case 6 (Fig. 5)*

623 *Clinical background.* Patient with left temporal lobe epilepsy. The
624 interictal EEG showed left temporal lobe IEDs; ictally, the EEG demon-
625 strated rhythmic theta activity over the left temporal lobe. Based on
626 the available electro-clinical information both SOZ and IZ are located
627 over the left temporal lobe.

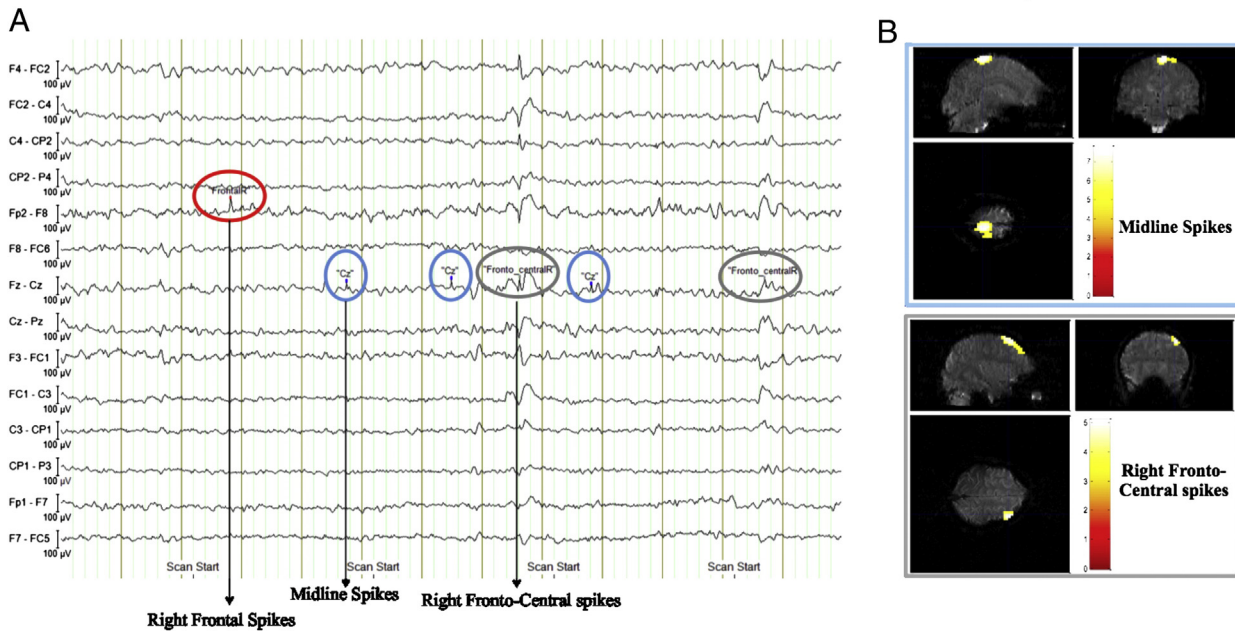
628 *IED classification.* The expert classified all events (225) as left temporal
629 spikes (Fig. 5A). The algorithmic process identified two IED classes

(Fig. 5C), one corresponding to high amplitude left spikes, mainly
630 temporal (C1; $N = 186$, shown in blue in Fig. 3C), and another one to
631 medium amplitude left IED, prevalent over the centro-temporal regions
632 (C2; $N = 39$; shown in red).
633

EEG–fMRI results. GLM1 revealed a cluster of BOLD increase located
634 in the left precentral cortex (BA6), and a decrease bilaterally in the
635 temporal lobes and precuneus (GM) (Fig. 5B) corresponding to a level of
636 concordance classed as [D].
637

The algorithmic EEG–fMRI data analysis (GLM2) showed a BOLD sig-
638 nal increase in the left precentral cortex (BA6) (GM) and widespread
639 BOLD decreases over bilateral temporal lobes and precuneus associated
640 with high amplitude diffuse left events (C1) (Fig. 5D). The events
641

Visual IED classification based fMRI analysis



Wave_Clus IED classification based fMRI analysis

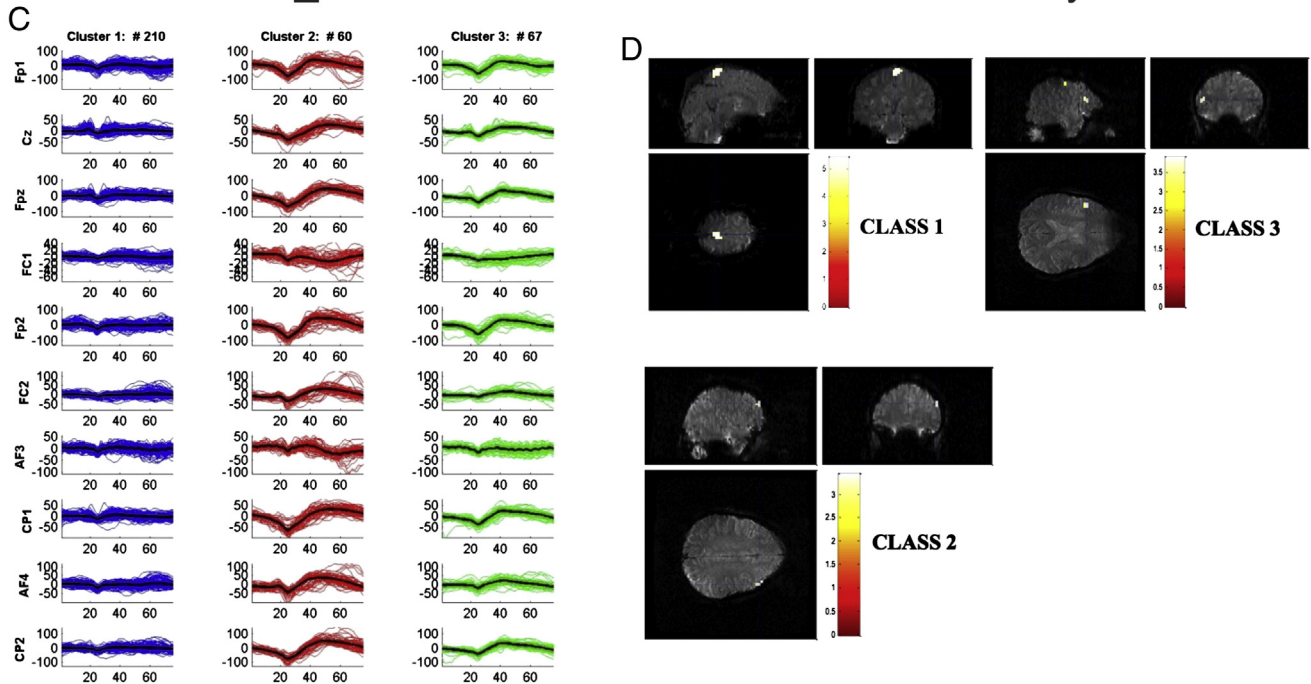


Fig. 6. Visual and algorithmic classification for the IED of case #8. The top of the figure (Panel A) presents results for the visual classification. EEG recorded during scanning after scanning artefact subtraction. The EEG trace was analysed following pulse (marked by R) and image artefact subtraction; the EEG trace is displayed as bipolar montage (32 channels). Note the presence of different types of IED marked: Midline spikes (IED1) in blue, Right fronto-central spikes (IED2) in grey and right frontal spikes in red (IED3). Panel B: EEG–fMRI data analysis results based on visual-IED labelling (T contrast, $p < 0.001$ uncorrected, crosshairs at the global maxima). A right middle frontal gyrus (BA9) activation (GM) corresponded to the IED1. IED2 led to a BOLD signal increase over the right medial frontal gyrus (BA6) (GM), while no hemodynamic changes were found related with the IED3 (Fig. 6B). Panel C: IED classification as result of the algorithm labelling: 3 IED classes were detected (see text for details). Panel D: EEG–fMRI data analysis results based on algorithmic labelling: Class1 identified a BOLD increase area on the right medial frontal gyrus (BA6) (GM), Class2 on the right middle frontal gyrus (BA9) (GM) to C2 and finally C3 demonstrate a left prefrontal cortex activation blob (BA10) (GM) (Fig. 6D). No deactivation clusters were observed associated to any Class. All fMRI results are overlaid subject's high resolution T1 image. R = right; BA: Brodmann area.

642 marked as medium amplitude left hemisphere IED (C2) were associated with a region of BOLD signal increase covering the pole and posterior
643 parts of the left temporal lobe (GM) classed as [C+] (Fig. 5D). The C1-
644 related map was classed as discordant [D]. The patient refused to under-
645 go icEEG recordings.
646

Case 8 (Fig. 6)

647

Clinical background. Patient affected by right parietal lobe epilepsy 648
symptomatic of right parietal FCD. Interictal EEG showed right parietal 649
and right central IEDs. Ictal EEG demonstrated a continuous pattern of 650

651 right fronto-central spikes. Seizures' semiology revealed a sensitive aura
652 (left leg paraesthesia) followed by left foot clonus which might continue
653 for many hours and shown correlation with the spikes revealed by scalp
654 EEG. A diffusion of the clonic jerks to the left leg and superior arm has
655 been documented. An interictal PET scan demonstrated a moderate
656 hypo-metabolism at the right fronto-polar and orbito-ventral cortex
657 while an ictal SPECT seem to reveal an hypo-perfusion at the right
658 temporal pole. The available non-invasive investigations, although
659 suggested a SOZ in the right fronto-central cortex and the patient
660 underwent icEEG recordings, showing a right pericentral cortex SOZ
661 and the patient underwent resective surgery; The outcome at 5 months
662 is ILAE Class1.

663 *IED classification.* Visual IED labelled three types of IED as midline central
664 (IED1-N = 206), right fronto-central (IED2-N = 121) and right frontal
665 spikes (IED3-N = 10) (Fig. 6A). The algorithmic solution identified
666 three classes, one corresponded to low amplitude bilateral fronto-
667 centro-parietal events [C1-N = 210], one to high amplitude bilateral
668 fronto-centro-parietal IED [C2-N = 60] and finally one to low amplitude
669 bilateral (>right) frontal spikes [C3-N = 67].

670 *EEG-fMRI results.* The visual EEG-fMRI data analysis for IED1 revealed a
671 right middle frontal gyrus (BA9) activation (GM), classed as [D]. IED2
672 were associated with a region of BOLD signal over the right medial frontal
673 gyrus (BA6) (GM) classed as [C]; for IED3 the result was [N] (Fig. 6B).
674 The automatic approach identified an area of BOLD increase in the
675 right medial frontal gyrus (BA6) (GM) associated with C1, in the right
676 middle frontal gyrus (BA9) (GM) for C2 and C3 was associated with a
677 left prefrontal cortex activation blob (BA10) (GM) (Fig. 6D). The level
678 of concordance was [C] for C1 and [D] for C2 and C3.

679 This case represents an example where the two solutions (visual and
680 algorithm IED classification approaches) provided similar results in
681 term of fMRI mapping of the presumed IZ and hence demonstrated a
682 good reliability of the *Wave_clus* method.

683 Discussion

684 We have presented here the use of an automated spike sorting algo-
685 rithm (*Wave_clus*) for the classification of IED events recorded during
686 simultaneous EEG-fMRI and evaluated it using a double-blind process.
687 Our approach integrates tools of signal processing and statistics into
688 the IED classification process. Data were collected from 8 patients
689 with refractory partial epilepsy within a pre-surgical evaluation proto-
690 col. This allowed us to compare the results of IED classification with
691 purely visual marking by an expert observer, and to use a second set
692 of observations, namely BOLD changes correlated with the IED classes,
693 to assess the localization of brain regions associated with the electro-
694 physiological activity, providing an evaluation of the solution proposed.

695 The main findings of this study are: (1) the approach based on spike
696 sorting of the signals provided a nearly fully-automated, and hence
697 potentially more objective classification, of interictal events visually
698 identified previous to the application of the algorithm. The results
699 obtained were generally in good agreement with expert classification,
700 being able to identify IED classes related to fMRI maps concordant
701 with the presumed IZ in 87% of the cases studied. This observation rep-
702 resents a promising outcome of the proposed method and its potential
703 clinical applications especially in long-term EEG monitoring or icEEG
704 recordings when used in conjunction with an automatic IED event de-
705 tector (LeVan and Gotman, 2008); (2) the classification algorithm-
706 based fMRI analysis demonstrated BOLD signal changes related to the
707 majority of IED classes that provided an improved performance com-
708 pared to the visual IED classification-based GLM (72% versus 50%);
709 (3) the IED-related fMRI maps obtained using the algorithm classi-
710 fication had the global maximum located within the presumed IZ (con-
711 firmed by icEEG in 4 patients) in a greater proportion of cases than those
712 derived from the visually IED classification approach (7 versus 5 of the

713 cases); (4) with respect to the most clinically relevant IED types, the
714 algorithm based fMRI analysis demonstrated concordant results (namely
715 C and C+) in 6 patients (75%) compared to the four cases (hence 50%)
716 when the visual classification was adopted. In summary, the proposed
717 method provides a characterization of the IED events into classes that
718 presented associated BOLD maps more consistent with the available
719 electro-clinical evidence for the studied cases. Hence, the results of our
720 study provided evidence that the algorithm solution might represent a
721 new and powerful way of analysing EEG-fMRI signals, to assess the local-
722 ization of brain regions associated with the electrophysiological activity
723 and its clinical correlates. Furthermore, since the classification of IEDs
724 using *Wave_clus* has proven successful and validated with the fMRI
725 results, it is possible to consider its application for other epileptic record-
726 ings such as long term monitoring of EEG signals (outside the limitations
727 of the fMRI scanner) and intracranial EEG recordings.

Automated classification of IEDs

728
729 The accurate identification of the area responsible for IED generation
730 (i.e. the IZ) is an important element of the management of patients with
731 drug-resistant epilepsy considered for surgery, with improved outcome
732 associated with removal of the IZ in cases with localized IED and concor-
733 dant with the clinical information (Dworetzky and Reinsberger, 2011;
734 Marsh et al., 2010). Additionally, human and animal studies raise the
735 possibility that IEDs contribute to the development of the neuronal
736 circuits that give rise to spontaneous seizures (Staley et al., 2005),
737 although it has also been proposed that they could have a protective
738 effect for the epileptic area (Curtis and Avanzini, 2001). The process of
739 identifying the IZ rests on the accurate detection and classification of
740 IED. In clinical practice, this can be a difficult undertaking particularly
741 for patients with complex and varied abnormal EEG features and for
742 prolonged EEG recordings which can last from a few to many days.
743 For this reason, automatic spike and seizure detection and classification
744 techniques have received intense attention (Yadav et al., 2011).

745 Sorting algorithms, based on the waveform of the recorded signals,
746 have been applied to electrophysiological recordings from microelec-
747 trodes for the identification of neuronal source signals for decades
748 (see Quian Quiroga, 2007 for a review). Recently, they have increased
749 their performance taking advantage of multiple-site recordings and
750 proving their contribution this complex recording scenario (Blanche
751 et al., 2005; Gray et al., 1995). However, up to our knowledge, spike
752 sorting algorithms for extracellular recordings have not previously
753 been used for the classification of EEG-related signals. In here, we
754 have shown that its use is not only possible, but desirable, in the classi-
755 fication of IEDs for the diagnosis of epilepsy.

756 The goal of our study was to provide a method of analysing the EEG
757 signals of any given recording that would maximize the information ex-
758 tracted from the recorded IEDs while, at the same time, diminish the
759 subjectivity of the present IEDs classification methods. In our work we
760 only focused on maximizing the performance on the event classification
761 and did not include an automatic detection as previous studies have
762 done (Hogan, 2011; Hostetler et al., 1992).

763 In this study we assessed the validity of the approach by comparing
764 the automated classification results to those obtained visually. We
765 contrasted both the EEG events themselves and associated fMRI signal
766 changes in a group of 8 patients for whom good, independent IZ local-
767 ization information was available. Our results suggest that the proposed
768 approach offers a valid classification and it is a promising complement
769 to automated detection methodologies. Furthermore, the results obtain-
770 ed provided more classes related to the IZ than the manual classifica-
771 tion. In addition, the use of algorithmic event classification could allow
772 correction of false detections, as it is likely that they will be grouped in
773 separate clusters. These clusters could be visually inspected and all the
774 spurious events, such as eye blinks and head motions, grouped together
775 by the algorithm in a cluster, could be rejected in one action. Others,
776 such as inconsistent EEG events, would not elicit any associated fMRI

777 signal. Hence, the solution proposed showed a marked improvement
778 compared to the visual solution reached by the individual classification
779 of events from the user, despite the user's supervision of the proposed
780 outcome before the final solution.

781 *IED classification and localization*

782 Our general approach to IED identification and classification for the
783 purpose of fMRI modelling is based on the principle of building a com-
784 plete and specific predictor of the fMRI signal changes. The predictor
785 is built under a compromise to optimise sensitivity and specificity of
786 the epilepsy-related BOLD changes while limiting the number of GLM
787 tested to a single one. Hence, we build a single GLM that embodies
788 our best hypothesis about the underlying sources of the fMRI signal vari-
789 ations and how they are reflected on EEG (Salek-Haddadi et al., 2006).
790 Therefore, we tend to include as an effect of interest any event that may
791 be associated with fMRI signal change, and try to separate effects that
792 may be associated with different BOLD regions or networks.

793 The total number of IED classes across the group was similar: 26 for
794 the visual classification compared to 29 for the algorithmic one. The two
795 approaches demonstrated similar degrees of correspondence between
796 the IED localization and the presumed or confirmed IZ (see the Supple-
797 mentary Material for details) with 87% of IED classes concordant with
798 the presumed or confirmed IZ. The most relevant question for our
799 results would be: "Does the algorithmic result give more localizing
800 information on the IZ than the visual classification?" Answering this
801 question will require further investigation, such as prospective studies
802 in a clinical context. Nonetheless, the fMRI element of our study pro-
803 vides some evidence relevant to the question.

804 In three cases (#1, #2 and #6) of the presented study the results
805 with the automatic classification method reported a higher number of
806 clusters, which in turn, led to fMRI maps more concordant to the clinical
807 evidence than the ones reported for visual classification (see the results
808 section and Table 3 for details).

809 In two further cases (#4 and #5) the labelling obtained for both
810 methods differed in the type of classes obtained. While the expert
811 reported classes based in morphology, the algorithmic method obtained
812 more IED localization based classes. Nonetheless, the fMRI maps related
813 to both approaches in these two cases were in broad agreement and
814 concordant with the IZ. These results pose an interesting question
815 about the possibility of overclustering risks in visual classification (espe-
816 cially in case #5, in which the merging of visual classes led to activation
817 maps in the fMRI signal), as we would expect correctly classified IED
818 to be associated with greater BOLD sensitivity (Flanagan et al., 2009).
819 Interestingly, even in a case in which the number of clusters was
820 lower for the automatic classification (#3), covering only partially the
821 topographic distribution of the visually-labelled IED (see Supplementary
822 Material), both approaches revealed clinically-relevant IED and the
823 related BOLD maps included almost the same clusters, although the
824 location of the global maxima (and hence the level of concordance)
825 was different.

826 Regarding the clinical significance of the IED classification, in the
827 Supplementary Material we have distinguished between potentially
828 meaningful IED types from others. Although this distinction can be
829 seen as arbitrary, especially in those cases without icEEG recordings,
830 we believe that it is relevant for the interpretation of the results obtain-
831 ed with the proposed solution and its clinical utility. The results obtain-
832 ed for both approaches also differed for the non-congruent classes.
833 According to the preponderant clinical hypotheses, visual classification
834 revealed 8 IED classes (38%) that were judged incongruent across the
835 entire group of patients compared to 16 (55%) for the algorithmic solu-
836 tion. However, the fMRI maps associated to the two types of analysis
837 were different. While all visually classified incongruent IEDs resulted
838 in BOLD activity maps classified as discordant or NULL (except for
839 patient #7 and for the type IED1 of patient #1), the algorithmic classifi-
840 cation presented a mixed type of BOLD maps for incongruent IEDs. In

the later case, the total number of classes accounting for discordant or
NULL classification was only of 10 of the 16 classes while the other 6
presented some relationship with the epileptogenic network. This
may indicate that the automated classifier could be providing some ad-
ditional information. In order to assess this, more analysis would be
needed to study the clinical relevance of this type of activations.

Algorithmic sensitivity and specificity

fMRI mapping failed to reveal significant hemodynamic changes in
relation to 50% of IED-types for the visual classification compared to
28% for the algorithmic clustering. The relatively high proportion of
NULL results, especially regarding the visual IED classification related
fMRI analyses, is in line with previously reported observations. Different
papers indeed reported a variable percentage between 30% and 70%
of EEG–fMRI recordings in patients with focal epilepsy, that did not re-
vealed any significant spike-related BOLD changes despite the presence
of recorded events (Aghakhani et al., 2006; Grouiller et al., 2011;
Salek-Haddadi et al., 2006; Storti et al., 2013). Within the group of
IEDs with fMRI hemodynamic changes, the proportion of IED types
with discordant fMRI maps was 27% and 38% for visual and algorithmic
labelling, respectively. However, in the majority of patients the
algorithmic-derived BOLD maps were more localizing the IZ (C and
C + results) than the visual classification-derived ones. Improved
concordance was observed in the patients for whom algorithmic
labelling provided additional IED classes (cases #1, #2 and #6). It is
notable that concordant fMRI maps were associated with clinically
meaningful IED, suggesting that algorithmic solutions can provide
more clinically relevant localizing information, improving sensitivity
of EEG–fMRI co-registration in severe partial epilepsies.

Given the small population sample, it is difficult to assess specificity
of algorithmic approach rigorously. In our centre and in many others,
the icEEG is considered the gold standard to localize the IZ (Luders
and Schuele, 2006; Rosenow and Luders, 2001) and when not available
localization provided by non-invasive means is acceptable. It is impor-
tant to keep in mind that the EEG–fMRI studies reveal often a network
characterized by several clusters of BOLD changes so that the technique
is not expected to specifically pinpoint the source of epileptic activity.
Nevertheless, in the majority of our patients (7/8), the localization of
the statistical maximum provided by the automatic IED classification
was specifically concordant with the presumed target area.

Taken together, our findings suggest that the analysis of IEDs using
automatic methods provides a high level of concordance between the
associated fMRI clusters and the IZ of focal epilepsy, providing more
significant clusters associated with the epileptic regions. In addition,
the method, being almost fully automatic might offer a more objective
evaluation of the recorded events.

Methodological considerations and future work

We used a less stringent statistical significance threshold than the
conventional value used in most cognitive fMRI studies ($p < 0.001$ with-
out correction for multiple comparisons). However, there are several
evidences that have shown and evaluated the clinical value of uncor-
rected results, including findings within the pre-surgical assessment of
drug-resistant epileptic patients. Indeed, a good concordance was
detected between IED related BOLD changes ($p < 0.001$ uncorrected)
with the IZ as defined by the intracranial recordings (Grouiller et al.,
2011) and by the postsurgical outcome (Thornton et al., 2010). In a
recent paper (Zijlmans et al., 2007), the uncorrected pre-surgical IED-
related fMRI maps revealed BOLD clusters concordant with the epilep-
togenic zone in patients with drug-resistant epilepsies previously ex-
cluded from surgery for presumed multifocality. In our study the use
of a less conservative threshold can be partly justified by the desire to
extract as much information as possible from each dataset (given its
potential clinical relevance for the individual patient's management),

our use of extensive confound effect modelling strategies (Chaudhary et al., 2012; Liston et al., 2006; Salek-Haddadi et al., 2006; Thornton et al., 2010, 2011; Vulliemoz et al., 2011), and the usual existence of a prior localization hypothesis (Carney et al., 2012; Thornton et al., 2011). Furthermore, the application of an additional five voxels threshold was applied in order to discard BOLD changes occurring in scattered voxels. The results shown here are encouraging enough to warrant the application of the automated classification technique in a larger group of patients, and for the analysis of icEEG–fMRI data, which has abundance of IED (Carmichael et al., 2012; Vulliemoz et al., 2011).

In our study, we selected patients with very frequent IED to satisfy a requirement of the algorithm. Such datasets represent the greatest challenge for visual IED classification being laborious and time-consuming. Given the success of this study, the application of the proposed solution to interictal activity recorded intra-cranially might be fruitful (Yadav et al., 2011). Our findings support the idea that spike sorting algorithms adapted for multiple-site recordings, such as *Wave_chus*, could be the basis of a completely automatic solution for the classification of IED in long term and/or intracranial EEG recordings by combining it with an automatic detection algorithm (see Hostetler et al., 1992; Webber et al., 1993 for examples).

Conclusions

In this study we have presented the analysis of 8 cases of epileptic patients in which we have increased the clinically-relevant information extracted from their EEG–fMRI co-registration. We have demonstrated the successful application of an automated spike sorting algorithm in the classification of IEDs on scalp EEG recorded during fMRI. The results obtained showed that, by using this approach, we could detect a higher number of IED classes associated with BOLD changes, corresponding to an increase in EEG–fMRI sensitivity, which could not be explained by the mere increase in the number of total classes. In addition, the results show that the combination of algorithmic classification of IEDs with automatic event detection could form a clinically useful tool in the pre-surgical assessment of patients with severe epilepsy.

Supplementary data to this article can be found online at <http://dx.doi.org/10.1016/j.neuroimage.2014.05.009>.

Uncited references

- 940 Alarcon et al., 1997
- 941 Rémi et al., 2011
- 942 Zhang et al., 2012

References

- 944 Aghakhani, Y., Kobayashi, E., Bagshaw, A.P., Hawco, C., Benar, C.G., Dubeau, F., et al., 2006. Cortical and thalamic fMRI responses in partial epilepsy with focal and bilateral synchronous spikes. *Clin. Neurophysiol.* 117, 177–191.
- 947 Alarcon, G., Garcia Seoane, J.J., Binnie, C.D., Martin Miguel, M.C., Juler, J., Polkey, C.E., Elwes, R.D., et al., 1997. Origin and propagation of interictal discharges in the acute electrocorticogram. Implications for pathophysiology and surgical treatment of temporal lobe epilepsy. *Brain* 120, 2259–2282.
- 951 Al-Asmi, A., Bènar, C.G., Gross, D.W., Khani, Y.A., Andermann, F., Pike, B., et al., 2003. fMRI activation in continuous and spike-triggered EEG–fMRI studies of epileptic spikes. *Epilepsia* 44, 1328–1339.
- 954 Allen, P.J., Polizzi, G., Krakow, K., Fish, D.R., Lemieux, L., 1998. Identification of EEG events in the MR scanner: the problem of pulse artifact and a method for its subtraction. *Neuroimage* 8, 229–239.
- 957 Allen, P.J., Josephs, O., Turner, R., 2000. A method for removing imaging artifact from continuous EEG recorded during functional MRI. *Neuroimage* 12, 230–239.
- 959 Blanche, T.J., Spacek, M.A., Hetke, J.F., Swindale, N.V., 2005. Polytrodes: high-density silicon electrode arrays for large-scale multiunit recording. *J. Neurophysiol.* 93, 2987–3000.
- 962 Carmichael, D.W., Vulliemoz, S., Rodionov, R., Thornton, J.S., McEvoy, A.W., Lemieux, L., 2012. Simultaneous intracranial EEG–fMRI in humans: protocol considerations and data quality. *Neuroimage* 63, 301–309.
- 964 Carney, P.W., Masterton, R.A., Flanagan, D., Berkovic, S.F., Jackson, G.D., 2012. The frontal lobe in absence epilepsy: EEG–fMRI findings. *Neurology* 78, 1157–1165.

- Chaudhary, U.J., Carmichael, D.W., Rodionov, R., Thornton, R.C., Bartlett, P., Vulliemoz, S., et al., 2012. Mapping preictal and ictal hemodynamic networks using video-electroencephalography and functional imaging. *Brain* 135, 3645–3663.
- 969 Curtis, M., Avanzini, G., 2001. Interictal spikes in focal epileptogenesis. *Prog. Neurobiol.* 63, 541–567.
- 972 Dwozetzky, B.A., Reinsberger, C., 2011. The role of the interictal EEG in selecting candidates for resective epilepsy surgery. *Epilepsy Behav.* 20, 167–171.
- 973 Ebersole, J.S., 1997. Defining epileptogenic foci: past, present, future. *J. Clin. Neurophysiol.* 14, 470.
- 975 Emerson, R.G., Pedley, T.A., 2000. Electroencephalography and evoked potentials. *Neurol. Clin. Pract.* 1, 473–485.
- 977 Flanagan, D., Abbott, D.F., Jackson, G.D., 2009. How wrong can we be? The effect of inaccurate mark-up of EEG–fMRI studies in epilepsy. *Clin. Neurophysiol.* 120 (9), 1637–1647.
- 980 Friston, K.J., Williams, S., Howard, R., Frackowiak, R.S., Turner, R., 1996. Movement-related effects in fMRI time-series. *Magn. Reson. Med.* 35, 346–355.
- 982 Gray, C.M., Malonado, P.E., Wisoln, M., McNaughton, B., 1995. Tetrodes markedly improve the reliability and yield of multiple single-unit isolation from multi-unit recordings in cat striate cortex. *J. Neurosci. Methods* 63, 43–54.
- 983 Grouiller, F., Thornton, R.C., Groening, K., Spinelli, L., Duncan, J.S., Schaller, K., et al., 2011. With or without spikes: localization of focal epileptic activity by simultaneous electroencephalography and functional magnetic resonance imaging. *Brain* 134, 2867–2886.
- 987 Hamer, H.M., Morris, H.H., Mascha, E.J., Karafa, M.T., Bingaman, W.E., Bej, M.D., et al., 2002. Complications of invasive video-EEG monitoring with subdural grid electrodes. *Neurology* 58, 97–103.
- 990 Hogan, R.E., 2011. Automated EEG, detection algorithms and clinical semiology in epilepsy: importance of correlations. *Epilepsy Behav.* 22 (Suppl. 1), S4–S6 (Disc).
- 992 Hostetler, W.E., Doller, H.J., Homan, R.W., 1992. Assessment of a computer program to detect epileptiform spikes. *Electroencephalogr. Clin. Neurophysiol.* 83 (1), 1–11.
- 996 Lemieux, L., Salek-Haddadi, A., Lund, T.E., Laufs, H., Carmichael, D., 2007. Modelling large motion events in fMRI studies of patients with epilepsy. *Magn. Reson. Imaging* 25, 894–901.
- 999 LeVan, P., Gotman, J., 2008. Automatic detection of epileptic spikes. In: Lüders, H.O., Bongaman, W., Najm, I.M. (Eds.), *Textbook of Epilepsy Surgery*. Taylor & Francis, Abingdon, UK. **Q6**
- 1001 Liston, A.D., Lund, T.E., Salek-Haddadi, A., Hamandi, K., Friston, K.J., Lemieux, L., 2006. Modelling cardiac signal as a confound in EEG–fMRI and its application in focal epilepsy studies. *Neuroimage* 30, 827–834.
- 1004 Lüders, H., 1993. General principles. *Surgical Treatment of the Epilepsies* pp. 137–153.
- 1006 Lüders, H., Schuele, S.U., 2006. Epilepsy surgery in patients with malformations of cortical development. *Curr. Opin. Neurol.* 19 (2), 169–174.
- 1008 Marsh, E.D., Peltzer, B., Brown III, M.W., Wusthoff, C., Storm Jr., P.B., Litt, B., et al., 2010. Interictal EEG spikes identify the region of electrographic seizure onset in some, but not all, pediatric epilepsy patients. *Epilepsia* 51, 592–601.
- 1011 Mégevand, P., Spinelli, L., Genetti, M., Brodbeck, V., Momjian, S., Schaller, K., et al., 2013. Electric source imaging of interictal activity accurately localises the seizure onset zone. *JNNP* 30, 1–6.
- 1014 Pittau, F., Dubeau, F., Gotman, J., 2012. Contribution of EEG–fMRI to the definition of the epileptic focus. *Neurology* 78, 1479–1487.
- 1015 Quian Quiroga, R., 2007. Spike sorting. *Scholarpedia* 2, 3583.
- 1017 Quian Quiroga, R., Nadasy, Z., Ben-Shaul, Y., 2004. Unsupervised spike detection and sorting with wavelets and super-paramagnetic clustering. *Neural Comput.* 16, 1661–1687 (5).
- 1020 Ramabhadran, B., Frost Jr., J.D., Glover, J.R., Ktonas, P.Y., 1999. An automated system for epileptogenic focus localization in the electroencephalogram. *J. Clin. Neurophysiol.* 16 (1), 59–68.
- 1022 Rémi, J., Vollmar, C., de Marinis, A., Heinlin, J., Peraud, A., Noachtar, S., 2011. Congruence and discrepancy of interictal and ictal EEG with MRI lesions in focal epilepsies. *Neurology* 77, 1383–1390.
- 1026 Rosenow, F., Lüders, H., 2001. Presurgical evaluation of epilepsy. *Brain* 124, 1683–1700.
- 1027 Salek-Haddadi, A., Diehl, B., Hamandi, K., Merschhemke, M., Liston, A., Friston, K., Duncan, J.S., Fish, D.R., Lemieux, L., 2006. Hemodynamic correlates of epileptiform discharges: an EEG–fMRI study of 63 patients with focal epilepsy. *Brain Res.* 1088, 148–166.
- 1031 Scherg, M., Ille, N., Weckesser, D., Ebert, A., Ostendorf, A., Boppel, T., Schubert, S., et al., 2012. Fast evaluation of interictal spikes in long-term EEG by hyper-clustering. *Epilepsia* 53 (7), 1196–1204.
- 1034 Siniatchkin, M., Moeller, F., Jacobs, J., Stephani, U., Boor, R., Wolff, S., et al., 2007. Spatial filters and automated spike detection based on brain topographies improve sensitivity of EEG–fMRI studies in focal epilepsy. *Neuroimage* 37 (3), 834–843.
- 1038 Staley, K., Hellier, J.L., Dudek, F.E., 2005. Do interictal spikes drive epileptogenesis? *Neuroscientist* 11 (4), 272–276.
- 1040 Staley, K.J., White, A., Dudek, F.E., 2011. Interictal spikes: harbingers or causes of epilepsy? *Neurosci. Lett.* 27, 247–250.
- 1042 Storti, S.F., Formaggio, E., Bertoldo, A., Manganotti, P., Fiaschi, A., Toffolo, G.M., 2013. Modelling hemodynamic response function in epilepsy. *Clin. Neurophysiol.* 124, 2108–2118.
- 1044 Thornton, R., Laufs, H., Rodionov, R., Cannadathu, S., Carmichael, D.W., Vulliemoz, S., et al., 2010. EEG correlated functional MRI and postoperative outcome in focal epilepsy. *J. Neurol. Neurosurg. Psychiatry* 81 (8), 922–927.
- 1048 Thornton, R., Vulliemoz, S., Rodionov, R., Carmichael, D.W., Chaudhary, U.J., Diehl, B., 2011. Epileptic networks in focal cortical dysplasia revealed using electroencephalography-functional magnetic resonance imaging. *Ann. Neurol.* 70 (5), 822–837.
- 1050
- 1051
- 1052

- 1053 Vulliemoz, S., Carmichael, D.W., Rosenkranz, K., Diehl, B., Rodionov, R., Walker, M.C., et al.,
1054 2011. Simultaneous intracranial EEG and fMRI of interictal epileptic discharges in
1055 humans. *Neuroimage* 54, 182–190.
- 1056 Webber, W.R., Litt, B., Lesser, R.P., Fischer, R.S., Bankman, I., 1993. Automatic EEG spike
1057 detection: what should the computer imitate? *Electroencephalogr. Clin. Neurophysiol.*
1058 87 (6), 364–367.
- 1059 White, A., Williams, P.A., Helliier, J.L., Clark, S., Edward, D.F., Staley, K.J., 2010. EEG spike activity
1060 precedes epilepsy after kainate-induced status epilepticus. *Epilepsia* 51 (3), 371–383.
- Yadav, R., Shah, A.K., Loeb, J.A., Swamy, M.N., Agarwal, R., 2011. A novel unsupervised 1061
spike sorting algorithm for intracranial EEG. *Conf. Proc. IEEE Eng. Med. Biol. Soc.* 1062
2011, 7545–7548. 1063
- Zhang, J., Liu, W., Chen, H., Xia, H., Zhou, Z., Wang, L., et al., 2012. EEG–fMRI validation 1064
studies in comparison with icEEG: a review. *Int. J. Psychophysiol.* 84, 233–239. 1065
- Zijlmans, M., Huiskamp, G., Hersevoort, M., Seppenwoolde, J.H., van Huffelen, A.C., Leijten,
F.S., 2007. EEG–fMRI in the preoperative work-up for epilepsy surgery. *Brain* 130, 1067
2343–2353. 1068

UNCORRECTED PROOF