This is the peer reviewd version of the followng article:

Real-world approach to actinic keratosis management: practical treatment algorithm for office-based dermatology / Dirschka, T., Gupta, G., Micali, G., Stockfleth, E., Basset-Séguin, N., Del Marmol, V., Dummer, R., Jemec, G.B.E., Malvehy, J., Peris, K., Puig, S., Stratigos, A.J., Zalaudek, I., Pellacani, G.. - In: THE JOURNAL OF DERMATOLOGICAL TREATMENT. - ISSN 0954-6634. - 28:5(2017), pp. 431-442. [10.1080/09546634.2016.1254328]

Terms of use:

The terms and conditions for the reuse of this version of the manuscript are specified in the publishing policy. For all terms of use and more information see the publisher's website.

26/11/2026 07:49

(Article begins on next page)

Journal of Dermatological Treatment

ISSN: 0954-6634 (Print) 1471-1753 (Online) Journal homepage: http://www.tandfonline.com/loi/ijdt20

Real-world approach to actinic keratosis management: Practical treatment algorithm for office-based dermatology

Thomas Dirschka, Girish Gupta, Giuseppe Micali, Eggert Stockfleth, Nicole Basset-Séguin, Véronique Del Marmol, Reinhard Dummer, Gregor B. E. Jemec, Josep Malvehy, Ketty Peris, Susana Puig, Alexander J. Stratigos, Iris Zalaudek & Giovanni Pellacani

To cite this article: Thomas Dirschka, Girish Gupta, Giuseppe Micali, Eggert Stockfleth, Nicole Basset-Séguin, Véronique Del Marmol, Reinhard Dummer, Gregor B. E. Jemec, Josep Malvehy, Ketty Peris, Susana Puig, Alexander J. Stratigos, Iris Zalaudek & Giovanni Pellacani (2016): Real-world approach to actinic keratosis management: Practical treatment algorithm for office-based dermatology, Journal of Dermatological Treatment, DOI: 10.1080/09546634.2016.1254328

To link to this article: http://dx.doi.org/10.1080/09546634.2016.1254328

Accepted author version posted online: 31 Oct 2016.

Submit your article to this journal

View related articles

View Crossmark data

Full Terms & Conditions of access and use can be found at http://www.tandfonline.com/action/journalInformation?journalCode=ijdt20

Download by: [137.189.171.235] **Date:** 01 November 2016, At: 15:59

Real-world approach to actinic keratosis management: Practical treatment algorithm for office-based dermatology

Thomas Dirschka[1], Girish Gupta[2], Giuseppe Micali[3], Eggert Stockfleth[4], Nicole Basset-Séguin[5], Véronique Del Marmol[6], Reinhard Dummer[7], Gregor B. E. Jemec[8], Josep Malvehy[9,10],Ketty Peris[11], Susana Puig[9,10], Alexander J. Stratigos[12], Iris Zalaudek[13], Giovanni Pellacani[14]

[1]Centroderm Clinic, Wuppertal, and Faculty of Health, University Witten-Herdecke, Witten, Germany

[2]Department of Dermatology, Monklands Hospital, Lanarkshire, and University of Glasgow, UK

[3]Dermatology Clinic, University of Catania, Italy

[4]Klinik für Dermatologie, Venerologie und Allergologie, St. Josef-Hospital, Ruhr-Universität Bochum, Bochum, Germany

[5]Policlinique de Dermatologie, Hôpital Saint-Louis, Paris, France

[6]Department Dermatology – Hôpital Erasme – Université Libre de Bruxelles, Bruxelles, Belgium

[7]Department of Dermatology Skin Cancer Unit, University Hospital Zürich, Switzerland

[8]Department of Dermatology, Zealand University Hospital, Roskilde; Health Sciences Faculty, University of Copenhagen, Denmark

[9]Dermatology Department, Melanoma Unit, Hospital Clínic de Barcelona, IDIBAPS, Universitat de Barcelona, Barcelona, Spain

[10]Centro de Investigación Biomédica en Red en Enfermedades Raras (CIBERER), Valencia, Spain

JUST ACCEPTED

[11]Department of Dermatology, Catholic University of Rome, Largo A. Gemelli 8, Rome, Italy

[12]First Department of Dermatology-Venereology, University of Athens Medical School, Andreas Sygros Hospital, Athens, Greece

[13]Non-Melanoma Skin Cancer Unit, Department of Dermatology and Venereology, Medical University of Graz, Austria

[14]Department of Dermatology, University of Modena and Reggio Emilia, Italy

Running head: AK practical algorithm

Key words: diclofenac, field cancerisation, 5-fluorouracil, imiquimod, ingenol mebutate, photodynamic therapy

Word count: 4687

Number of tables: 2

Number of figures: 5

Number of references: 101

Corresponding author: T. Dirschka

Address: CentroDerm GmbH, Heinz-Fangman-Straße 57, D-42287 Wuppertal, Germany

Phone: +49 (0) 202 555656

Fax: +49 (0) 202 2547822

Email: t.dirschka@centroderm.de

JUST ACCEPTED

Abstract

Actinic keratosis (AK) is a chronic skin disease in which multiple clinical and subclinical lesions co-exist across large areas of sun-exposed skin, resulting in field cancerisation. Lesions require treatment because of their potential to transform into invasive squamous cell carcinoma. This article aims to provide office-based dermatologists and general practitioners with simple guidance on AK treatment in daily clinical practice to supplement existing evidence-based guidelines. Novel aspects of the proposed treatment algorithm include differentiating patients according to whether they have isolated scattered lesions, lesions clustered in small areas or large affected fields without reference to specific absolute numbers of lesions. Recognising that complete lesion clearance is rarely achieved in real-life practice and that AK is a chronic disease, the suggested treatment goals are to reduce the number of lesions, to achieve long-term disease control and to prevent disease progression to invasive squamous cell carcinoma. In the clinical setting, physicians should select AK treatments based on local availability, and the presentation and needs of their patients. The proposed AK treatment algorithm is easy-to-use and has high practical relevance for real-life, office-based dermatology.

JUST ACCEPTED

Introduction

Actinic keratosis (AK) is a chronic skin lesion, which principally arises due to long-term sun-exposure (1-3). As ultraviolet radiation affects the entire sun-exposed area of skin, clinically visible AK lesions are surrounded by subclinical or invisible lesions resulting in field cancerisation (Figure 1) (4,5). AK lesions can be considered as early *in situ* squamous cell carcinoma (SCC) and part of a disease continuum that can progress into invasive SCC (1-3). Furthermore, subclinical and early AK lesions may also be associated with invasive SCC, suggesting that these lesions may also directly transform into invasive disease (6). Estimates from clinical studies indicate that 0.025–16% of AK lesions may progress to invasive SCC per year (7), although there are currently no established biomarkers to predict which subclinical or clinical lesions will progress and when this progression will occur. However, based on clinical experience, it is evident that there is an association between AK lesions and invasive SCC, which is stronger with a greater number of AK lesions, suggesting a risk of transformation (8). Consequently, guidelines recommend that all AKs need to be adequately treated (9).

The prevalence of AK and the clinical and economic burden of the disease are expected to rise substantially over the coming decades (10,11). This is because AK mainly affects elderly people who have had chronic lifetime sun exposure [with an estimated prevalence of 34% of men and 18% of women in Europe aged over 70 years (12)], and due to the increasingly ageing global population. The prevalence of the disease varies widely between different countries with the highest prevalence seen in Australia (40–60% of adults) (13). In some countries, AK is considered to be an occupational disease for those who work outside (14). Other risk factors for the

JUST ACCEPTED

development of AK include male gender, fair skin type and immunosuppression (15-17).

The recently published global S3 guidelines from the International League of Dermatological Societies (ILDS) and European Dermatology Forum (EDF) provide evidence-based recommendations for the treatment of AK (9). Published data from randomised clinical trials (RCTs) are considered to be the 'gold-standard' evidence to support treatment recommendations. However, these RCTs typically include a highly selected homogeneous population of patients due to their strict eligibility criteria and may not be representative of the broader range of AK patients seen by dermatologists in real-life clinical practice.

In addition to evidence-based guidelines, there is a need to provide dermatologists with simple, practical, easy-to-use guidance on the treatment of AK in daily clinical practice. Recognising this need, the aim of this article is to provide a real-world practical approach to the office-based management of AK patients by dermatologists and general practitioners (GPs), including guidance on diagnosis, patient classification and treatment. The focus of the article is for office-based dermatology given that most AK patients are treated in an outpatient setting. In such a setting, the availability of devices to perform procedures such as standard photodynamic therapy (PDT) is limited, so the main emphasis is on topical AK treatments which can be self-applied by the patient. The aim is not to replace current treatment guidelines, but to provide complementary practical advice on the treatment of AK in daily clinical practice.

JUST ACCEPTED

Methods

An international panel of fourteen experts in AK was convened to develop a real-world practical approach to AK management. The practical guidance was developed based on a review of published international and national guidelines on AK, together with an evaluation of relevant literature published up to June 2016. In situations where insufficient published information was available and where published information was not considered to be relevant to real-life practice, recommendations were developed based on consensus of the author's practical clinical experience.

AK diagnosis

AK is easy to diagnose and commonly seen by office-based dermatologists (18). However, the disease is often underestimated by patients who typically are not aware of the potential risk of malignant transformation (10,19). Consequently, AK is frequently diagnosed when patients present for other skin diseases. In elderly patients with clear evidence of photodamaged skin, physicians should check for the presence of AK in sun-exposed areas, irrespective of the reason for the consultation.

The majority of AKs are diagnosed based on clinical examination and a history of risk factors. AK lesions present as rough scaly patches, plaques or papules on an erythematous base in an area, which shows signs of chronic sun damage. The lesions are usually <1 cm in size and have a sandpaper-like texture on palpation (1,9).

AK lesions may be clinically graded on the basis of their thickness using the Olsen classification system (20). Grade 1 lesions are slightly palpable, grade 2 lesions are moderately thick, and grade 3 lesions are very thick and hyperkeratotic (Figure 2) (20). This grading was proposed to provide a better characterisation of

JUST ACCEPTED

disease and to distinguish different morphological subtypes. However, a recent study showed that the clinical classification of lesions using this system does not reliably provide information on the underlying histology of the lesions, with only approximately 50% of lesions having matching clinical and histological classifications (21). Therefore, the Olsen classification cannot be used as a surrogate marker of histopathology. Moreover, the two types of classification systems provide different information on AK lesions. For example, lesions clinically classified as grade 3 are hyperkeratotic, whereas those classified histologically as grade III are *in situ* SCC (20,22).

Dermoscopy improves the clinical diagnosis of AK and has been reported to reach a 98.7% and 95.0% diagnostic sensitivity and specificity, respectively (23). Depending on the clinical aspects, dermoscopy reveals either a red network pattern (grade 1), a “strawberry pattern” (grade 2), or structureless white to yellow areas (grade 3) (Figure 2) (23,24). Moreover, dermoscopy can aid in the assessment of treatment response (Figure 3) and in the differential diagnosis of AK versus other benign non-melanocytic lesions such as solar lentigo or seborrheic keratosis. In the case of pigmented AK, dermoscopy may help to rule out lentigo maligna (24). Dermoscopy can also help to identify early signs of invasive SCC due to the presence of vessels or white circles, which are rarely observed in AK (25).

A skin biopsy should be taken to rule out differential diagnoses and if one or more of the following clinical features are present which may indicate invasive SCC or other types of skin cancer: infiltration, induration, ulceration, pigmentation, rapid enlargement and pain (9). A biopsy should be considered if coiled/dotted, hairpin or polymorphous vessels and/or white circles or whitish homogeneous areas are detected with dermoscopy (25). Biopsies are also required in patients where clinical

JUST ACCEPTED

clearance cannot be achieved and a suspicious lesion remains. In the future, novel imaging techniques such as reflectance confocal microscopy and optical coherence tomography may be useful in the diagnosis of AK (5,26,27).

Following diagnosis, the dermatologist or GP should provide patients with a simple explanation about AKs – describing them as sun-damaged skin and a marker for invasive skin cancer and avoiding the term, “precancerous” – so that they understand the possibility of malignant transformation and recognise why their lesions need to be treated. Clinical and dermoscopy photographs of the lesions and treatment area are useful to allow the clinician to monitor the treatment response and for clinical documentation of the patient. The images can be used to explain the disease to the patient and to clarify where topical treatment needs to be applied. Images can be taken again at every follow-up visit.

Clinical spectrum of AK

AK patients usually present with multiple clinical lesions rather than isolated individual lesions. The latest ILDS/EDF AK guidelines classify patients according to the number of AK lesions per affected field or body region. Patients with single lesions have ≥1 but ≤5 palpable or visible AK lesions, those with multiple lesions have ≥6 distinguishable AK lesions, and those with field cancerisation also have ≥6 distinguishable AK lesions together with contiguous areas of chronic actinic sun damage and hyperkeratosis (9). This classification is used to direct treatment choices.

The authors consider the ILDS/EDF patient classification to have limited supporting evidence for the numerical thresholds of AK lesions which separate the different categories of patients, as previously discussed by Pellacani *et al*. (28).

JUST ACCEPTED

Whilst the number of AK lesions is useful to define patient eligibility criteria for RCTs, it does not provide useful information on the underlying biological characteristics of the disease process, in particular field cancerisation. In addition, absolute lesion numbers do not take into consideration important factors, such as early recurrence after treatment, rapid increase in lesions, immunosuppression or other factors that can influence the risk of developing an invasive SCC.

The authors propose that AK patients should be classified as follows without defining a specific number of AK lesions per patient group: (1) Those with isolated individual lesions scattered on separate body areas; (2) Those with multiple AK lesions clustered into a single small field; and (3) Those with multiple lesions across a large field such as the entire face or scalp (Figure 4).

The authors also consider it to be important to identify patients who are at high risk of progression to invasive SCC or metastatic disease so that they can be monitored more closely. Criteria suggestive of “high-risk” patients are shown in Table 1, although there is currently limited supporting evidence for identifying those most likely to progress to invasive disease.

JUST ACCEPTED

Practical algorithm for AK management

A practical algorithm for the management of AK patients in real-life clinical practice is shown in Figure 5. Following a clinical diagnosis of AK, it is advisable to remove any hyperkeratosis (e.g., with curettage, laser ablation, keratolytic treatment) before initiating treatment. Curettage is preferred because it allows histological confirmation of the diagnosis. Furthermore, the panel recommends taking biopsies and performing histopathology on residual lesions after topical treatment to explore the possibility of malignancy.

Treatment recommendations are provided for patients with isolated scattered lesions, those with small clusters of lesions and those with involvement of large areas. Lesion-directed therapies are those that are suitable for the treatment of single scattered lesions, but which do not treat the surrounding skin. Cluster-directed therapies are those that are suitable for the treatment of small field cancerisation areas (usually ≤25 cm^2) based on their licensed indication. Cluster-directed therapies may also be used to treat larger fields in successive treatment cycles, although this comes at the expense of an increased number of physician visits and longer treatment durations as subsequent cycles can only be started after the initial cycle has been completed and a rest period has been taken. Therapies for large-affected fields are those that are suitable for the treatment of sun-exposed fields >25cm^2. These therapies may also be used for the treatment of clustered lesions in small fields.

AK treatment goals

The goals of AK treatment are to eradicate as many clinical and subclinical AK lesions as possible (i.e., to reduce the extent of field cancerisation), to achieve a time to relapse or disease-free interval that is as prolonged as possible, and to decrease the risk of a patient developing invasive SCC. Secondary aims are to improve the quality of the patient's skin and consequently their quality of life. Since it is not always possible to clear each AK lesion in real-life practice, the main aim of therapy is to reduce the number of lesions and to achieve long-term disease control. AK is a marker for chronic sun damage, another goal of AK treatment is to reduce the risk of other UV-dependent skin cancers.

JUST ACCEPTED

In real-life clinical practice, treatment success should usually be evaluated using the absolute or percentage reduction in AK lesions, rather than by determining whether or not the patient achieves complete clearance. For example, a patient with 20 AK lesions on clinical presentation and one lesion remaining after field-directed treatment may be considered a treatment failure based on the endpoint of complete lesion clearance, even though a 95% reduction in lesions has been achieved. Treatment success parameters should ideally also take into consideration the ability of a therapy to eliminate subclinical lesions, though this depends on these lesions becoming detectable during treatment, or the use of specific imaging techniques for field cancerization (which are not usually available in dermatological offices) (26).

The authors do not specify a particular percentage reduction of lesions, which corresponds to treatment success in daily practice, since this will depend on the number of lesions the patient has on presentation and the individual clinical situation. Instead, the dermatologist/GP should evaluate whether treatment success has been achieved, recognising that complete lesion clearance is rarely attained in real-life practice. Clinical photographs at initial and follow-up visits are recommended to evaluate the treatment response, particularly in patients with multiple lesions.

Patients should be followed-up 3–6 months after completion of treatment to determine the success of the therapy and to exclude early disease relapse. If there is rapidly evolving disease, patients should be treated with a different AK regimen. If treatment success has been achieved, the patient can be followed-up subsequently every 6–12 months.

The goals of AK treatment may need adaptation according to the clinical situation. For example, for lesions which are at a high risk of progressing to invasive

JUST ACCEPTED

SCC such as those on the ear, lip and eyelid (29,30), the goal of treatment should be complete lesion clearance.

Other management recommendations

Dermatologists/GPs should advise all AK patients to protect themselves from sunlight. In particular, patients should regularly use a high sun protection factor (≥50), broad-spectrum sunscreen. Patients should be advised to avoid sun exposure between 11 am and 3 pm, and to protect themselves from sunlight whilst outside by wearing sunglasses, a brimmed hat and loose fitting clothing.

The authors recommend that certain AK patients (e.g., immunocompromised patients; patients with AK around the eyelid or in other sensitive areas) should be referred to specialised centres for treatment. In the case of extensive disease, a blood count to exclude chronic lymphocytic leukaemia or other diseases which lead to immunosuppression is recommended (31), since these patient populations also need special attention.

Comparison of AK treatment options

Treatment considerations

When selecting an AK treatment, the dermatologist/GP has to take into consideration patient-, lesion- and treatment-related factors. Patient-related factors include age (many AK patients are often elderly with age-related health problems and co-morbidities), their ability to perform home-based treatment, their quality of life, and whether they adhere to the regimen (32-34). Lesion-related factors include the number of lesions as well as their location and presentation. Treatment-related factors include treatment duration, application scheme, efficacy, cost, side-effects

JUST ACCEPTED

and prior therapies. Treatment selection also depends on their availability in different practices and countries. Dermatologists/GPs should select AK treatments which they are experienced in using.

Adherence with AK treatments is currently poor with approximately 90% of patients being non-adherent or non-persistent with therapy (35). Dermatologists/GPs need to advise patients about the importance of using their treatment and how to apply it correctly to ensure that adherence is optimised. For example, patients need to understand that field-directed treatment should be applied not only to visible lesions, but also to the entire surrounding sun-exposed area. Dermatologists/GPs should also ensure that patients are aware of any anticipated local skin reactions during treatment. Features of an AK treatment which may optimise patients' adherence are short and simple treatment regimens, ability to self-apply, good efficacy and tolerability, lack of pain, and easy access for patients in terms of cost and reimbursement issues (36-38).

AK treatments, which may be used by office-based dermatologists and GPs, are compared in Table 2 and discussed in more detail below.

JUST ACCEPTED

Lesion-directed therapies

Physical treatments

Cryotherapy is widely available and commonly used in office-based dermatology for the destruction of single AK lesions with liquid nitrogen. The technique rapidly removes individual clinical lesions, but does not treat field cancerisation or subclinical lesions in the surrounding area and is associated with high rates of disease recurrence of up to 96% within one year (39). The main side effects of cryotherapy are pain, stinging, and burning during treatment. Poor cosmetic

outcomes, in particular hypopigmentation after healing (which is directly correlated with freezing times) are a disadvantage of this treatment (40). There is also a lack of standardisation in how the procedure is performed. According to the authors, cryotherapy is an option for single lesions on the scalp and dorsum of the hands. However, relapse rates after cryotherapy are high, and efficacy can be impaired by hyperkeratosis since it may reduce the cold penetration into the tissue (41). The authors also recommend that field-directed treatment should be performed after cryotherapy.

Other physical treatments which target individual clinical AK lesions include curettage, excision and laser therapy (42). There is less clinical evidence supporting the use of these treatments than for cryotherapy and some are associated with poor cosmetic outcomes and/or need sophisticated equipment and appropriate training.

Cluster-directed therapies

0.5% 5-fluorouracil / 10% salicylic acid

0.5% 5-fluorouracil / 10% salicylic acid solution may be used for the treatment of individual or small clusters of lesions. The 5-fluorouracil component inhibits RNA and DNA synthesis in rapidly dividing cells to preferentially target AK lesions over normal skin cells. The salicylic acid component decreases the hyperkeratosis associated with AK. The treatment is indicated for both slightly palpable and/or moderately thick hyperkeratotic lesions (but not Olsen grade 3 lesions) and is self-applied by the patient once-daily for a maximum of 12 weeks (43). The treatment is applied directly to AK lesions, and therefore, does not treat subclinical lesions in the surrounding field. Some patients, particularly elderly people, may have difficulties in precisely applying the liquid with a brush applicator to the treatment area. Studies have shown

JUST ACCEPTED

that 0.5% 5-fluorouracil / 10% salicylic acid leads to a 70–75% reduction in AK lesions (44,45). Commonly reported side effects include application site irritation and inflammation (44).

Imiquimod 5%

Imiquimod is an immune response modifier, which acts as a Toll-like receptor-7 agonist. It stimulates the local production of cytokines in the epidermis that enhance cellular immunity and also has a direct apoptotic effect on tumour cells (46-48).

Imiquimod 5% cream may be used for the treatment of small clusters of lesions (in an area ≤25 cm^2). The treatment is self-applied by patients three times a week on alternate days for four weeks. After a four-week treatment-free interval, a second course of treatment may be initiated if the patient still has residual lesions. Imiquimod 5% may also be used to treat field cancerisation in sequential treatment courses, although this results in a long overall treatment duration since there should be a rest period between courses (4–8 weeks), and may be associated with a high overall treatment cost.

Clinical studies have shown that imiquimod 5% can detect and clear clinical and subclinical lesions, with a clearance rate of individual clinical lesions of approximately 75% (5,49,50). Disease recurrence rates are low since both clinical and subclinical disease are targeted, with studies reporting recurrence in 27% of patients after 12 months of follow-up (which was substantially lower than with 5-fluorouracil [67%] and cryotherapy [96%] in the same study) (39), in 25% of patients after 16 months (51) and 20% of patients after 24 months (52). Imiquimod 5% has also demonstrated efficacy against superficial basal cell carcinoma (BCC), small nodular BCC and Bowen's disease (53-59). Commonly reported side effects are

JUST ACCEPTED

inflammatory local skin reactions, which may extend beyond the treatment area (49,50,60). Systemic side effects such as flu-like symptoms occur rarely (60).

Ingenol mebutate

Ingenol mebutate is believed to have two mechanisms of action including stimulation of immune responses mediated by neutrophils and induction of necrosis of dysplastic cells. Its exact mechanism of action, however, is not completely clear (61,62). It is available as a 0.05% gel to treat AK lesions located on the trunk or extremities and as a 0.015% gel for the face and scalp. Both ingenol mebutate concentrations may be used for the treatment of small clusters of lesions in an area of 25 cm^2, with the therapy applied on two (0.015%) or three (0.05%) consecutive days. The short treatment duration leads to high patient adherence with the regimen (60,63). Large affected fields may be treated in successive cycles, although this results in long overall treatment durations (as treatment courses need to be separated by an eight-week rest period) and high costs.

The results of four RCTs of ingenol mebutate showed that this AK treatment is associated with median reductions of clinical lesions of 75–83% eight weeks after treatment was completed (63). Out of the patients cleared of lesions at the end of the initial studies, 50–54% had disease recurrence in the treatment field during one year of follow-up (63). Intense local skin reactions such as erythema, flaking/scaling and crusting commonly occur (63,64). These side effects predictably occur in the week following treatment and resolve within 2–4 weeks (60).

JUST ACCEPTED

Large field-directed therapies

Imiquimod 3.75%

Imiquimod 3.75% cream can be used to treat large affected fields (i.e., full face or balding scalp) in one treatment course. Imiquimod 3.75% is applied daily in a simple regimen consisting of 2 two-week treatment cycles, separated by a two-week treatment free interval. It has a strong recommendation for the treatment of multiple AK and field cancerisation in the ILDS/EDF S3 treatment guidelines with the highest percentage of agreement between experts (≥90%) of any field-directed AK therapy (9). Small clusters of lesions may be treated with imiquimod 3.75% or 5%.

The results from RCTs of imiquimod 3.75% have shown that this field-directed treatment leads to an 81.8% median percentage reduction in AK lesions from baseline (65). The appearance of lesions clinically similar to AKs on the treated area, which subsequently disappear during the treatment course, suggests that imiquimod 3.75% may detect and treat both clinical and subclinical lesions (5,65-67). An additional analysis of data from the RCTs showed that imiquimod 3.75% leads to a 92.2% median percentage reduction in lesions from Lmax (maximum lesion count during treatment) to study end (66). The AK lesion reduction with imiquimod 3.75% is also sustained over the long-term (68,69).

The most common side effects with imiquimod 3.75% are local skin reactions, which may extend beyond the treatment area (60). These reactions, in particular erythema, indicate that the treatment is having a beneficial effect (65,70). Rest periods may be taken during either of the two treatment cycles in order to manage local skin reactions, if required, with no impact on efficacy (71). As for imiquimod 5%, rare systemic reactions may occur during treatment with imiquimod 3.75% (72).

JUST ACCEPTED

5% 5-fluorouracil

Five percent 5-fluorouracil cream may be used to treat field cancerisation or small clusters of lesions. It leads to cell death by inhibiting thymidylate synthetase, an enzyme required for DNA synthesis (60). The treatment is easy for patients to self-apply twice a day to the affected area over 3–4 weeks and can be used to treat large areas (up to 500 cm^2) in one treatment course.

RCTs have demonstrated an overall lesion clearance rates of 47–88% with 5-fluorouracil (73-76). Long-term follow-up studies have shown a 12-month disease recurrence rate of 67% (39), whereas 82% of patients required a lesion-directed treatment for recurrent AKs over a mean follow-up of 2.6 years compared with 89% of patients in the control group (75). Comparative clinical studies have indicated that 5% 5-fluorouracil leads to a greater reduction in AK lesions than diclofenac 3% (77,78) and imiquimod 5% (79), and a similar AK lesion reduction to photodynamic therapy with aminolevuinic acid (80).

Five percent 5-fluorouracil is associated with the development of intense, unspecific local skin reactions such as inflammation, pruritus, scaling and crusting, which may limit the size of the treatment field and reduce patient adherence in daily clinical practice (42,73,81). Owing to these intense local skin reactions, studies have shown that 5% 5-fluorouracil is less well tolerated than other AK treatments such as diclofenac sodium 3% and photodynamic therapy (77,78,80). Exposure to sunlight during 5% 5-fluorouracil treatment may increase the intensity of skin reactions (60). Another disadvantage is the potential for life-threatening drug interactions with inhibitors of dihydropyrimidine dehydrogenase such as brivudine (82).

JUST ACCEPTED

Diclofenac 3% in 2.5% hyaluronic acid

Diclofenac is a non-steroidal anti-inflammatory drug which inhibits cyclooxygenase 2. Diclofenac 3% gel in 2.5% hyaluronic acid may be used to treat clustered lesions and field cancerisation. Although easy to apply, diclofenac has to be applied twice-daily for 60–90 days (83), and this lengthy treatment duration may be difficult for many patients to fully comply with.

Some authors consider the efficacy of diclofenac to be lower than other topical treatments (9,60), with the treatment being useful for controlling AK rather than clearing lesions. The overall lesion clearance rates of 54–63% reported in RCTs (84,85) are rarely observed in real-life clinical practice. However, an advantage of diclofenac is its good tolerability with only mild irritant side effects such as pruritus, erythema and dry skin, and only rare occurrences of contact dermatitis (60,84-87).

Photodynamic therapy (PDT)

With PDT, the skin is treated with a photosensitising drug (either aminolevuinic acid or methyl aminolevulinate) which is preferentially accumulated by rapidly dividing atypical keratinocytes. The cells are then eradicated when the skin is exposed to an external light source in the presence of oxygen (88). The procedure may be used to treat small clusters of lesions or large affected fields, although it is not widely available in office-based dermatology. Overall, this physician-administered procedure is time-consuming, can cause severe pain, and may be less convenient for some patients than self-apply a topical medication. Recent studies have shown that daylight PDT is associated with less pain and greater patient satisfaction than conventional PDT, although efficacy may vary according to geographical locations, weather conditions and seasons (89,90). Daylight PDT is increasingly becoming an

JUST ACCEPTED

important option to treat AK, since the patients can apply the photosensitising cream at home and then expose themselves to the sun, without needing repeat physician visits.

RCTs have reported overall lesion clearance rates of 82–91% (91-95) and 12-month disease recurrence rates of 53–64% depending on the type of photosensitising agent that is used (96). The procedure can be associated with intense local reactions such as erythema, stinging/burning and oedema (97).

Combination approaches

The treatment approaches described above may be used in combination with each other according to the clinical situation and patient response to treatment. A lesion-directed treatment may be used to target any lesions remaining after a patient has been treated with a large field-directed therapy. Alternatively, a lesion-directed treatment may be used to clear AK lesions, with a field-directed therapy subsequently being used to treat the actinic damage in the surrounding area. As an example, a study of the use of imiquimod 3.75% after cryosurgery showed that this approach provided significantly greater clearance of AK lesions assessed six months after treatment completion compared with cryosurgery followed by placebo (median percentage reduction: 86.5% vs 50%, respectively, $p<0.0001$) (98). Similarly, sequential use of other AK treatments such as cryosurgery followed by 5-fluorouracil (99) and PDT followed by imiquimod 5% (100) lead to an improvement in AK lesion reduction versus a single treatment.

JUST ACCEPTED

Conclusions and future directions

This article provides office-based dermatologists and GPs with a simple, practical guide for diagnosing AK, classifying patients, and selecting appropriate treatment for them in daily clinical practice. The algorithm differentiates patients according to whether they have scattered lesions, lesions clustered in small fields, or large fields affected by AK, and pragmatically allows physicians to select treatments based on their local availability, the clinical presentation of individual patients and patient preferences. The suggested therapeutic approach is flexible allowing treatments to be used alone or in combination until the goal of treatment, i.e., lesion reduction and long-term disease control, is achieved.

There are several key areas for future investigations, which would strengthen the evidence base on which recommendations for the treatment of AK patients in real-life practice are made. For example, studies are needed to define optimal cut-offs of AK lesions, which separate patients into distinct groups who require different treatment approaches. Well-designed, large-scale RCTs comparing different AK treatments are urgently required as are studies of AK treatments in real-life clinical practice. Long-term studies investigating the effect of AK treatments on the risk of disease progression to invasive SCC would also be informative.

JUST ACCEPTED

Acknowledgements

We thank Dr Ágota Bartha (CentroDerm GmbH, Wuppertal) for assistance with the preparation of figures in this manuscript.

Declaration of interest

TD: Speaker's fees from Almirall, Biofrontera, Galderma, Leo, Meda, GSK, Janssen; advisory board member for Almirall, Biofrontera, Galderma, Leo, Meda; unrestricted grant from Meda.

GG: Received honoraria for presentations and for attending conferences from Almirall, Leo, Meda, Novartis; advisory board member for Leo and Meda.

GM: None.

ES: Consultant contract with Meda, Almirall, Leo, Novartis.

NBS: Consultant and investigator for Leo and Galderma.

VDM: Advisory board member for Galderma and Abbvie.

RD: Consultant contract with Meda. Research support for the institution from Galderma.

GJ: Advisory board member for AbbVie, MSD, Pfizer; Investigator for Abbvie, Actelion, Janssen-Cilag, Leo, Novartis, Regeneron; Speaker's fees from AbbVie, Galderma, Leo, MSD; Unrestricted research grants from AbbVie and Leo.

JM: Speaker's fees from ISDIN, Almirall, Leo, Meda, La Roche Posay, Roche, Bristol-Myers Squibb, Amgen; Advisory board member for Almirall, Leo, Meda, Amgen; Research grants from Almirall, Cantabria, GSK Biological, ISDIN, La Roche Posay, Leo.

KP: Advisory board for Abbvie, Leo, Meda, Roche; Speaker's fees from Leo, Meda, Roche.

JUST ACCEPTED

SP: Advisory board member for Bristol-Myers Squibb, GSK, Leo, Roche; Consultant for Almirall; Research grants from Almirall, Cantabria, GSK Biological, ISDIN, La Roche Posay, Leo; Speaker's fees from Almirall, ISDIN, Leo, La Roche Posay, Roche, Bristol-Myers Squibb.

AS: Speaker's fees from Meda and Leo; Research support and advisory board member for Roche and Novartis.

IZ: Speaker's fees from Almirall, Leo, Meda, La Roche Posay, Roche, Bristol-Myers Squibb, Amgen; advisory board member for Almirall, Leo, Meda, Amgen.

GP: Research grant from Meda and Leo; advisory board member for Roche, Galderma.

This article was funded by Meda. Medical writing assistance in the preparation of this manuscript was provided by David Harrison, Medscript Ltd, funded by Meda.

JUST ACCEPTED

References

1. Goldberg LH, Mamelak AJ. Review of actinic keratosis. Part I: etiology, epidemiology and clinical presentation. J Drugs Dermatol. 2010 Sep;9(9):1125-32.

2. Fenske NA, Spencer J, Adam F. Actinic keratoses: past, present and future. J Drugs Dermatol. 2010 May;9(5 Suppl ODAC Conf Pt 1):s45-s49.

3. Feldman SR, Fleischer AB, Jr. Progression of actinic keratosis to squamous cell carcinoma revisited: clinical and treatment implications. Cutis. 2011 Apr;87(4):201-7.

4. Stockfleth E, Ortonne JP, Alomar A. Actinic keratosis and field cancerisation. Eur J Dermatol. 2011;21 (Suppl 1):3-12.

5. Ulrich M, Krueger-Corcoran D, Roewert-Huber J, Sterry W, Stockfleth E, Astner S. Reflectance confocal microscopy for noninvasive monitoring of therapy and detection of subclinical actinic keratoses. Dermatology. 2010;220(1):15-24.

6. Fernandez-Figueras MT, Carrato C, Saenz X, et al. Actinic keratosis with atypical basal cells (AK I) is the most common lesion associated with invasive squamous cell carcinoma of the skin. J Eur Acad Dermatol Venereol. 2015;29:991-7.

7. Glogau RG. The risk of progression to invasive disease. J Am Acad Dermatol. 2000 Jan;42(1 Pt 2):23-4.

JUST ACCEPTED

8. Green A, Battistutta D. Incidence and determinants of skin cancer in a high-risk Australian population. Int J Cancer. 1990 Sep 15;46(3):356-61.

9. Werner RN, Stockfleth E, Connolly SM, et al. Evidence- and consensus-based (S3) Guidelines for the Treatment of Actinic Keratosis - International League of Dermatological Societies in cooperation with the European Dermatology Forum - Short version. J Eur Acad Dermatol Venereol. 2015 Sep 14;29(11):2069-79.

10. Chetty P, Choi F, Mitchell T. Primary care review of actinic keratosis and its therapeutic options: a global perspective. Dermatol Ther (Heidelb). 2015 Mar;5(1):19-35.

11. Rosen T, Lebwohl MG. Prevalence and awareness of actinic keratosis: barriers and opportunities. J Am Acad Dermatol. 2013 Jan;68(1 Suppl 1):S2-S9.

12. Memon AA, Tomenson JA, Bothwell J, Friedmann PS. Prevalence of solar damage and actinic keratosis in a Merseyside population. Br J Dermatol. 2000 Jun;142(6):1154-9.

13. Frost C, Williams G, Green A. High incidence and regression rates of solar keratoses in a queensland community. J Invest Dermatol. 2000 Aug;115(2):273-7.

14. Schwartz RA, Bridges TM, Butani AK, Ehrlich A. Actinic keratosis: an occupational and environmental disorder. J Eur Acad Dermatol Venereol. 2008 May;22(5):606-15.

JUST ACCEPTED

15. Flohil SC, van der Leest RJ, Dowlatshahi EA, Hofman A, De Vries E, Nijsten T. Prevalence of actinic keratosis and its risk factors in the general population: the Rotterdam Study. J Invest Dermatol. 2013 Aug;133(8):1971-8.

16. Traianou A, Ulrich M, Apalla Z, et al. Risk factors for actinic keratosis in eight European centres: a case-control study. Br J Dermatol. 2012 Aug;167 Suppl 2:36-42.

17. Stockfleth E, Ulrich C, Meyer T, Christophers E. Epithelial malignancies in organ transplant patients: clinical presentation and new methods of treatment. Recent Results Cancer Res. 2002;160:251-8.

18. Uhlenhake EE. Optimal treatment of actinic keratoses. Clin Interv Aging. 2013;8:29-35.

19. MacKie RM. Awareness, knowledge and attitudes to basal cell carcinoma and actinic keratoses among the general public within Europe. J Eur Acad Dermatol Venereol. 2004 Sep;18(5):552-5.

20. Olsen EA, Abernethy ML, Kulp-Shorten C, et al. A double-blind, vehicle-controlled study evaluating masoprocol cream in the treatment of actinic keratoses on the head and neck. J Am Acad Dermatol. 1991 May;24(5 Pt 1):738-43.

21. Schmitz L, Kahl P, Majores M, Bierhoff E, Stockfleth E, Dirschka T. Actinic keratosis: correlation between clinical and histological classification systems. J Eur Acad Dermatol Venereol. 2016; [Epub ahead of print].

JUST ACCEPTED

22. Röwert-Huber J, Patel MJ, Forschner T, et al. Actinic keratosis is an early in situ squamous cell carcinoma: a proposal for reclassification. Br J Dermatol. 2007 May;156 Suppl 3:8-12.

23. Huerta-Brogeras M, Olmos O, Borbujo J, et al. Validation of dermoscopy as a real-time noninvasive diagnostic imaging technique for actinic keratosis. Arch Dermatol. 2012 Oct;148(10):1159-64.

24. Peris K, Micantonio T, Piccolo D, Fargnoli MC. Dermoscopic features of actinic keratosis. J Dtsch Dermatol Ges. 2007 Nov;5(11):970-6.

25. Zalaudek I, Giacomel J, Schmid K, et al. Dermatoscopy of facial actinic keratosis, intraepidermal carcinoma, and invasive squamous cell carcinoma: a progression model. J Am Acad Dermatol. 2012 Apr;66(4):589-97.

26. Malvehy J. A new vision of actinic keratosis beyond visible clinical lesions. J Eur Acad Dermatol Venereol. 2015 Jan;29 Suppl 1:3-8.

27. Ulrich M, Themstrup L, de Carvalho N, et al. Dynamic optical coherence tomography in dermatology. Dermatology. 2016 Apr 23;232(3):298-311.

28. Pellacani G, Neri L, Longo C. Comment to: 'Evidence and consensus based (S3) Guidelines for the Treatment of Actinic Keratosis'. J Eur Acad Dermatol Venereol. 2015 Sep 25[Epub ahead of print].

29. Rowe DE, Carroll RJ, Day CL, Jr. Prognostic factors for local recurrence, metastasis, and survival rates in squamous cell carcinoma of the skin, ear, and lip. Implications for treatment modality selection. J Am Acad Dermatol. 1992 Jun;26(6):976-90.

JUST ACCEPTED

30. Brantsch KD, Meisner C, Schonfisch B, et al. Analysis of risk factors determining prognosis of cutaneous squamous-cell carcinoma: a prospective study. Lancet Oncol. 2008 Aug;9(8):713-20.

31. Perez-Reyes N, Farhi DC. Squamous cell carcinoma of head and neck in patients with well-differentiated lymphocytic lymphoma. Cancer. 1987 Feb 1;59(3):540-4.

32. Esmann S, Jemec GB. Management of actinic keratosis patients: a qualitative study. J Dermatolog Treat. 2007;18(1):53-8.

33. Esmann S, Vinding GR, Christensen KB, Jemec GB. Assessing the influence of actinic keratosis on patients' quality of life: the AKQoL questionnaire. Br J Dermatol. 2013 Feb;168(2):277-83.

34. Esmann S, Jemec GB. Patients' perceptions of topical treatments of actinic keratosis. J Dermatolog Treat. 2014 Oct;25(5):375-9.

35. Shergill B, Zokaie S, Carr AJ. Non-adherence to topical treatments for actinic keratosis. Patient Prefer Adherence. 2013;8:35-41.

36. Stockfleth E, Peris K, Guillen C, et al. A consensus approach to improving patient adherence and persistence with topical treatment for actinic keratosis. Int J Dermatol. 2015 May;54(5):509-15.

37. Stockfleth E, Peris K, Guillen C, et al. Physician perceptions and experience of current treatment in actinic keratosis. J Eur Acad Dermatol Venereol. 2015 Feb;29(2):298-306.

JUST ACCEPTED

38. Peris K, Neri L, Fargnoli MC, Pellacani G. Physicians' concerns towards prescription adherence and treatment effectiveness in the clinical management of actinic keratosis. G Ital Dermatol Venereol. 2014 Apr;149(2):193-8.

39. Krawtchenko N, Roewert-Huber J, Ulrich M, Mann I, Sterry W, Stockfleth E. A randomised study of topical 5% imiquimod vs. topical 5-fluorouracil vs. cryosurgery in immunocompetent patients with actinic keratoses: a comparison of clinical and histological outcomes including 1-year follow-up. Br J Dermatol. 2007 Dec;157 Suppl 2:34-40.

40. Thai KE, Fergin P, Freeman M, et al. A prospective study of the use of cryosurgery for the treatment of actinic keratoses. Int J Dermatol. 2004 Sep;43(9):687-92.

41. Simon JC, Dominicus R, Karl L, Rodriguez R, Willers C, Dirschka T. A prospective randomized exploratory study comparing the efficacy of once-daily topical 0.5% 5-fluorouracil in combination with 10.0% salicylic acid (5-FU/SA) vs. cryosurgery for the treatment of hyperkeratotic actinic keratosis. J Eur Acad Dermatol Venereol. 2015 May;29(5):881-9.

42. Stockfleth E, Ferrandiz C, Grob JJ, Leigh I, Pehamberger H, Kerl H. Development of a treatment algorithm for actinic keratoses: a European Consensus. Eur J Dermatol. 2008 Nov;18(6):651-9.

43. Actikerall. Summary of product characteristics. Available at https://www medicines org uk/emc/medicine/24614. 2014;Last accessed July 2016.

JUST ACCEPTED

44. Stockfleth E, Kerl H, Zwingers T, Willers C. Low-dose 5-fluorouracil in combination with salicylic acid as a new lesion-directed option to treat topically actinic keratoses: histological and clinical study results. Br J Dermatol. 2011 Nov;165(5):1101-8.

45. Szeimies RM, Dirschka T, Prechtl A, Melzer A. Efficacy of low-dose 5-fluorouracil/salicylic acid in actinic keratoses in relation to treatment duration. J Dtsch Dermatol Ges. 2015 May;13(5):430-8.

46. Gaspari AA. Mechanism of action and other potential roles of an immune response modifier. Cutis. 2007 Apr;79(4 Suppl):36-45.

47. Sauder DN. Immunomodulatory and pharmacologic properties of imiquimod. J Am Acad Dermatol. 2000 Jul;43(1 Pt 2):S6-11.

48. Schon M, Bong AB, Drewniok C, et al. Tumor-selective induction of apoptosis and the small-molecule immune response modifier imiquimod. J Natl Cancer Inst. 2003 Aug 6;95(15):1138-49.

49. Alomar A, Bichel J, McRae S. Vehicle-controlled, randomized, double-blind study to assess safety and efficacy of imiquimod 5% cream applied once daily 3 days per week in one or two courses of treatment of actinic keratoses on the head. Br J Dermatol. 2007 Jul;157(1):133-41.

50. Jorizzo J, Dinehart S, Matheson R, et al. Vehicle-controlled, double-blind, randomized study of imiquimod 5% cream applied 3 days per week in one or two courses of treatment for actinic keratoses on the head. J Am Acad Dermatol. 2007 Aug;57(2):265-8.

JUST ACCEPTED

51. Lee PK, Harwell WB, Loven KH, et al. Long-term clinical outcomes following treatment of actinic keratosis with imiquimod 5% cream. Dermatol Surg. 2005 Jun;31(6):659-64.

52. Stockfleth E, Christophers E, Benninghoff B, Sterry W. Low incidence of new actinic keratoses after topical 5% imiquimod cream treatment: a long-term follow-up study. Arch Dermatol. 2004 Dec;140(12):1542.

53. Peris K, Micantonio T, Fargnoli MC, Lozzi GP, Chimenti S. Imiquimod 5% cream in the treatment of Bowen's disease and invasive squamous cell carcinoma. J Am Acad Dermatol. 2006 Aug;55(2):324-7.

54. Schulze HJ, Cribier B, Requena L, et al. Imiquimod 5% cream for the treatment of superficial basal cell carcinoma: results from a randomized vehicle-controlled phase III study in Europe. Br J Dermatol. 2005 May;152(5):939-47.

55. Gollnick H, Barona CG, Frank RG, et al. Recurrence rate of superficial basal cell carcinoma following treatment with imiquimod 5% cream: conclusion of a 5-year long-term follow-up study in Europe. Eur J Dermatol. 2008 Nov;18(6):677-82.

56. Quirk C, Gebauer K, De'Ambrosis B, Slade HB, Meng TC. Sustained clearance of superficial basal cell carcinomas treated with imiquimod cream 5%: results of a prospective 5-year study. Cutis. 2010 Jun;85(6):318-24.

57. Lacarrubba F, Potenza MC, Gurgone S, Micali G. Successful treatment and management of large superficial basal cell carcinomas with topical imiquimod

JUST ACCEPTED

5% cream: a case series and review. J Dermatolog Treat. 2011 Dec;22(6):353-8.

58. Micali G, Lacarrubba F, Nasca MR, De Pasquale R. The use of imiquimod 5% cream for the treatment of basal cell carcinoma as observed in Gorlin's syndrome. Clin Exp Dermatol. 2003 Nov;28 Suppl 1:19-23.

59. Micali G, Lacarrubba F, Nasca MR, Ferraro S, Schwartz RA. Topical pharmacotherapy for skin cancer: part II. Clinical applications. J Am Acad Dermatol. 2014 Jun;70(6):979-12.

60. Micali G, Lacarrubba F, Nasca MR, Schwartz RA. Topical pharmacotherapy for skin cancer: part I. Pharmacology. J Am Acad Dermatol. 2014 Jun;70(6):965-12.

61. Alchin DR. Ingenol mebutate: a succinct review of a succinct therapy. Dermatol Ther (Heidelb). 2014 Aug 27;4:157-64.

62. Zarchi K, Jemec GB. Ingenol mebutate: from common weed to cancer cure. Curr Probl Dermatol. 2015;46:136-42.

63. Lebwohl M, Swanson N, Anderson LL, Melgaard A, Xu Z, Berman B. Ingenol mebutate gel for actinic keratosis. N Engl J Med. 2012 Mar 15;366(11):1010-9.

64. Ricci F, Tambone S, Neri L, et al. Real-life efficacy and safety of ingenol mebutate for the treatment of actinic keratosis of the face and scalp: A single arm retrospective study. J Dermatolog Treat. 2016 Apr 4;1-6.

JUST ACCEPTED

65. Swanson N, Abramovits W, Berman B, Kulp J, Rigel DS, Levy S. Imiquimod 2.5% and 3.75% for the treatment of actinic keratoses: results of two placebo-controlled studies of daily application to the face and balding scalp for two 2-week cycles. J Am Acad Dermatol. 2010 Apr;62(4):582-90.

66. Stockfleth E, Gupta G, Peris K, Aractingi S, Dakovic R, Alomar A. Reduction in lesions from Lmax: a new concept for assessing efficacy of field-directed therapy for actinic keratosis. Results with imiquimod 3.75%. Eur J Dermatol. 2014 Feb 1;24(1):23-7.

67. Kopera D, Kerl H. Visualization and treatment of subclinical actinic keratoses with topical imiquimod 5% cream: an observational study. Biomed Res Int. 2014;2014:135916.

68. Hanke CW, Swanson N, Bruce S, Berman B, Kulp J, Levy S. Complete clearance is sustained for at least 12 months after treatment of actinic keratoses of the face or balding scalp via daily dosing with imiquimod 3.75% or 2.5% cream. J Drugs Dermatol. 2011 Feb;10(2):165-70.

69. Gupta G, Stockfleth E, Peris K, et al. Long-term sustained lesion clearance from Lmax with imiquimod 3.75%, a new field-directed treatment for actinic keratosis. J Eur Acad Dermatol Venereol. 2015;29:1840-2.

70. Tambone S, Fargnoli MC, Capizzi R, Peris K. Clinical experience of imiquimod 3.75% for actinic keratosis: results from a case series. G Ital Dermatol Venereol. 2015 Oct 6[Epub ahead of print].

71. Dirschka T, Peris K, Gupta G, et al. Imiquimod 3.75% in actinic keratosis: efficacy in patients with and without rest periods during treatment. J Eur Acad

JUST ACCEPTED

Dermatol Venereol. 2015;Aug 24:DOI: 10.1111/jdv.13260. [Epub ahead of print].

72. Quist SR, Gollnick HP. Imiquimod 3.75% cream (Zyclara) for the treatment of actinic keratoses. Expert Opin Pharmacother. 2011 Feb;12(3):451-61.

73. Lawrence N, Cox SE, Cockerell CJ, Freeman RG, Cruz PD, Jr. A comparison of the efficacy and safety of Jessner's solution and 35% trichloroacetic acid vs 5% fluorouracil in the treatment of widespread facial actinic keratoses. Arch Dermatol. 1995 Feb;131(2):176-81.

74. Gupta AK. The management of actinic keratoses in the United States with topical fluorouracil: a pharmacoeconomic evaluation. Cutis. 2002 Aug;70(2 Suppl):30-6.

75. Pomerantz H, Hogan D, Eilers D, et al. Long-term efficacy of topical fluorouracil cream, 5%, for treating actinic keratosis: a randomized clinical trial. JAMA Dermatol. 2015 Sep;151(9):952-60.

76. Loven K, Stein L, Furst K, Levy S. Evaluation of the efficacy and tolerability of 0.5% fluorouracil cream and 5% fluorouracil cream applied to each side of the face in patients with actinic keratosis. Clin Ther. 2002 Jun;24(6):990-1000.

77. Segatto MM, Dornelles SI, Silveira VB, Frantz GO. Comparative study of actinic keratosis treatment with 3% diclofenac sodium and 5% 5-fluorouracil. An Bras Dermatol. 2013 Sep;88(5):732-8.

78. Smith SR, Morhenn VB, Piacquadio DJ. Bilateral comparison of the efficacy and tolerability of 3% diclofenac sodium gel and 5% 5-fluorouracil cream in

JUST ACCEPTED

the treatment of actinic keratoses of the face and scalp. J Drugs Dermatol. 2006 Feb;5(2):156-9.

79. Tanghetti E, Werschler P. Comparison of 5% 5-fluorouracil cream and 5% imiquimod cream in the management of actinic keratoses on the face and scalp. J Drugs Dermatol. 2007 Feb;6(2):144-7.

80. Smith S, Piacquadio D, Morhenn V, Atkin D, Fitzpatrick R. Short incubation PDT versus 5-FU in treating actinic keratoses. J Drugs Dermatol. 2003 Dec;2(6):629-35.

81. Epstein E. Does intermittent "pulse" topical 5-fluorouracil therapy allow destruction of actinic keratoses without significant inflammation? J Am Acad Dermatol. 1998 Jan;38(1):77-80.

82. Efudix. Summary of product characteristics. Available at: http://www medicines org uk/emc/medicine/6219/SPC/Efudix+Cream. 2014;Last accessed July 2016.

83. Diclofenac sodium 3%. Summary of product characteristics. Available at: http://www medicines org uk/emc/medicine/21229/SPC. 2012;Last accessed July 2016.

84. Gebauer K, Brown P, Varigos G. Topical diclofenac in hyaluronan gel for the treatment of solar keratoses. Australas J Dermatol. 2003 Feb;44(1):40-3.

85. Rivers JK, Arlette J, Shear N, Guenther L, Carey W, Poulin Y. Topical treatment of actinic keratoses with 3.0% diclofenac in 2.5% hyaluronan gel. Br J Dermatol. 2002 Jan;146(1):94-100.

JUST ACCEPTED

86. Wolf JE, Jr., Taylor JR, Tschen E, Kang S. Topical 3.0% diclofenac in 2.5% hyaluronan gel in the treatment of actinic keratoses. Int J Dermatol. 2001 Nov;40(11):709-13.

87. Nelson CG. Diclofenac gel in the treatment of actinic keratoses. Ther Clin Risk Manag. 2011;7:207-11.

88. Marmur ES, Schmults CD, Goldberg DJ. A review of laser and photodynamic therapy for the treatment of nonmelanoma skin cancer. Dermatol Surg. 2004 Feb;30(2 Pt 2):264-71.

89. Lacour JP, Ulrich C, Gilaberte Y, et al. Daylight photodynamic therapy with methyl aminolevulinate cream is effective and nearly painless in treating actinic keratoses: a randomised, investigator-blinded, controlled, phase III study throughout Europe. J Eur Acad Dermatol Venereol. 2015 Oct 5;29(12):2342-8.

90. Rubel DM, Spelman L, Murrell DF, et al. Daylight photodynamic therapy with methyl aminolevulinate cream as a convenient, similarly effective, nearly painless alternative to conventional photodynamic therapy in actinic keratosis treatment: a randomized controlled trial. Br J Dermatol. 2014 Nov;171(5):1164-71.

91. Pariser DM, Lowe NJ, Stewart DM, et al. Photodynamic therapy with topical methyl aminolevulinate for actinic keratosis: results of a prospective randomized multicenter trial. J Am Acad Dermatol. 2003 Feb;48(2):227-32.

92. Freeman M, Vinciullo C, Francis D, et al. A comparison of photodynamic therapy using topical methyl aminolevulinate (Metvix) with single cycle

JUST ACCEPTED

cryotherapy in patients with actinic keratosis: a prospective, randomized study. J Dermatolog Treat. 2003 Jun;14(2):99-106.

93. Pariser D, Loss R, Jarratt M, et al. Topical methyl-aminolevulinate photodynamic therapy using red light-emitting diode light for treatment of multiple actinic keratoses: A randomized, double-blind, placebo-controlled study. J Am Acad Dermatol. 2008 Oct;59(4):569-76.

94. Piacquadio DJ, Chen DM, Farber HF, et al. Photodynamic therapy with aminolevulinic acid topical solution and visible blue light in the treatment of multiple actinic keratoses of the face and scalp: investigator-blinded, phase 3, multicenter trials. Arch Dermatol. 2004 Jan;140(1):41-6.

95. Hauschild A, Stockfleth E, Popp G, et al. Optimization of photodynamic therapy with a novel self-adhesive 5-aminolaevulinic acid patch: results of two randomized controlled phase III studies. Br J Dermatol. 2009 May;160(5):1066-74.

96. Dirschka T, Radny P, Dominicus R, et al. Long-term (6 and 12 months) follow-up of two prospective, randomized, controlled phase III trials of photodynamic therapy with BF-200 ALA and methyl aminolaevulinate for the treatment of actinic keratosis. Br J Dermatol. 2013 Apr;168(4):825-36.

97. Stockfleth E. The paradigm shift in treating actinic keratosis: a comprehensive strategy. J Drugs Dermatol. 2012 Dec 1;11(12):1462-7.

98. Jorizzo JL, Markowitz O, Lebwohl MG, et al. A randomized, double-blinded, placebo-controlled, multicenter, efficacy and safety study of 3.75% imiquimod

JUST ACCEPTED

cream following cryosurgery for the treatment of actinic keratoses. J Drugs Dermatol. 2010 Sep;9(9):1101-8.

99. Hoover WD, III, Jorizzo JL, Clark AR, Feldman SR, Holbrook J, Huang KE. Efficacy of cryosurgery and 5-fluorouracil cream 0.5% combination therapy for the treatment of actinic keratosis. Cutis. 2014 Nov;94(5):255-9.

100. Shaffelburg M. Treatment of actinic keratoses with sequential use of photodynamic therapy; and imiquimod 5% cream. J Drugs Dermatol. 2009 Jan;8(1):35-9.

101. Tavin E, Persky M. Metastatic cutaneous squamous cell carcinoma of the head and neck region. Laryngoscope. 1996 Feb;106(2 Pt 1):156-8.

JUST ACCEPTED

Table 1. AK patients at high risk of progression to invasive squamous cell carcinoma or metastatic disease.

Supported by evidence	Expert opinion

• AKs on body areas such as the ear and lip (29,30)
• Early disease relapse following treatment (101)
• Immunocompromised patients (29,30)
  ○ Elderly
  ○ Organ transplant recipients
  ○ Rheumatological disease
  ○ Haematological disease
  ○ Inflammatory bowel disease
  ○ Chronic lymphocytic leukaemia
	• Poor response to treatment
	• High cumulative lifetime sun exposure (occupational or recreational)
	• Personal history of skin cancer
	• Many AK lesions
	• Fair skin type
	• Smoking
	• Alcoholism
	• Other diseases affecting patients' immunocompetence

AK, actinic keratosis.

JUST ACCEPTED

Table 2. Comparison of AK treatments.

Treatment	Lesion-directed	Cluster-directed	Large field-directed	Advantages	Disadvantages
Physical treatments *Cryotherapy* *Curettage* *Lasers*	Yes	No	No	➢ Rapid ➢ Widely available and used in office-based dermatology	➢ Poor standardisation of procedure ➢ Poor cosmetic outcomes ➢ Does not address subclinical disease ➢ Supporting evidence for cryotherapy only
0.5% 5-fluorouracil/10% salicylic acid	Yes	Yes	No	➢ Self-administration	➢ Difficulty in self-application ➢ Irritant reactions ➢ Does not

JUST ACCEPTED

					treat subclinical lesions
Imiquimod 5%	No	Yes	Yes, sequential use	➢ Efficacy ➢ Targeted therapy: active on subclinical lesions ➢ Also active on Bowen's disease, superficial BCC	➢ Long treatment duration for large fields (i.e., repeat treatments) ➢ Inflammatory reactions extending beyond treatment area ➢ Rare systemic reactions (e.g., flu-like symptoms)
Ingenol mebutate	No	Yes	Yes, sequential use	➢ Efficacy ➢ Short treatment duration for clustered	➢ Long treatment duration for large fields (i.e., repeat

JUST ACCEPTED

				lesions ➢ Predictability of local skin reactions ➢ High adherence ➢ Can be used to treat trunk and extremities (in addition to face and scalp)	treatments) ➢ Intense irritant reactions
Imiquimod 3.75%	No	Yes	Yes	➢ Efficacy ➢ Can treat large field (full face or balding scalp) in one treatment course ➢ Short treatment duration for large field	➢ Inflammatory reactions extending beyond treatment area ➢ Rare systemic reactions (e.g., flu-like symptoms)

JUST ACCEPTED

				➢ Targeted therapy: active on subclinical lesions ➢ Easy self-application ➢ Personalised management	
5% 5-fluorouracil	No	Yes	Yes	➢ Easy self-application ➢ Can treat large field in one treatment course	➢ Intense, unspecific local reactions ➢ Possible drug interactions (e.g., brivudine)
Diclofenac 3% in 2.5% hyaluronic acid	No	Yes	Yes	➢ Easy self-application ➢ Good tolerability	➢ Long treatment duration ➢ Poor adherence

JUST ACCEPTED

					➢ Low efficacy
Photodynamic therapy	No	Yes	Yes	➢ Efficacy	➢ Availability in office-based dermatology ➢ Cannot be self-applied ➢ Intense local reactions ➢ Pain

AK, actinic keratosis; BCC, basal cell carcinoma.

Yes / No, means recommended or not recommended by the authors, respectively.

Although field-directed therapies may be used to treat individual lesions, the recommendations reflect practical considerations and the situation in real-life, office-based dermatology.

JUST ACCEPTED

Figure Legends

Figure 1. Concept of field cancerisation.

In this image of a severely sun-damaged scalp, clinically and dermoscopically visible invasive squamous cell carcinoma (upper right insert), Bowen's disease (lower right insert) and AKs (upper left) co-exist with subclinical lesions that are only seen by histopathology (lower left).

Figure 2. Clinical and dermoscopic grading of AK.

Left image – grade 1; middle image – grade 2; right image – grade 3.

Figure 3. Dermoscopy for treatment monitoring.

Left image – clinical and dermoscopic criteria of AK are present; right image – clinical and dermoscopic criteria of AK have disappeared. This also corresponds well with histopathological clearance.

Figure 4. Classification of AK lesions: (A) isolated lesion; (B) multiple lesions clustered in a small field; (C) multiple lesions across a large field (entire scalp).

Figure 5. Practical algorithm for the treatment of AK.

AK, actinic keratosis; iSCC, invasive squamous cell carcinoma.

*Pre-treatment (e.g., curettage, laser ablation) to remove hyperkeratosis.

†Discharge and follow-up patient if treatment success is achieved; move patient to different AK treatment if treatment success is not achieved.

JUST ACCEPTED

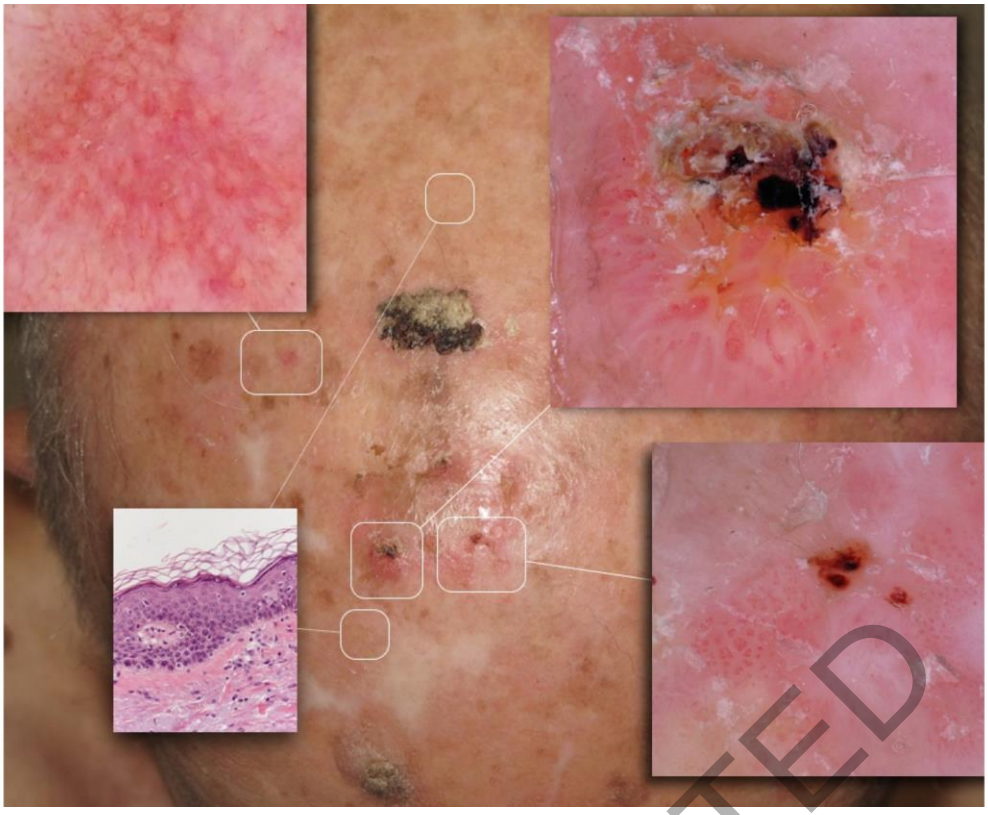



JUST ACCEPTED





JUST ACCEPTED



JUST ACCEPTED



JUST ACCEPTED

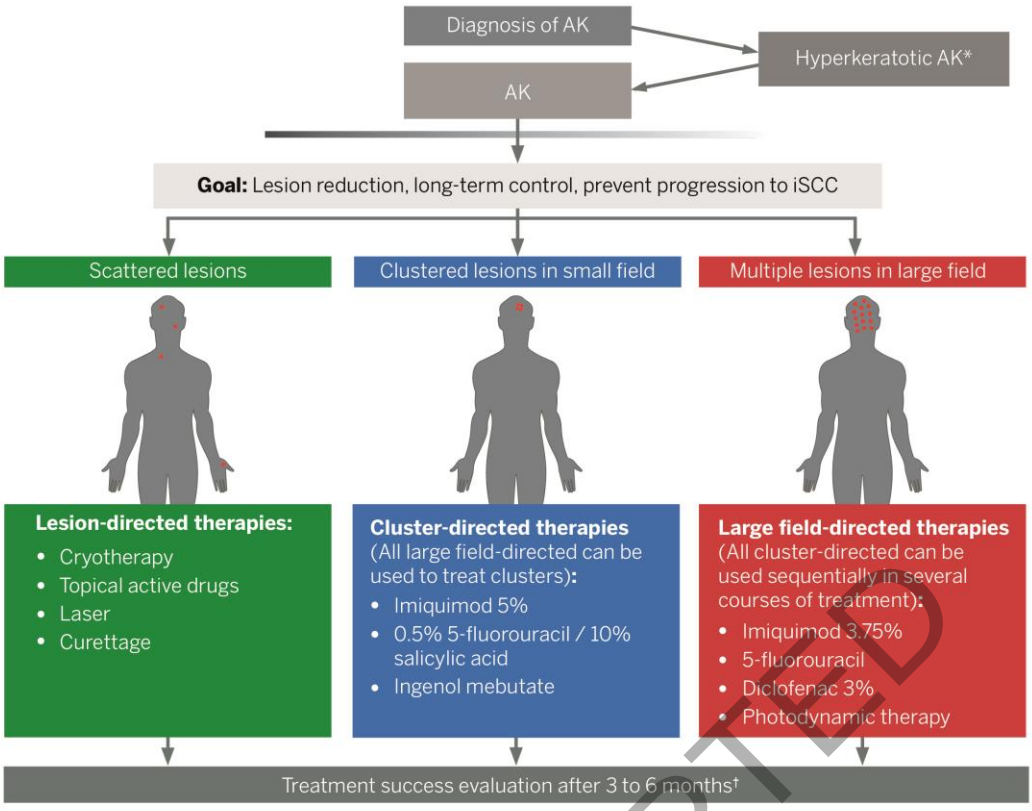

General recommendations for all patients: sun protection and avoid sun exposure

JUST ACCEPTED