

This is the peer reviewed version of the following article:

Facial lipohypertrophy in HIV-infected subjects who underwent autologous fat tissue transplantation / Guaraldi, Giovanni; De Fazio, D.; Orlando, G.; Murri, R.; Wu, A.; Guaraldi, Pietro; Esposito, Roberto. - In: CLINICAL INFECTIOUS DISEASES. - ISSN 1058-4838. - ELETTRONICO. - 40:2(2005), pp. 13-15. [10.1086/426686]

Terms of use:

The terms and conditions for the reuse of this version of the manuscript are specified in the publishing policy. For all terms of use and more information see the publisher's website.

07/05/2026 04:28

Facial Lipohypertrophy in HIV-Infected Subjects Who Underwent Autologous Fat Tissue Transplantation

Giovanni Guaraldi,¹ Domenico De Fazio,³ Gabriella Orlando,¹ Rita Murri,⁴ Albert Wu,⁵ Pietro Guaraldi,² and Roberto Esposito¹

¹Clinica delle Malattie Infettive and ²Clinica Neurologica, Università degli Studi di Modena e Reggio Emilia, Modena, and ³Chirurgia Plastica, Ospedale San Raffaele, Milan, and ⁴Clinica delle Malattie Infettive, Università Cattolica del "Sacro Cuore," Rome, Italy; and ⁵Johns Hopkins School of Public Health, Johns Hopkins University, Baltimore, Maryland

Of 41 HIV-infected patients with facial lipoatrophy who underwent autologous fat transplantation, disfiguring facial lipohypertrophy at the graft site occurred at the same time as recurrent fat accumulation at the tissue harvest site in 4 patients who had had fat transferred from the dorsocervical fat pad or from subcutaneous abdominal tissue.

Lipodystrophy associated with HAART includes subcutaneous fat loss (i.e., lipoatrophy) in the face, limbs, or buttocks and/or fat accumulation (i.e., lipohypertrophy) in the abdomen, in the breast, and/or on the dorsocervical spine (resulting in a dorsocervical fat pad or "buffalo hump") [1]. In patients with lipodystrophy, switching from treatment with either of the thymidine nucleoside analogues, stavudine or zidovudine, to treatment with the nonthymidine analogue abacavir resulted in a mild increase in peripheral fat mass; however, facial lipoatrophy did not improve [2]. The only currently available clinical interventions to treat facial lipoatrophy are fat transplantation surgery or injection with inert colloidal preparations.

Patients and methods. At our Metabolic Clinic in Modena, Italy, 41 HIV-infected patients with facial lipoatrophy underwent autologous fat transplantation to treat facial-fat wasting [3, 4]. Surgery was performed using the technique described by Coleman [3]. Intact fat-tissue parcels were harvested, and the nonviable components were removed; mechanical trauma, exposure to infectious agents, and direct contact with air were

avoided to allow the graft to remain metabolically active. The graft was implanted with small cannulae in the subcutaneous space to allow nutrition and cell anchoring. The source of the graft was the subcutaneous abdominal region in 27 patients, the dorsocervical fat pad in 14 patients, the breast in 2 patients, and the pubis region in 2 patients. Few patients had multiple harvest sites as the graft source.

Results. Of the 41 patients, 32.1% were women, and 21% had Centers for Disease Control and Prevention (CDC) stage C HIV disease. At baseline, the mean values (\pm SD) for clinical characteristics and laboratory values were as follows: age, 43 ± 6 years; nadir CD4 cell count, 191 ± 151 cells/ μ L; duration of exposure to HAART, 65 ± 17 months; and duration of exposure to stavudine, 44 ± 19 months. At the time of surgery, the patients' mean (\pm SD) CD4 cell count was 582 ± 248 cells/ μ L, and the median HIV load was $9621 \pm 24,867$ copies/mL.

Surgery resulted in a safe, effective, and durable aesthetic result in all patients, with a mean increase in the subcutaneous thickness of the cheeks of 5.5 mm (SD \pm 2.4 mm). After a median of 17.5 months postsurgery, 4 patients who had fat tissue harvested from a single site developed renewed fat accumulation at the harvest site. All 4 of these patients developed simultaneous facial graft hypertrophy. For 3 patients, the graft source had been the dorsocervical fat pad, and, for 1 patient, the graft source had been subcutaneous abdominal fat tissue. Patients described themselves as looking like "hamsters," because of the prominence of their cheeks.

During the follow-up period, the 4 patients had their treatment switched from stavudine to abacavir or tenofovir and from a protease inhibitor to a nonnucleoside reverse-transcriptase inhibitor or multiple nucleoside reverse-transcriptase inhibitors. None of the patients received steroids. The mean increase in body weight was 2 kg.

Progressive facial lipohypertrophy of the cheeks after surgery was documented by ultrasonography that was performed, in all cases, by the same operator with a high-frequency (7.5 MHz) transducer (3-GE Medical System; LOGIQ).

The mean increase in the subcutaneous thickness of the cheeks from the time of surgery to the evaluation at month 24 was 14.6 mm (SD \pm 2.1 mm; $P = .07$) in the 4 patients. Figure 1 shows the increase in the subcutaneous thickness of the cheeks in the 4 patients, compared with that of the overall cohort, and also shows the morphological appearance of patient 1.

Discussion. The reasons for fat depletion and accumulation in HIV-infected patients receiving antiretroviral therapy remain unexplained. Microscopic examination of adipocytes in patients

Received 23 July 2004; accepted 23 August 2004; electronically published 21 December 2004.

Reprints or correspondence: Dr. Giovanni Guaraldi, Dept. of Medicine and Medicine Specialties, Infectious Diseases Clinic, University of Modena and Reggio Emilia School of Medicine, Via del Pozzo 71, 41100 Modena, Italy (g.guaraldi@unimo.it).

Clinical Infectious Diseases 2005;40:e13-5

© 2004 by the Infectious Diseases Society of America. All rights reserved.
1058-4838/2005/4002-00E2\$15.00

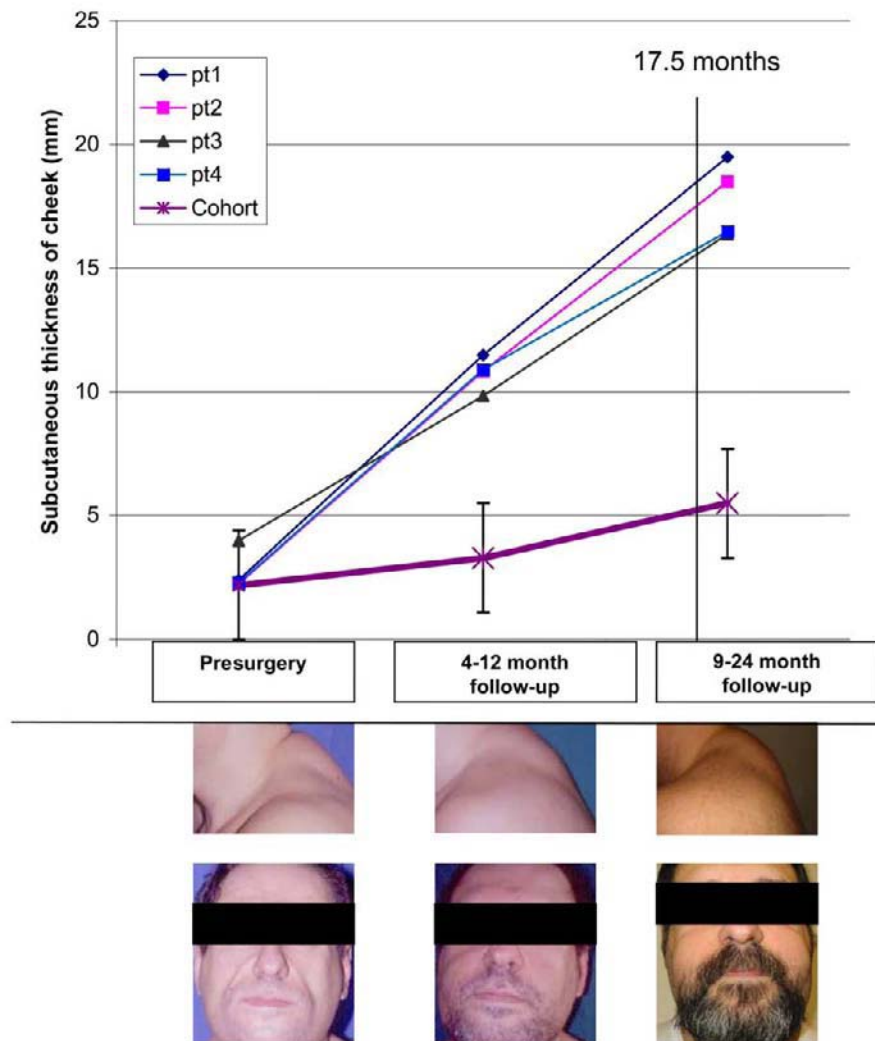


Figure 1. *Top panel*, Subcutaneous increase in cheek thickness, as measured by ultrasonography, in the 4 patients with facial lipohypertrophy (pt 1–4), as well as the mean thickness for the overall cohort (*whiskers* indicate SDs). *Bottom panel*, Photographs show lipohypertrophy of the dorsocervical fat pad (*upper row*) and simultaneous hypertrophy of the facial fat graft (*lower row*). Written permission for use of the photographs was obtained from the patient.

with lipoatrophy shows remodeling that involves a combination of apoptosis, defective lipogenesis, and increased metabolic activity in different areas [5]. Antiretroviral drugs may impair lipid metabolism enzymes, which may result in hyperlipidemia, insulin resistance, and apoptosis of adipocytes, because of the great similarity between the low-density lipoprotein-receptor-related protein and the cytoplasmic retinoic acid-binding protein type I. Several of the commonly used nucleoside analogues inhibit mitochondrial enzymes (e.g., γ -polymerase), producing a progressive loss of mtDNA, with impairment of the oxidative phosphorylation pathway.

Antiretroviral drugs may cause downregulation of TNF- α homeostasis, altering transcriptional regulation, glucose levels, fatty acid metabolism, and hormone receptor signaling. Hypertrophy of the subcutaneous, denervated fat that was trans-

planted in the cheeks clearly suggests that the abnormal distribution of adipose tissue in HIV-infected patients cannot be entirely explained as a selective neuropathy mediated via the CNS but that some other circulating or humoral factor, as yet unknown, should be taken into account to explain the pathogenesis of HIV-associated adipose redistribution syndrome [6].

Our observations do not provide evidence for any pathogenic mechanism. The syndrome is unlikely to depend only on paracrine factors, such as cytokine signals. In fact, paracrine factors were present where the lipid alteration appeared, but relapse occurred in a different area. Adipocyte receptors and mitochondrial toxicity-related mechanisms could explain how receptor expression, as well as mtDNA, could be transferred from the harvest site to the graft site and remain sensitive to

lipohypertrophy determinants. Another hypothesis is that lipohypertrophy of the cheeks may be the result of the expansion of brown fat that is transferred with the intervention. Ultrastructural observation suggests that dorsocervical fat consists mainly of brown fat, and its expansion has been demonstrated in areas undergoing white-fat atrophy, such as subcutaneous abdominal tissue. Our data suggests that brown fat, which has a higher mitochondria content, could be more prone to lipohypertrophy and that it may be a mechanism that compensates for fat atrophy.

The influence of genetic factors is suggested, as only a minority of the patients (21% of patients who received a graft from the dorsocervical fat pad and 4% of patients who received a graft from other sites) developed lipohypertrophy at the graft site. A clinical implication is that, when autologous fat transplantation is chosen for the treatment of facial lipoatrophy, the preferred subcutaneous harvest site should be the abdomen or pubis region.

Acknowledgments

We thank A. Grisotti, M. Callegari, M. De Lorenzi, I. Pecorari, and M. Blini, for their active contribution in the surgery activities; G. Nardini and

B. Beghetto, for their assistance in the project; and G. Amorico, for performing ultrasonography.

Potential conflicts of interest. All authors: no conflicts.

References

1. Lichtenstein K, Delaney KM, Armon C, et al. Incidence and risk factors for lipoatrophy (abnormal fat loss) in ambulatory HIV-1-infected patients. *J Acquir Immune Defic Syndr* **2003**;32:48–56.
2. Moyle GJ, Baldwin C, Langroudi B, Mandalia S, Gazzard BG. A 48-week, randomized, open-label comparison of three abacavir-based substitutions approaches in the management of dyslipidemia and peripheral lipoatrophy. *J Acquir Immune Defic Syndr* **2003**;33:22–8.
3. Coleman SR. Structural fat graft: the ideal filler? *Clinic Plastic Surg* **2001**;28:111–9.
4. Guaraldi G, De Fazio D, Orlando G, et al. Autologous fat transfer for treating facial wasting in HIV body fat redistribution syndrome [abstract 722]. In: Program and abstracts of the 10th Conference on Retroviruses and Opportunistic Infections (Boston). **2003**. Available at: <http://www.retroconference.org/2003/>. Accessed 19 December 2004.
5. Lloreta J, D'Amico P, Pujol RM, et al. Ultrastructural feature of highly active antiretroviral therapy-associated partial lipodystrophy. *Virchows Archives* **2002**;441:599–604.
6. Fliers E, Sauerwein HP, Romijn JA, et al. HIV-associated adipose redistribution syndrome as a selective autonomic neuropathy. *Lancet* **2003**;362:1758–60.