This is the peer reviewd version of the followng article:

Rituximab in the treatment of patients with systemic sclerosis. Our experience and review of the literature / Giuggioli, Dilia; Lumetti, Federica; Colaci, Michele; Fallahi, Poupak; Antonelli, Alessandro; Ferri, Clodoveo. - In: AUTOIMMUNITY REVIEWS. - ISSN 1568-9972. - STAMPA. - 14:11(2015), pp. 1072-1078. [10.1016/j.autrev.2015.07.008]

Terms of use:

The terms and conditions for the reuse of this version of the manuscript are specified in the publishing policy. For all terms of use and more information see the publisher's website.

08/05/2026 18:31

(Article begins on next page)

Accepted Manuscript

Rituximab in the treatment of patients with systemic sclerosis. Our experience and review of the literature

Dilia Giuggioli, Federica Lumetti, Michele Colaci, Poupak Fallahi, Alessandro Antonelli, Clodoveo Ferri

PII: S1568-9972(15)00157-3
DOI: doi: 10.1016/j.autrev.2015.07.008
Reference: AUTREV 1744

To appear in: *Autoimmunity Reviews*

Received date: 3 July 2015
Accepted date: 17 July 2015

Please cite this article as: Giuggioli Dilia, Lumetti Federica, Colaci Michele, Fallahi Poupak, Antonelli Alessandro, Ferri Clodoveo, Rituximab in the treatment of patients with systemic sclerosis. Our experience and review of the literature, *Autoimmunity Reviews* (2015), doi: 10.1016/j.autrev.2015.07.008

This is a PDF file of an unedited manuscript that has been accepted for publication. As a service to our customers we are providing this early version of the manuscript. The manuscript will undergo copyediting, typesetting, and review of the resulting proof before it is published in its final form. Please note that during the production process errors may be discovered which could affect the content, and all legal disclaimers that apply to the journal pertain.

ACCEPTED MANUSCRIPT

\Rituximab in the treatment of patients with systemic sclerosis. Our experience and review of the literature.

Dilia Giuggioli, MD[1], Federica Lumetti MD[1], Michele Colaci, MD[1], Poupak Fallahi, MD[2], Alessandro Antonelli, MD[2], and Clodoveo Ferri, MD[1]

[1]*Chair and Rheumatology Unit, University of Modena and Reggio Emilia, Medical School, Azienda Ospedaliero-Universitaria, Policlinico di Modena, Modena, Italy.*
[2]*Department of Internal Medicine, School of Medicine, University of Pisa, Pisa, Italy.*

ACCEPTED MANUSCRIPT

Running title:
Rituximab and scleroderma

Key words: scleroderma, systemic sclerosis, rituximab, anti-CD20, arthritis, skin sclerosis, lung fibrosis

Words count of the abstract: 413
Words count of the text: 3,025

Corresponding author:

Clodoveo Ferri, MD
Chair and Rheumatology Unit
Dpt of Internal Medicine, University of Modena and Reggio E.
Policlinico di Modena
Via del Pozzo, 71
41100 Modena Italy
Tel +39-059-4224053
Fax +39-059-4224178

E-mail : clferri@unimore.it

ACCEPTED MANUSCRIPT

Abstract

Background. The treatment of systemic sclerosis (SSc) represents a great clinical challenge because of the complex disease pathogenesis including vascular, fibrotic, and immune T- and B-lymphocyte-mediated alterations. Therefore, SSc should be treated by combined or sequential therapies according to prevalent clinico-pathogenetic phenotypes. Some preliminary data suggest that rituximab (RTX) may downregulate the B-cell over expression and correlated immunological abnormalities.

Methods. Here, we describe a series of 10 SSc patients (4 M and 6 F, mean age 46±13.5SD years, mean disease duration 6.3±2.7SD years; 5 pts had limited and 5 diffuse SSc cutaneous subset) treated with one or more cycles of RTX (4 weekly infusions of 375 mg/m2). The main indications to RTX were interstitial lung fibrosis, cutaneous, and/or articular manifestations unresponsive to previous therapies; ongoing treatments remained unchanged in all cases. The effects of RTX were evaluated after 6 months of the first cycle and at the end of long-term follow-up period (37±21SD months, range 18-72 months).

An updated review of the world literature was also done.

Results. RTX significantly improved the extent of skin sclerosis in patients with diffuse SSc at 6 months evaluation (modified Rodnan skin score from 25±4.3 to 17.2±4.6; p =.022). A clinical improvement of other cutaneous manifestations, namely hypermelanosis (7/7), pruritus (6/8), and calcinosis (3/6) was observed. Moreover, arthritis revealed particularly responsive to RTX showing a clear-cut reduction of swollen and tender joints in 7/8 patients; while lung fibrosis detected in 8/10 remained stable in 6/8 and worsened in 2/8 at the end of follow-up. Pro-inflammatory cytokines, namely IL6, IL15, IL17, and IL23, evaluated in 3 patients with diffuse cutaneous SSc, showed a more or less pronounced reduction after the first RTX cycle.

These observations are in keeping with the majority of previous studies including 6 single case reports and 10 SSc series (from 5 to 43 pts), which frequently reported the beneficial effects of RTX on some SSc manifestations, particularly cutaneous sclerosis, along with the improvement/stabilization of lung fibrosis. Possible discrepancies among different clinical studies can be related to the etiopathogenetic complexity of SSc and not secondarily to the patients' selection and disease duration at the time of the study.

Conclusion. The present study and previous clinical trials suggest a possible therapeutical role of RTX in SSc, along with its good safety profile. The specific activity of RTX on B-cell-driven autoimmunity might explain its beneficial effects on some particular SSc clinical symptoms, namely the improvement of skin and articular involvement, and possibly the attenuation of lung fibrosis.

1.Introduction

Systemic sclerosis (SSc) is a connective tissue disease characterized by specific autoimmune abnormalities, diffuse microangiopathy, and accumulation of collagen

ACCEPTED MANUSCRIPT

and other matrix constituents in the skin and target internal organs [1, 2]. Clinically, SSc appears as multifaceted disorder consequent to the variable contribution of the above pathogenetic mechanisms, through a multistep process responsible for different clinical phenotypes. These latter represent a variable combination and degree of typical SSc symptoms: from vascular manifestations, i.e. skin ulcers, pulmonary arterial hypertension, and/or renal scleroderma crisis, to fibrotic cutaneous and visceral organ involvement [1-4]. Abnormal humoral and cellular immune activation may decisively contribute to both vascular and fibrotic SSc manifestations [1-4]; however, the complex and pleiotropic nature of the immune response in SSc constitutes a great therapeutic challenge [1-6]. The effects of nonselective immunosuppressive treatments, usually employed during the early phases of SSc to control skin and lung inflammation, are often unpredictable. In addition, they tend to lose their efficacy once the disease enters a chronic phase, and consequently their long-term treatment is not recommendable considering their potential severe side-effects [4].

Given the close interrelationship between altered immune response and initiation/propagation of the other SSc pathogenetic events, the usefulness of novel immunomodulating therapies targeting specific cellular and/or molecular immune effectors requires to be carefully investigated [6]. In particular, the rationale for the use of rituximab (RTX), able to downregulate the B-cell over experession, is largely demonstrated in different autoimmune diseases [7-14]; moreover, some important experimental data suggested a key role for B cells in regulating both inflammatory and fibrotic alterations that characterize several SSc manifestations [4, 6, 15, 16]. On the basis of laboratory investigations, during the last years preliminary clinical trials have suggested the therapeutical usefulness of RTX also in SSc [17-18].
Here we report our experience with RTX treatment in a series of SSc patients along with the updated review of the world literature on this topic.

1.1. Patients and methods

The present study included 10 SSc patients (4 M and 6 F, mean age 46 ± 13.5SD years, mean disease duration 6.3 ± 2.7 SD years) treated with one or more cycles of RTX and evaluated during a mean follow-up period of 37±21SD months, range 18-72 months (Tab. 1). All patients, followed at our University-based Rheumatology Unit, satisfied EULAR/ACR 2013 criteria for SSc classification [19].
Scleroderma cutaneous and visceral organ involvement, including pulmonary, cardiac, renal, and gastrointestinal alterations, as well as routine blood chemistry, urinalysis, and immunological alterations were evaluated according to previously described methodologies [3, 5]. The following serological markers were detected by means of standard techniques: anti-nuclear (ANA), anti-centromere (ACA), anti-nucleolar (ANoA), and anti-extractable nuclear antigen (ENA) antibodies; these latter included anti-Scl70, -Sm, -RNP, -SSB, -SSA, -PCNA, -SL, and Jo1 [3].
In addition, standard pulmonary function tests (PFTs), namely FVCnd a DLCO, 6-minute walking test, high-resolution computed tomography (HRCT), trans-thoracic echo-color-Doppler cardiography (ECHOcg), and nailfold videocapillaroscopy were performed in all patients at baseline, after 6 months of RTX treatment, and at the end of follow up. With the same timing, an experienced physician evaluated, in a blinded fashion, the extent of skin thickening measured by modified Rodnan skin score (mRSS), the presence and severity of skin ulcers, melanodermia, teleangectasias, calcinosis, pruritus, and tender and/or swelling joints. Four patients

ACCEPTED MANUSCRIPT

with abnormally increased pulmonary arterial systolic pressure at ECHOcg underwent to right heart catheterization.
All patients gave their written informed consent to enter in the study.
At the starting of RTX treatment, the patients showed one or more active SSc clinical manifestations, scarcely responsive to previous and/or ongoing treatments (Tab. 1). Patients were treated with one or more cycles of RTX; each cycle included 4 infusions of RTX 375 mg/m^2 of body surface area once weekly, always in combination with other ongoing therapies (iloprost, calcium-channel blockers, steroids and/or bosentan). Nine patients underwent to a second RTX cycle after 6 months; moreover, in 4/9 subjects RTX was repeated once yearly for a total of 3-5 cycles. In only one patient the initial RTX cycle was interrupted after the first two infusions because of severe sepsis. Besides routine laboratory examinations, at baseline and after six months of RTX therapy, circulating CD19-positive cell count were carried out in all cases by flow cytometry; moreover, serum levels of some pro-inflammatory interleukins were measured in 3 patients by means of commercially available assays (Human IL6, IL15, IL17, and IL23 Quantikine ELISA Kits).
Adverse events attributable to RTX were also recorded; they were classified as adverse events that occurred during RTX infusion or that appeared within the next 12 months after the RTC cycle and requiring hospitalization and/or intravenous antibiotics in case of infection.

1.1.2. Review of the literature. A throughout search in PubMed, Embase, Scopus, Web of Science, Asian Science Citration Index (ASCI), IranMedex, Scientific Information Database (SID), PaKMediNet, IndMed, and Index Medicus for the World Health Organization Eastern Mediterranean Region (IMEMR) regarding SSc patients treated with RTX up to June 2015 was done, using the key words scleroderma, systemic sclerosis, rituximab, and anti-CD20.

1.1.3. Statistical analysis. Statistical analysis was performed by means of univariate analysis of variance (ANOVA), Student's t-test, and Fisher's exact test. Values are given as mean±SD for normally distributed variables, or as median (range) for not normally distributed variables; P values ≤0.05 were considered statistically significant.

1.2. Results

Demographic and clinico-epidemiological features of 10 SSc patients treated along with the main indications to RTX therapy are shown in Tab. 1.Five patients presented limited cutaneous scleroderma with serum ACA, while the other five showed a diffuse cutaneous involvement with circulating anti Scl-70 in 4 and ANoA in one. The most frequent symptoms were arthritis (8 pts), lung fibrosis (9 pts) associated to PAH in 4; pruritus (7 pts), melanodermia (7 pts), skin ulcers (8 pts), calcinosis (6 pts), and dysphagia (5 pts). RTX treatment was decided because of the failure or low responsiveness to other previous combined treatments (Ca-channel blockers, iloprost, bosentan, hydroxychloroquine, leflunomide, and/or immunosuppressors). At baseline the patients showed a variable combination of SSc clinical manifestations; the main indications to RTX are shown in Tab. 1.
After 6 months from the first RTX cycle, the patients showed a clear-cut clinical improvement of both articular and skin SSc manifestations. In particular, the number

ACCEPTED MANUSCRIPT

of swollen and tender joints markedly reduced in 7/8 patients, as well as the patient's pain VAS that medially decreased 66±19.5 to 39±9.9 (p=0.017). At the end of follow-up, the clinical improvement of arthritis showed a complete remission in 6/7 and remained stable in 1/7.

Similarly, mRSS was significant lower after RTX (from 15.3±11.5 to 11±7.3; p=0.042); skin sclerosis improvement was particularly evident considering the five patients with diffuse cutaneous involvement (mRSS from 25±4.3 to 17.2±4.6; p =.022). At the end of follow-up, the extent of skin sclerosis in the five patients with diffuse cutaneous subset remained stable or showed a moderate progression in some individuals (19.6±7.1; Wilcoxon test: p=0.071; Fig. 1).

After RTX treatment the majority of subjects showed (Tab. 1) a clinical improvement of other cutaneous manifestations, such as hypermelanosis (7/7), pruritus (6/8), and calcinosis (3/6), with the exception of digital ulcers resulting scarcely responsive in all cases (6/6) (Tab. 1).

Similarly, other important SSc manifestations were poorly responsive to RTX treatment; in particular lung fibrosis detected in 8/10 remained stable in 6/8 and worsened in 2/8 at the end of follow-up (Tab. 1); moreover, three individuals (pts no. 1, 2, and 4) deceased because of PAH progression (Tab. 1).

As expected, the number of circulating B-lymphocytes significantly decreased in all patients after RTX treatment, while no variations of serum levels of immunoglobulins, autoantibodies, ESR, and C-reactive protein were observed.

Moreover, serum levels of pro-inflammatory cytokines, namely IL6, IL15, IL17, and IL23, measured at baseline in 3 patients with diffuse cutaneous SSc, were abnormally increased in all cases compared to the median values detectable in our healthy controls; these cytokines showed a more or less pronounced reduction after 6-month period from the first RTX cycle (Tab. 2).

With regards to the safety of RTX, only few and generally mild side-effects were recorded after treatment. In particular, infusion-related reactions were observed in 2/10 patients, i.e. hypotension, mild urticaria, and serum sickness-like reaction. Only one patient developed bacterial infection of the urinary tract that needed the hospitalization and intravenous antibiotics, with RTX cycle discontinuation.

1.2.1.Review of the literature. Available data from the world literature regarding the RTX treatment in SSc patients comprises 15 reports [17, 18, 20-32], which are carefully summarized in the Tab. 3. It includes 6 single case reports [17, 22, 24-26, 29] and 9 open-label, uncontrolled trials [18, 20, 21, 23, 27, 28, 30- 32]; these latter generally reported small patients' series (from 5 to 20 pts), with the exception of one multicentre study reporting the effects of RTX in a large series scleroderma patients [31]. The indications to RTX treatment were generally lung fibrosis and/or skin sclerosis, and less frequently severe calcinosis or arthritis (Tab. 3); while, the dosage and modalities of drug administration and the number of RTX cycles, as well as the duration of patient's clinical follow-up after RTX treatment largely varied among different studies (Tab. 3).

Following the first description of a patient with lung fibrosis improvement by McGonagle et al. in 2008 [17], the majority of studies focused on the significant reduction of skin sclerosis and/or improvement/stabilization of interstitial lung fibrosis after RTX treatment (Tab. 3).

The improvement of lung fibrosis was observed in one randomized controlled trial including a small series of SSc patients [23]; in addition, RTX was able to reduce

ACCEPTED MANUSCRIPT

the scores of skin sclerosis, even if cutaneous improvement was comparable to that observed in the control group of patients receiving standard treatment alone [23]. More recently, two studies reported the effects of RTX treatment in SSc patients showing a positive response of both cutaneous and pulmonary involvement [31, 32]. In particular, Bosello et al. demonstrated a clear-cut reduction of skin fibrosis and disease activity/severity indexes after RTX in the majority of patients unresponsive to recent treatment with cyclophosphamide [32]. Moreover, pulmonary function tests remained stable throughout the long-term clinical follow-up. The Authors hypothesized that these findings, especially the skin fibrosis improvement might be correlated to the significant decline in IL-6 serum levels after RTX treatment as observed in a previous study of the same group [20]. In a multicentre study by the European Scleroderma Trial and Research (EUSTAR) the efficacy and safety of RTX were analyzed in 63 patients using a nested case-control design [31]. The mRSS was available in 46 patients showed a significant reduction in the RTX-treated group compared to matched controls (N=25; -24.0±5.2% vs -7.7±4.3%; p=0.03). Moreover, in RTX-treated patients, the mean mRSS was significantly reduced at the follow-up compared with baseline (26.6±1.4 vs 20.3±1.8; p=0.0001). In addition, in a limited number of patients with documented interstitial lung disease, RTX was able to prevent a further decline of FVC compared with controls (N=9; 0.4±4.4% vs -7.7±3.6%; p=0.02). The safety measures showed a good profile of RTX in SSc patients consistent with previous studies in other autoimmune rheumatic diseases [31, 7-13].

Contrarily, Lafyatis et al. did not confirm the above positive results in a study evaluating the effects of a single RTX cycle in a series of 15 patients with diffuse cutaneous SSc; no significant variations of both cutaneous and lung involvement were observed, regardless the complete depletion after 6-months from RTX cycle of the modest B cell infiltrates present in most skin biopsies at baseline [18].

On the whole, these cohort studies demonstrated the frequent reduction of skin fibrosis as well as the improvement/stabilization of lung fibrosis after RTX, while data regarding the beneficial effects on other SSc manifestations such as calcinosis, arthritis, and skin ulcers remains still anecdotal.

1.3. Discussion

The results of the present study seem to confirm the clinical usefulness of RTX treatment in SSc patients, particularly for some disease manifestations. The B cell depletion was able to significantly improve the extension and severity of skin sclerosis, clearly evident in patients with diffuse cutaneous involvement; similarly, other skin manifestations, such as melanodermia, pruritus, and calcinosis ameliorated in the majority of individuals. Another valuable effect of RTX was the recovery of arthritis in 7/8 patients. Of interest, these positive effects were maintained for the entire long-term follow-up period. With regards to main visceral organ manifestations, lung and heart involvement revealed scarcely responsive at the first patient's evaluation but showed a valuable stabilization (lung) at the end of the follow-up; on the contrary, 3/4 patients with PAH and limited cutaneous SSc died because of the progression of lung vascular involvement regardless combined vasoactive drugs and RTX treatment.

In our experience, the most favorable results were mainly observed for skin and articular involvement; the improvement of skin sclerosis was clearly quantifiable in

ACCEPTED MANUSCRIPT

patients with diffuse cutaneous SSc subset, while arthritis ameliorated in the majority of cases regardless of cutaneous and serological disease subsets. In three subjects the improvement of some clinical SSc manifestations were mirrored by the reduction of serum levels of some cytokines potentially involved in the pathogenesis of the disease [20, 32, 33, 34, 35, 36].

The above findings are in some measure comparable with that emerging from the updated review of the world literature on the RTX treatment in SSc patients [17, 18, 20-32]. A limited number of open-label, uncontrolled trials are generally referred to small patients' series; while only one multicentre study evaluated the effects of RTX in a larger number of scleroderma patients [31]. Up to date, the observed variations of scleroderma clinical features represent only preliminary, encouraging suggestions of a possible role of RTX in the therapeutical strategies of SSc. The indications to RTX treatment were more frequently cutaneous, pulmonary involvement, and/or the failure of previous treatments [17, 18, 20-32]; while, the dosage and modalities of RTX administration, the number of cycles, as well as the duration of patient's clinical follow-up after treatment were considerably heterogeneous among different trials [17, 18, 20-32]. However, these studies generally suggested the efficacy of RTX in the treatment of skin sclerosis along with the possible improvement and/or stabilization of interstitial lung fibrosis, along with the good safety profile of this drug [17, 18, 20-32].
In particular, the EUSTAR multicentre study analyzed the efficacy and safety of RTX in a relatively large series of patients, showing that the drug was able to significantly improve the extent of skin sclerosis in patients with diffuse SSc subset; moreover, in individuals with interstitial lung disease RTX was able to prevent a further decline of FVC compared to controls [31]. The clinical usefulness was associated with elevated patients' compliance and safety of RTX treatment as previously observed in other autoimmune rheumatic disorders [7-13, 17, 18, 20-32]. Comparable results have been demonstrated in another recent trial [32] reporting a significant improvement of both skin sclerosis and other SSc activity/severity indexes after RTX cycles in patients unresponsive to recent treatment with cyclophosphamide. Moreover, lung involvement remained stable throughout the long-term clinical follow-up. The observed cutaneous and pulmonary improvement was mirrored by the significant reduction of circulating IL-6 levels after RTX treatment, suggesting a key role of this cytokine in the pathogenesis of the disease, especially with regards the severity of cutaneous involvement [20].

The therapeutical effects of RTX on some important SSc manifestations evidenced by different trials, including the present study, contrast with the results of a previously published report by Lafyatis et al. [18] evaluating a series of 15 patients with diffuse cutaneous SSc; these Authors did not find significant variations of both skin and lung involvement after a single RTX cycle [18].
Some discrepancies among different clinical studies are not surprising considering the etiopathogenetic complexity of SSc and other variables such as the patients' selection, disease duration at the time of the study, and associated treatments [17, 18, 20-32]. Moreover, the therapeutical specificity of RTX, able to down-regulate the B-cell function, might explain its positive effects on some particular SSc clinical symptoms, i.e. the reduction of skin sclerosis and the attenuation of lung fibrosis [17, 20-25, 27, 28, 30-32]. SSc is the result of a multifactorial and multistep process secondary to different causative and genetic predisposing factors; various

ACCEPTED MANUSCRIPT

pathogenetic processes, including endothelial cell impairment with diffuse microangiopathy, increased collagen deposition by altered fibroblasts, and T- and B-cell hyperactivity, may variably contribute to the wide spectrum of SSc clinical phenotypes [1-6]. In this context, anti-CD20 treatment could be included among different pathogenetic treatments of SSc according to specific therapeutic protocols. The main vascular manifestations of SSc, i.e. pulmonary arterial hypertension, renal crisis, and digital ulcers, must be primarily treated with vasoactive treatment [4-6]; while skin and internal organ involvement secondary to fibrotic and immune-mediated alterations may be responsive to anti-fibrotic/immunosuppressive drugs [4-6]. These different therapeutic approaches are not mutually exclusive due to the frequent coexistence of different pathogenetic processes in the same individual; they could be employed as combined/sequential treatments according to the prevalent pathogenetic alterations and symptom aggregations [4-6]. Because of the lack of well-defined predictive factors for the appearance of specific clinical manifestations, the effects of different therapies are unpredictable in the clinical practice, as well as often inadequate or transient [4-6]. Therefore, the therapeutical interventions should be started in the early phases of disease or directed to single organ involvement and always tailored in individual patient after a careful evaluation of the clinico-immunological SSc phenotype; in all cases, a tight monitoring of patients is necessary and when necessary a timely treatment remodulation.

If confirmed by further investigations in larger patients' series, anti-CD20 therapy could be included in the therapeutic armamentarium of scleroderma patients; it could be positioned among the first-line treatments of patients with diffuse skin sclerosis and mild-moderate visceral organ involvement [17, 20-25, 27, 28, 30-32], as well as in the presence of SSc-associated arthritis [32 and present series]. Even if in a limited number of patients the clear-cut improvement of SSc-related arthritis represents one of the most valuable effects of RTX treatment in our experience. Both cutaneous and joint involvement may be responsible for the severe disability that lastly affects a high percentage of scleroderma patients [37, 38]. In the presence of most severe manifestations, such as progressive interstitial lung fibrosis, RTX might be usefully employed as second-line treatment after an attempt with antifibrotic/immunosuppressive therapy.

Take-home messages.

- B-cell overexpression represents one of the most important pathogenetic mechanisms of SSc
- The usefulness of Rituximab on some SSc manifestations has been previously reported
- In our SSc pts, anti-CD20 therapy was able to improve both cutaneous and articular involvement.
- These findings are in keeping with the updated review of the world literature on this topic
- Rituximab represents a promising treatment of SSc skin sclerosis and arthritis, and possibly lung involvement

ACCEPTED MANUSCRIPT

References.

[1] LeRoy EC, Black C, Fleischmajer R, Jablonska S, Krieg T, Medsger Jr TA, et al. Scleroderma (systemic sclerosis): classification, subsets and pathogenesis. J Rheumatol 1988;15:202–5.

[2] Medsger Jr TA. Systemic sclerosis (scleroderma): clinical aspect. In: Koopman WJ, editor. Arthritis and allied conditions. A textbook of rheumatology Philadelphia: Williams & Wilkins 2005;1433–65.

[3] Ferri C, Valentini G, Cozzi F, Sebastiani M, Michelassi C, La Montagna G, et al. Systemic Sclerosis Study Group of the Italian Society of Rheumatology (SIR-GSSSc). Systemic sclerosis: demographic, clinical, and serologic features and survival in 1,012 Italian patients. Medicine (Baltimore) 2002;81(2):139-53.

[4] Denton CP, Black CM, Abraham DJ. Mechanisms and consequences of fibrosis in systemic sclerosis. Nat Clin Pract Rheumatol 2006;2:134-144.

[5] Ferri C, Sebastiani M, Lo Monaco A, Iudici M, Giuggioli D, Furini F, et al. Systemic sclerosis evolution of disease pathomorphosis and survival. Our experience on Italian patients' population and review of the literature. Autoimmun Rev 2014;13(10):1026-34.

[6] Nagaraja V, Denton CP, Khanna D. Old medications and new targeted therapies in systemic sclerosis. Rheumatology (Oxford) 2014. Jul 26. pii: keu285. [Epub ahead of print].

[7] Ferri C, Cacoub P, Mazzaro C, Roccatello D, Scaini P, Sebastiani M, et al. Treatment with rituximab in patients with mixed cryoglobulinemia syndrome: results of multicenter cohort study and review of the literature. Autoimmun Rev 2011;11(1):48-55.

[8] Visentini M, Tinelli C, Colantuono S, Monti M, Ludovisi S, Gragnani L, et al. Efficacy of low-dose rituximab for the treatment of mixed cryoglobulinemia vasculitis: Phase II clinical trial and systematic review. Autoimmun Rev 2015. May 29. pii: S1568-9972(15)00121-4. [Epub ahead of print]

[9] Giuggioli D, Manfredi A, Colaci M, Manzini CU, Antonelli A, Ferri C. Systemic sclerosis and cryoglobulinemia: our experience with overlapping syndrome of scleroderma and severe cryoglobulinemic vasculitis and review of the literature. Autoimmun Rev 2013;12(11):1058-63.

[10] Keystone EC, Cohen SB, Emery P, Kremer JM, Dougados M, Loveless JE, et al. Multiple courses of rituximab produce sustained clinical and radiographic efficacy and safety in patients with rheumatoid arthritis and an inadequate response to 1 or more tumor necrosis factor inhibitors: 5-year data from the REFLEX study. J Rheumatol 2012;39(12):2238-46.

[11] Erkan D, Aguiar CL, Andrade D, Cohen H, Cuadrado MJ, Danowski A, et al. 14th International Congress on Antiphospholipid Antibodies: task force report on antiphospholipid syndrome treatment trends. Autoimmun Rev 2014;13(6):685-96.

[12] Meijer JM, Pijpe J, Vissink A, Kallenberg CG, Bootsma H. Treatment of primary Sjogren syndrome with rituximab: extended follow-up, safety and efficacy of retreatment. Ann Rheum Dis 2009;68(2):284-5.

ACCEPTED MANUSCRIPT

[13] Tanaka Y, Takeuchi T, Miyasaka N, Sumida T, Mimori T, Koike T, et al. Efficacy and safety of rituximab in Japanese patients with systemic lupus erythematosus including lupus nephritis who are refractory to conventional therapy. Mod Rheumatol. 2015 Jun 9:1-27.

[14] Kamal A, Khamashta M. The efficacy of novel B cell biologics as the future of SLE treatment: a review. Autoimmun Rev 2014;13(11):1094-101.

[15] Sato S, Fujimoto M, Hasegawa M, Takehara K, Tedder TF. Altered B lymphocyte function induces systemic autoimmunity in systemic sclerosis. Mol Immunol 2004;41(12):1123-33.

[16] François A, Chatelus E, Wachsmann D, Sibilia J, Bahram S, Alsaleh G, et al. B lymphocytes and B-cell activating factor promote collagen and profibrotic markers expression by dermal fibroblasts in systemic sclerosis. Arthritis Res Ther 2013;15(5):R168.

[17] McGonagle D, Tan AL, Madden J, Rawstron AC, Rehman A, Emery P, et al. Successful treatment of resistant scleroderma-associated interstitial lung disease with rituximab. Rheumatology (Oxford) 2008;47(4):552-3.

[18] Lafyatis R, Kissin E, York M, Farina G, Viger K, Fritzler MJ, et al. B cell depletion with rituximab in patients with diffuse cutaneous systemic sclerosis. Arthritis Rheum 2009;60(2):578-83.

[19] van den Hoogen F, Khanna D, Fransen J, Johnson SR, Baron M, Tyndall A, et al. 2013 classification criteria for systemic sclerosis: an American college of rheumatology/European league against rheumatism collaborative initiative. Ann Rheum Dis 2013;72(11):1747-55.

[20] Bosello S, De Santis M, Lama G, Spanò C, Angelucci C, Tolusso B, et al. B cell depletion in diffuse progressive systemic sclerosis: safety, skin score modification and IL-6 modulation in an up to thirty-six months follow-up open-label trial. Arthritis Res Ther 2010;12(2):R54.

[21] Smith V, Van Praet JT, Vandooren B, Van der Cruyssen B, Naeyaert JM, Decuman S, et al. Rituximab in diffuse cutaneous systemic sclerosis: an open-label clinical and histopathological study. Ann Rheum Dis 2010;69(1):193-7.

[22] Daoussis D, Liossis SN, Tsamandas AC, Kalogeropoulou C, Kazantzi A, Korfiatis P, et al. Is there a role for B-cell depletion as therapy for scleroderma? A case report and review of the literature. Semi Arthritis Rheum 2010;40(2):127-36.

[23] Daoussis D, Liossis SN, Tsamandas AC, Kalogeropoulou C, Kazantzi A, Sirinian C, et al. Experience with rituximab in scleroderma: results from a 1-year, proof-of-principle study. Rheumatology (Oxford) 2010;49(2):271-80.

[24] Haroon M, McLaughlin P, Henry M, Harney S. Cyclophosphamide-refractory scleroderma-associated interstitial lung disease: remarkable clinical and radiological response to a single course of rituximab combined with high-dose corticosteroids. Ther Adv Respir Dis 2011;5(5):299-304.

[25] Yoo WH. Successful treatment of steroid and cyclophosphamide-resistant diffuse scleroderma-associated interstitial lung disease with rituximab. Rheumatol Int 2012;32(3):795-8.

[26] Daoussis D, Antonopoulos I, Liossis SN, Yiannopoulos G, Andonopoulos AP. Treatment of systemic sclerosis-associated calcinosis: a case report of rituximab-induced

ACCEPTED MANUSCRIPT

regression of CREST-related calcinosis and review of the literature. Semin Arthritis Rheum 2012;41(6):822-9.

[27] Daoussis D, Liossis SN, Tsamandas AC, Kalogeropoulou C, Paliogianni F, Sirinian C, et al. Effect of long-term treatment with rituximab on pulmonary function and skin fibrosis in patients with diffuse systemic sclerosis. Colin Exp Rheumatol 2012;30(2 Suppl 71):S17-22.

[28] Smith V, Piette Y, van Praet JT, Decuman S, Deschepper E, Elewaut D, et al. Two-year results of an open pilot study of a 2-treatment course with rituximab in patients with early systemic sclerosis with diffuse skin involvement. J Rheumatol 2013;40(1):52-7.

[29] de Paula DR, Klem FB, Lorencetti PG, Muller C, Azevedo VF. Rituximab-induced regression of CREST-related calcinosis. Clin Rheumatol 2013;32(2):281-3.

[30] Moazedi-Fuerst FC, Kielhauser SM, Brickmann K, Hermann J, Lutfi A, Meilinger M, et al. Rituximab for systemic sclerosis: arrest of pulmonary disease progression in five cases. Results of a lower dosage and shorter interval regimen. Scand J Rheumatol 2014;43(3):257-8.

[31] Jordan S, Distler JH, Maurer B, Huscher D, van Laar JM, Allanore Y, et al; EUSTAR Rituximab study group. Effects and safety of rituximab in systemic sclerosis: an analysis from the European Scleroderma Trial and Research (EUSTAR) group. Ann Rheum Dis 2015;74(6):1188-94.

[32] Bosello SL, De Luca G, Rucco M, Berardi G, Falcione M, Danza FM, et al. Long-term efficacy of B cell depletion therapy on lung and skin involvement in diffuse systemic sclerosis. Semin Arthritis Rheum 2015;44(4):428-36.

[33] Muangchant C, Pope JE. The significance of interleukin-6 and C-reactive protein in systemic sclerosis: a systematic literature review. Clin Exp Rheumatol 2013;31(2 Suppl 76):122-34.

[34] Wuttge DM, Wildt M, Geborek P, Wollheim FA, Scheja A, Åkesson A. Serum IL-15 in patients with early systemic sclerosis: a potential novel marker of lung disease. Arthritis Research & Therapy 2007;9:R85.

[35] Hemdan NY, Birkenmeier G, Wichmann G, Abu El-Saad AM, Krieger T, Conrad K, et al. Interleukin-17-producing T helper cells in autoimmunity. Autoimmun Rev 2010;9(11):785-92.

[36] Olewicz-Gawlik A, Danczak-Pazdrowska A, Kuznar-Kaminska B, Gornowicz-Porowska J, Katulska K, Trzybulska D, et al. Interleukin-17 and interleukin-23: importance in the pathogenesis of lung impairment in patients with systemic sclerosis. Int J Rheum Dis 2014;17(6):664-70.

[37] Fenoglio D, Bernuzzi F, Battaglia F, Parodi A, Kalli F, Negrini S, et al. Th17 and regulatory T lymphocytes in primary biliary cirrhosis and systemic sclerosis as models of autoimmune fibrotic diseases. Autoimmun Rev 2012;12(2):300-4.

[38] Bosello S, De Luca G, Tolusso B, Lama G, Angelucci C, Sica G, et al. B cells in systemic sclerosis: a possible target for therapy. Autoimmun Rev 2011;10(10):624-30.

ACCEPTED MANUSCRIPT

Legend to the Fig. 1.

Variations of modified Rodnan skin score (mRSS) after 6 months of the first rituximab cycle and at the end of long-term follow up (f.u.; mean 37±21SD months) in 10 scleroderma patients, 5 with limited (lcSSc) and 5 with diffuse cutaneous (dcSSc) subset. P values are referred to 5 patients with dcSSc.

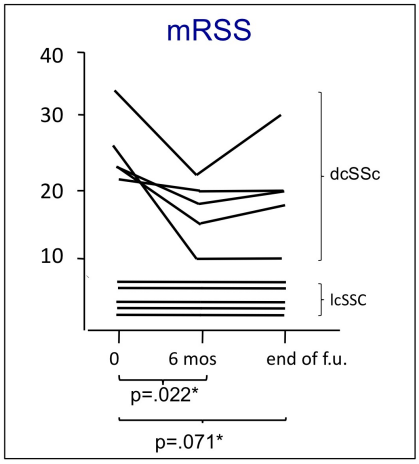

Tab. 1. Epidemiological and clinico-serological features of SSc patients before/after rituximab treatment.

Patients	1	2	3	4	5	6	7	8	9	10
Age/Sex	70/M	74/F	68/F	80/F	74/F	24/F	29/M	45/M	41/F	39/M
SSc dur. (yrs)	22	13	25	20	9	3	12	2	4	5
SSc cutaneous subset	Limited	Limited	Limited	Limited	Limited	Diffuse	Diffuse	Diffuse	Diffuse	Diffuse
Autoantibodies	ACA	ACA	ACA	ACA	ACA	ANoA	anti-Scl70	anti-Scl70	anti-Scl70	anti-Scl70
Indication to RTX	L, A	L, A, DU	L, C	L, A, C, DU	L, A, DU, C	A, DU, C, S	L, DU, C, S	L, A, S	L, A, S, DU	A, S
RTX cycles	5	2	2	2	3	1	5	2	4	2
Other therapies	B, Ccb, Cs	B, Ilo, Ccb, Cs	Ilo, Ccb, Cs	Ilo, Ccb, Cs	Ilo, Lef, Ccb, Cs	B, Ilo, Mmf, Ccb, Cs	B, Ilo, Mmf, Ccb, Cs	Ilo, Lef, Ccb, Cs	B, Ilo, Mmf, Ccb, Cs	B, Ilo, Ccb, Cs

ACCEPTED MANUSCRIPT

Follow-up (months)	72	72	30	18	30	18	48	18	36	24
Clinical features (baseline/6mth/end of follow-up)										
Skin										
mRSS	6/6/6	4/4/4	6/6/6	4/4/4	4/4/4	33/22/30	24/18/20	22/20/20	24/16/18	26/10/10
Digital ulcers°	-/-/-	+/+/+	-/-/-	+/+/+	+/+/+	+/+/+	+/+/+	-/-/-	+/+/+	-/-/-
Calcinosis (I/U/W)	-/-/-	-/-/-	+/u/u	+/u/u	+/u/u	+/i/i	+/i/i	-/-/-	+/i/i	-/-/-
Melanodermia	+/i/u	-/-/-	-/-/-	-/-/-	+/i/u	+/i/i	+/i/i	+/i/i	+/i/i	+/i/u
Pruritus	-/-/-	-/-/-	+/i/u	+/u/u	+/u/u	+/i/i	+/i/i	+/i/i	+/i/i	+/i/i
Lung^	+/u/u	+/u/u	+/u/u	+/u/u	+/u/u	-/u/u	+/u/w	-/-/-	+/u/w	+/u/u
Cardiovascular inv.										
LV involvement (ECHO)	+/u/u	+/u/u	-/-/-	+/u/w	-/-/-	-/-/-	-/-/-	-/-/-	-/-/-	-/-/-
PAH	+/u/w	+/u/w	+/u/u	+/u/w	-/-/-	-/-/-	-/-/-	-/-/-	-/-/-	-/-/-
Esophagous										
Dysphagia	+/u/u	-/u/u	+/u/u	-/u/u	-/-/-	+/u/u	+/u/u	-/-/-	+/u/u	-/-/-
Kidney	-/-/-	-/-/-	-/-/-	-/-/-	-/-/-	-/-/-	-/-/-	-/-/-	-/-/-	-/-/-
Arthritis	+/i/u	+/i/i	-/-/-	+/u/u	+/i/i	+/i/i	-/-/-	+/i/i	+/i/i	+/i/i
Cumulative results										
6 months	i (A)	i (A)	u	u	i (A)	i (A, C, S)	i (C, S)	i (A, S)	i (A, C, S)	i (A, S)
end of follow-up	u*	i (A)*	u	u*	i (A)	i (A, C, S)	i (C, S)	i (A, S)	i (A, C, S)	i (A, S)

°digital ulcers detectd at baseline in 6/6 pts were unresponsive to RTX needing in all cases of other systemic and local treatments;
^Interstitial lung involvement evaluated by means of HRCT, FVC, Dlco, and 6-minute walking test
L: lung; A: arthritis; DU: digital ulcers; C: calcinosis; S: skin involvement evaluated by modified Rodnan skin score (mRSS);
i/u/w: improved/unchanged/worsened; ECHO: ecocolorDoppler cardiography;
B: bosentan; Lef: leflunomide; Ilo: iloprost; Mmf: mycophenolate mofetil; Cs: corticosteroids; Ccb: calcium channel blokers
ACA: anticentromere; ANoA: antinucleolar; anti-Scll70: antitopoisomerase 1 antibodies
*deceased due to the progression of pulmonary arterial hypertension (PAH);

Tab. 2.

Serum levels of cytokines in 3 pts with diffuse cutaneous SSc before/after rituximab

Patient no.	**IL-6** range 0-12 pg/ml median 3.6*	**IL-15** range 0-8.68 pg/ml median 2.4*	**IL-17** range 0 – 252 pg/ml median 21*	**IL-23** range 0 – 645 pg/ml median 0*
	b / a	b / a	b / a	b / a

ACCEPTED MANUSCRIPT

6	98.2 / 62.5	17.4 / 12.4	30.4 / 14.8	7.9 / 1.4
8	35.4 / 20.7	11.8 / 10.1	26.8 / 22.7	6.3 / 6.1
9	101 / 44.5	89.9 / 36.5	70.5 / 41.9	10.1 / 4.8

SSc: systemic sclerosis; RTX: rituximab

*range and median values are referred to our healthy controls

b / a: before/after 6-month follow-up period from the first RTX (rituximab) cycle

Tab. 3. Systemic sclerosis (SSc) patients treated with Rituximab (RTX): review of the literature

		Treatment with RTX						
No.	Authors, year (ref. no.)	SSc Pts no.	Dosage each cycle	Cycles no.	Follow-up months°	Main indications*	Results	Skin biopsy before/after RTX	Adverse events serious-minor
1	**Mc Gonagle D, 2008**	1	RTX 1g/2wks for 2 times	2	nd	L	Improved lung inv. (FVC, DLCO, and fibrosis at HRCT)	nd	na
2	**Lafyatis R, 2009**	15	RTX 1g/2wks for 2 times	1	6-12	S, L	skin fibrosis and lung inv. remained stable.	reduction myofibroblast scores, depletion of dermal B cells 6 months after RTX cycle	prostate cancer (1 pt) possibly unrelated to RTX; infusion reactions 46.7% (pts not premedicated), mild hypotension (2 pts), flushing, fatigue, nausea/abdominal cramping, rigors, and hand tingling each (1 pts), urinary tract infection (1 pt), dental abscess (1 pt).
3	**Bosello S, 2010**	9	RTX 1g/2wks for 2 times	1	6-36	S, L	Improvement of mRSS and clinical	depletion of B-cell infiltrates (1	na

ACCEPTED MANUSCRIPT

							symptoms	pt)	
4	**Smith V, 2010**	8	RTX 1g/2wks for 2 times	1	24	S	significant improvement of mRSS	improvement of myofibroblasts and collagen; absence of B cells at baseline	Possibly unrelated to RTX: 1 pt underwent coronary artery bypass surger; 1 pt reported a 2-day lowgrade fever occurring 2 weeks after the second infusion.
5	**Daoussis D, 2010**	1	RTX 375mg/m^2/wk for 4 weeks	4	24	S, L	Improved lung and skin inv.	reduction of collagen and myofibroblast scores, and B-cell infiltrates	Severe respiratory tract infection with hospitalization 2 months after the third RTX course.
6	**Daoussis D, 2010**	14	8 pts were randomized to receive two cycles of RTX (375mg/m^2/wk for 4 weeks) compared to 6 pts as controls	2	12	S, L	Improved lung inv.	Improvement of fibrosis in the papillary dermis, reduction of collagen deposition and B-cell infiltrates	! pt was hospitalized for respiratory tract infection 3 months after the second cycle of RTX
7	**Haroon M, 2011**	1	RTX 1g/2wks for 2 times	1	12	L	Improved lung inv., disappearance of exertional dyspnoea	nd	na
8	**Yoo WH, 2012**	1	RTX 500mg/wk for 2 weeks	1		2L	Improved lung inv. (FVC, DLCO, and fibrosis at HRCT)	nd	na
9	**Daoussis D, 2012**	1	RTX 375mg/m2/wk for 4 weeks	2	24	C	Significant improvement of calcinosis	nd	na
10	**Daoussis D, 2012^**	8	RTX 375mg/m^2/wk for 4 weeks	4	24	S, L	Improvement of skin and lung inv.	Decrease in collagen accumulation, myofibroblast score and skin infiltrating B cells	Respiratory tract infection 3 mths after second RTX course (1 pt). Respiratory tract infection with associated leukopenia 2 mths after third RTX course, and

ACCEPTED MANUSCRIPT

									an H1N1 infection 5 mths after fourth RTX course (1 pt). Mild infusion reaction during the first RTX course (1 pt).
11	**Smith V, 2013**	8	RTX 1g/2wks for 2 times	2	24	S, L	Improvement of skin inv. and stabilization of internal organ status	reduction of collagen and myofibroblast scores, and B-cell infiltrates	Coronary arterial bypass grafting (1 pt), episode of noninfectious subfebrility (1pt), sepsis leading to death (1 pt), secondary infection of digital ulcer (1 pt), episode of hyperventilation (1)
12	**de Paula DR, 2013**	1	RTX 375mg/m^2/wk for 4 weeks	2	7	L, C	Complete resolution of calcinosis, improved dyspnea and synovitis	nd	na
13	**Moazedi-Fuerst FC, 2014**	5	RTX 500mg/wk for 2 weeks every 3 months for 1 year	4**	12	S, L	Improvement of skin and lung inv., healing of digital ulcers and capillaroscopic alterations	nd	na
14	**Jordan S et al.,2014**	46°	RTX 1g/2wks for 2 times (in the majority of cases)	1	7	S, L	Improvement of skin inv., and prevention of progression of lung fibrosis (n=9 pts)	nd	Absence of serious adverse events; cardiac/renal inv. and arrhythmia was reported in 1 pt each. Fatigue was noted in 14/56 (25%), infections in 11/53 (21%), nausea in 2/48 (4%) and rigour in 3/48 (6%). Serum sickness/hypersensitivity reaction was

ACCEPTED MANUSCRIPT

									observed in 2/54 (4%) pts.
15	**Bosello S, 2015**	20	RTX 1g/2wks for 2 times	1***	48,5±20,4	S, L, A	Improvement of both skin and lung inv., and arthritis in 5/5; prevention of lung fibrosis progression	nd	4 events (3 probably unrelated to RTX); 2 pts died: one pt with long dis dur due to heart failure 30 mths after last RTX infusion and 1 due to sudden death 39 mths after RTX. 1 pt developed herpes zoster infection 1 month after third course of RTX and 1 presented an occult breast cancer after 6 mths from RTX.
16	**present series**	10	RTX 375mg/m^2/wk for 4 weeks	1-5	37±21	S, L, A, DU	Improved mRSS in pts with diffuse cutaneous SSc, calcinosis, and arthritis	nd	infusion-related reactions in 2/10 pts (hypotension, mild urticaria , and serum sickness-like reaction). 1 pt developed infection of urinary tract needing hospitalization .

^extension of the study no. 6; ᶜfrom the first RTX cycle
*Involvement of: skin (S), lung(L), calcinosis (C); arthritis (A); digital ulcers (DU)
** RTX 500 mg time 0-14 every 3 months for 1 year
***8 pts were treated with two or more courses of RTX during the follow-up
ᶜmodified Rodnan skin score (mRSS) was available for statistical analysis in 46/63 enrolled patients
FU: follow up, RTX: Rituximab, wk: week, wks: weeks,

ACCEPTED MANUSCRIPT

FVC: forced vital capacity, DLCO: diffusing capacity of the lung for carbon monoxide
HRCT: High-resolution computed tomografhy
n: not done; na: not
available

ACCEPTED MANUSCRIPT