

This is the peer reviewed version of the following article:

Scleroderma skin ulcers definition, classification and treatment strategies our experience and review of the literature / Giuggioli, D.; Manfredi, A.; Lumetti, F.; Colaci, M.; Ferri, C.. - In: AUTOIMMUNITY REVIEWS. - ISSN 1568-9972. - 17:2(2018), pp. 155-164. [10.1016/j.autrev.2017.11.020]

*Terms of use:*

The terms and conditions for the reuse of this version of the manuscript are specified in the publishing policy. For all terms of use and more information see the publisher's website.

03/05/2026 04:05

(Article begins on next page)

## Accepted Manuscript

Scleroderma skin ulcers definition, classification and treatment strategies our experience and review of the literature

Dilia Giuggioli, Andreina Manfredi, Lumetti Federica, Colaci Michele, Clodoveo Ferri



PII: S1568-9972(17)30293-8  
DOI: doi:[10.1016/j.autrev.2017.11.020](https://doi.org/10.1016/j.autrev.2017.11.020)  
Reference: AUTREV 2099

To appear in:

Please cite this article as: Dilia Giuggioli, Andreina Manfredi, Lumetti Federica, Colaci Michele, Clodoveo Ferri , Scleroderma skin ulcers definition, classification and treatment strategies our experience and review of the literature. The address for the corresponding author was captured as affiliation for all authors. Please check if appropriate. Autrev(2017), doi:[10.1016/j.autrev.2017.11.020](https://doi.org/10.1016/j.autrev.2017.11.020)

This is a PDF file of an unedited manuscript that has been accepted for publication. As a service to our customers we are providing this early version of the manuscript. The manuscript will undergo copyediting, typesetting, and review of the resulting proof before it is published in its final form. Please note that during the production process errors may be discovered which could affect the content, and all legal disclaimers that apply to the journal pertain.

**Scleroderma skin ulcers**  
**Definition, classification and treatment strategies**  
**Our experience and review of the literature**

Dilia Giuggioli, MD, Andreina Manfredi, MD, Lumetti Federica, MD, Colaci Michele, MD,  
and Clodoveo Ferri, MD

*Chair and Rheumatology Unit, University of Modena and Reggio Emilia, Medical School,  
Azienda Ospedaliero-Universitaria, Policlinico di Modena, Modena, Italy.*

**Running title:**

Scleroderma skin ulcers

**Key words:**

systemic sclerosis, scleroderma, skin ulcers, digital ulcers, definition, classification,  
procedural pain, wound bed preparation, TIME, debridement.

Words count of the abstract: 405

Words count of the text: 4,081

*Corresponding author:*

Clodoveo Ferri, MD  
UOC di Reumatologia, Dpt of Internal Medicine,  
University of Modena and Reggio E.  
Azienda Ospedaliero-Universitaria  
Via del Pozzo, 71  
41100 Modena Italy  
Tel +39-059-4224053 Fax +39-059-4224178  
E-mail : clferri@unimore.it

**Abstract.**

**Background:** Skin ulcers (SU) are one of the most frequent manifestations of systemic sclerosis (SSc). SSc-SU are very painful, often persistent and recurrent; they may lead to marked impairment of patient's activities and quality of life. Despite their severe impact on the whole SSc patient's management, the proposed definition, classification criteria, and therapeutic strategies of SSc-SU are still controversial.

**Objective:** The present study aimed to elaborate a comprehensive proposal of definition, classification, and therapeutic strategy of SSc-SU on the basis of our long-term single center experience along with a careful revision of the world literature on the same topic.

**Methods:** A series of 282 SSc patients (254 females and 28 males; 84% with limited and 16% diffuse cutaneous SSc; mean age of  $51.5 \pm 13.9$ SD at SSc onset; mean follow-up  $5.8 \pm 4.6$ SD years) enrolled during the last decade at our Rheumatology Unit were retrospectively evaluated with specific attention to SSc-SU. The SSc-SU were classified in 5 subtypes according to prominent pathogenetic mechanism(s) and localization, namely 1. digital ulcers (DU) of the hands or feet, 2. SU on bony prominence, 3. SU on calcinosis, 4. SU of lower limbs, and 5. DU presenting with gangrene. This latter is a very harmful evolution of both DU of the hands and feet needing a differential diagnosis with critical limb ischemia.

**Results:** During the follow up period, one or more episodes of SSc-SU were recorded in over half patients (156/282, 55%); skin lesions were often recurrent and difficult-to-heal because of local complications, mainly infections (67.3%), in some cases associated to osteomyelitis (19.2%), gangrene (16%), and/or amputation (11.5%). SSc-SU were significantly associated with lower patients' mean age at the disease onset ( $p=.024$ ), male gender ( $p=.03$ ), diffuse cutaneous subset ( $p=.015$ ), calcinosis ( $p=.002$ ), telangiectasia ( $p=.008$ ), melanoderma ( $p<.001$ ), abnormal PAPs ( $p=.036$ ), and/or altered inflammation reactant (CRP,  $p=.001$ ).

Therapeutic strategy of SSc-SU included both systemic and local pharmacological treatments with particular attention to complicating infections and chronic/procedural pain, as well as a number of non-pharmacological measures. Integrated local treatments were often decisive for the SSc-SU healing; they were mainly based on the wound bed preparation principles that are summarized in the acronym TIME (necrotic Tissue, Infection/Inflammation, Moisture balance, and Epithelization).

The updated review of the literature focusing on this challenging issue was analyzed in comparison with our experience.

**Conclusions:** The recent advancement of knowledge and management strategies of SSc-SU achieved during the last years lead to the clear-cut improvement of patients' quality of life and reduced long-term disability.

## 1. Introduction

Systemic Sclerosis (SSc) is a connective tissue disease, characterized by diffuse microangiopathy, collagen hyperproduction by altered fibroblasts with fibrosis of the skin and internal organs, and multiple immune system alterations (1-3). The pathogenetic role of microvascular involvement seems to be crucial as suggested by the natural course of the disease; actually, various vasculopathic manifestations characterize the SSc since its prodromic phases: Raynaud's phenomenon almost invariably precedes the SSc clinical onset (1-3), while scleroderma renal crisis and pulmonary arterial hypertension are among the most harmful scleroderma complications, finally scleroderma skin ulcers (SSc-SU) are commonly recorded in up-to 50% of patients (1-3). SSc-SU represent a burdensome, very painful, often persistent and recurrent SSc complication (4-8); they may lead to marked limitations in everyday personal and occupational activities with deleterious impact on the patients' quality of life (5). In some individuals, SSc-SU may be complicated by infections and severe gangrene needing amputation (5, 9). Despite their severe clinical impact on the whole patient's managing, the proposed definition/classification criteria and therapeutic guidelines of SSc-SU are still controversial (4-7, 10-15). The present study aimed to draw up a proposal of definition, classification, and therapeutic strategy of SSc-SU on the basis of our long-term single center experience along with a thorough revision of the world literature on this debated issue.

## 2. Patients and Methods

We retrospectively evaluated the epidemiological and clinico-serological data derived from our SSc patients' population enrolled during the last decade at our University-based Rheumatology Unit (282 patients; 254F, 28M) and classified according to ACR/EULAR criteria (16). All SSc patients were routinely evaluated at baseline and at least every 6 months with regards to both cutaneous and visceral organ involvement according to previously reported methodologies (1, 17); clinico-serological and instrumental data, as well as ongoing therapies were regularly reported in clinical records, together with unplanned visits due to the appearance/worsening of clinical symptoms, including SSc-SU that were regularly assessed according to the following criteria.

### 2.1. SU definition/classification.

The Tab. 1 shows our proposal of definition and classification of SSc-SU; the classification is mainly based on the different localization of cutaneous lesions, likely due to different pathogenetic mechanisms. According to the definition currently used in the wound care field (18), chronic (lasting >6 weeks) cutaneous ulcers complicating the SSc can be defined as '*loss of*

substance involving epidermis, basement membrane, and dermis; the latter can be variably involved, considering that the more severe lesions may affect deeper skin layers, i.e. subcutaneous tissue, muscle, ligament, and bone' (Fig. 1). The SSc-SU encompass all cutaneous ulcerative lesions, while the term digital ulcers (DU) refers to lesions localized to fingertips, toe tips, and/or close to the nails. Overall, SSc-SU more frequently develop at the acral zones of the hands and feet; they may be multiple, recurrent, and/or relapsing. Therefore, SSc-SU can be classified as: 1. DU of the hands and DU of the feet, 2. SU on bony prominence, 3. SU on calcinosis, 4. SU of lower limbs, and 5. SU or DU presenting with gangrene (Tab. 1; Fig 2). Several cutaneous lesions, generally characterized by surface loss of substance, can be frequently observed in scleroderma patients, namely *abrasions and fissures, as well as digital pitting scars and sub-ungual hyperkeratosis*; these manifestations are inconsistent with diagnosis of true SSc-SU (14; Fig. 1-2).

## 2.2. Treatment.

The treatment schedule of SSc-SU was individually tailored according to the patient's clinical conditions and the severity of cutaneous lesion(s), including its possible complications (infection, osteomyelitis, and gangrene) (5, 19). In the presence of multiple SU, the characteristics of each lesion were carefully evaluated. In all cases the therapeutic strategy of SSc-SU was based on systemic and local pharmacological treatments, including analgesia for both chronic and procedural pain, as well as on non-pharmacological measures (Fig. 3, Tab. 2).

### 2.2.1. systemic treatment.

Systemic therapy was individually decided by evaluating the severity/activity of the whole SSc. Patients with mild-moderate manifestations, including sporadic ulcerative manifestations, underwent long-term treatment with a combination of vasodilators, i.e. calcium-channel blockers, prostanoids, phosphodiesterase type 5 (PDE-5) inhibitors, and/or endothelin receptor antagonists (ERA), and low-dose aspirin; while cycles of immunosuppressant/immunomodulators (cyclophosphamide, mycophenolate, or rituximab) were employed in the presence of more severe SSc manifestations such as interstitial lung fibrosis or progressive cutaneous involvement; specific treatments were necessarily used in patients with pulmonary arterial hypertension (20-24) (Fig. 3, Tab. 2). Treatment strategy was invariably tailored on the single patient in close collaboration with other specialists, mainly pneumologists and cardiologists. Moreover, in patients with very difficult to heal or recurrent, severe SU an attempt with growth factors such as granulocyte-colony stimulating factor (GCSF) and/or erythropoietin (EPO) was carried out (25, 26) (Fig. 3, Tab. 2).

### 2.2.2. *local treatment.*

Besides local analgesia necessary for procedural pain due to local SU debridement, local non-pharmacological treatment was regularly performed according to wound bed preparation (WBP) procedures: a complex of multistep operations based on the notion that the efficacy of evaluation and treatment of chronic wounds requires holistic care by multidisciplinary approach (27-28). In the last years we have gradually adapted these knowledge to the specific features and difficulties of SSc-SU. The main principles of WBP are summarized in the acronym TIME (Fig. 3-4; Fig. 3, Tab. 2), recalling to the most important aspects of ulcer evaluation and management: necrotic tissue, infection/inflammation, moisture balance, and epithelization, in order to accelerate the spontaneous SU healing and to facilitate the effectiveness of systemic and local therapeutic measures (27-28).

More in detail the TIME includes (Fig. 4):

**T is for necrotic tissue:** altered cells and bacterial load represent a strong obstacle to the healing process, thus their removal by means of debridement *is crucial*. Necrotic tissues frequently overshadow the underlying wound bed for a careful assessment, while bacteria compete for scarce local resources necessary for wound healing such as nutritional factors. Different kind of debridement can be performed: chemical, autolytic, mechanical (less selective), biological, and sharp/surgical. We usually employed the sharp debridement because it is the most selective.

**I is for infection and inflammation:** chronic wounds always contain bacteria ranging from contamination, colonization to invasive infection (9, 19, 27-28).

The infection complicating the SU is clinically diagnosed by the presence of lesion redness, warmth of the skin surrounding the wound, edema, worsening pain and tenderness, foul smell, and/or purulent drainage. The SU infection should be confirmed by laboratory investigations; considering the difficulties of the tissue biopsy, an adequate deep wound swab may be sufficient. Wound debridement reducing the bacterial burden, including the biofilm, is mandatory. Moreover, the presence of underlying osteomyelitis requires extended systemic antibiotic and surgical management.

**-M is for moisture balance:** the moisture balance is useful to control of the wound and surrounding area; correct moisture balance has been proven to accelerate wound healing in terms of re-epithelization, granulation tissue formation, and prevention of surrounding skin maceration, without increasing the infection rate. In clinical practice this balance is favored by the use of the wide array of “advanced” moisture retentive dressing (occlusive, semioclusive, absorptive, and hydrating dressing) according to the moisture status of the wound bed.

-E is for epithelization: wound healing can be defined in the case of complete progression of the edges and wound contraction. Otherwise, in the case of discontinuation of healing process, every step of the TIME procedure should be re-considered.

**Advanced dressings.** Besides the above TIME procedures, we invariably utilize the active dressing; it is often required to obtain the best results of local treatment. The active, advanced dressing encompasses a number of medications that actively interact with the wound tissues developing cellular matrix and promoting the entire healing process (29, 30; Tab. 2). The most used products were alginate (non-woven absorbent fiber derived from different types of algae and seaweeds), hydrocolloid (wafer type of self-adhering dressing containing gel-forming agents in an adhesive compound laminated onto a flexible, water-resistant outer layer), hydrofiber (soft, sterile, non-woven pad or ribbon dressing composed of sodium carboxymethylcellulose), hydrogel (water based-gel wafer able to promote moist environment and removal of necrotic tissue through autolytic debridement), and polyurethane foam or film (open-cell hydrophilic polyurethane foam sheets, permeable to gas and water vapor, with an hydrophobic surface) (29, 30; Tab. 2).

#### 2.2.3. Regenerative medicine.

The treatment of most severe, non-healing SSc-SU may be integrated by special local treatments such as homologous platelet gel (PG), autologous and allogeneic skin grafting, as previously reported (31-33).

Recently we treated long lasting and poorly responsive to traditional therapy SSc- DU by implantation of autologous adipose tissue-derived cell fractions to accelerate wound healing. (34, 35) (Tab. 2).

2.2.4. **Pain management.** Analgesia is mandatory for both background and procedural pain during local debridement of SU (8, 29, 36; Fig. 3; Tab. 2). Long-lasting chronic pain is responsible of decreased patients' quality of life; while procedural pain weakens the patient's compliance during local treatment, which may result impracticable in more severe lesions. When required, patients with SSc-SU are treated for background chronic pain with long-lasting analgesic treatment, usually opioids, according to pain severity evaluated, for instance, by means of numeric rating scale (range 0-10). Procedural pain needs to be managed with timely escalation of analgesic therapy during DU debridement according to patient's pain rating at the beginning of medication and during ensuing debridement steps (8).

#### 2.2.5. Non pharmacological measures.

A correct education of all SSc patients for an appropriate life-style is particularly advisable, with specific instructions for individuals with severe Raynaud's phenomenon and/or complicating SSc-SU (37). Therefore, all SSc patients should be recommended to wear a hat, mittens or gloves, scarf, coat with snug cuffs, and warm socks and shoes during cold weather; moreover, to use hand and foot warmers in mittens, boots, socks, or pockets, warm up car before driving in cold weather, wear gloves or mittens when taking food out of the refrigerator or freezer. In general, it is also important to learn handling anxiety, when present, by mean of physical activity, yoga, tai chi, or meditation. Considering that some drugs can trigger Raynaud's attacks, it is necessary to avoid medicines that contain ergotamine, appetite suppressants, beta-blockers, and hormonal contraceptives; in addition, all patients were strongly advised to stop smoking (29, 30, 37, 38; Fig. 3; Tab. 2).

For a correct management of SSc patients, an individually tailored rehabilitation and/or occupational therapy programs was also included when opportune. These physical therapies were selected on the bases of prevalent clinical manifestation(s), considering the impact on the patient's quality of life.

### 2.3. Review of the literature.

A throughout search in PubMed, Embase, Scopus, Web of Science, Asian Science Citration Index (ASCI), IranMedex, Scientific Information, Database (SID), PaKMediNet, IndMed, and Index Medicus for the World Health Organization Eastern Mediterranean Region (IMEMR) regarding SSc patients with SU/DU was done up to June 2017, using the key words scleroderma, systemic sclerosis, skin ulcers, digital ulcers, skin lesions.

### 2.4. Statistical analysis.

Data were expressed as mean±standard deviation (SD) unless otherwise noted. Categorical variables were analyzed by Fisher's exact test, while differences between the means were determined using the Mann–Whitney U-test for unpaired samples. p values  $\leq 0.05$  were considered statistically significant.

The data processing was performed using the statistical software GraphPad Prism 5.5 for Windows.

## 3. Results

The main epidemiological and clinical features of our SSc patients series evaluated in the present study are shown in the Tab. 3; it includes 282 individuals (254 females and 28 males) with a mean age of  $51.5\pm 13.9$ SD at SSc onset and  $54.6\pm 13.5$ SD years and at the beginning of

follow-up, respectively. The patients were followed for a mean period of  $5.8 \pm 4.6$ SD years; at the first visit the disease duration was  $3.1 \pm 5.7$ SD years, while Raynaud's phenomenon duration before disease onset was  $6.4 \pm 11$ SD years. With regards to cutaneous subset classification, 84% SSc patients showed limited cutaneous SSc, while 16% had diffuse cutaneous involvement. The detection of anti-topoisomerase antibodies (Scl-70) was positive in 33% of patients, anticentromere antibodies (ACA) in 45%, and antinucleolar antibodies (ANoA) in 16%. During the follow-up period abnormally increased values of erythrocyte sedimentation rate (ESR) were recorded in 30% of SSc patients, while 21% showed altered C reactive protein (CRP). Moreover, the prevalence of SSc manifestations were: Raynaud's phenomenon 90% of patients, melanoderma 39%, telangiectasia 65%, calcinosis 13%, sicca syndrome 46%, lung fibrosis 48%, and abnormally high pulmonary arterial pressure (PAPs) as derived at echocardiography 14%. While renal involvement was recorded in a limited number of patients (7%), in only 4 as typical scleroderma renal crisis. Finally, smoking habit was observed in 32% of patients (Tab. 3).

The occurrence of at least one episode of SU was recorded in 156 of the whole SSc series (55%). The comparison between patients with and without SU revealed that cutaneous lesions were significantly more frequent in male than female patients ( $p=.03$ ); moreover, patients with SU showed a medially lower age at SSc onset ( $p=.024$ ) compared to those without, as well as higher percentages of diffuse cutaneous subset, calcinosis, telangiectasia, and melanoderma ( $p=.015$ ,  $=.002$ ,  $p=.008$ , and  $<.001$ , respectively). Abnormally increased values of derived PAPs ( $>40$  mmHg), and CRP were significantly more frequent in SSc patients complicated by SU ( $p=.036$ , and  $.011$ , respectively) (Tab 3).

Of interest, one or more episodes of SU complicated by local infection were observed in 105/156 (67.3%) patients with SSc-SU, in some cases associated to osteomyelitis, gangrene, and/or amputation (Tab. 4). The involved infectious agents were Staphylococcus Aureus in 46.6% of cases, fecal pathogens (E. coli, E. faecalis) in 29.3%, Pseudomonas Aeruginosa in 13.2%, others 10.9%. The occurrence of osteomyelitis was observed in 19.2% of patients with SSc-SU, gangrene in 16%, while digital amputations were necessary in 11.5%; of note, these harmful complications presence of osteomyelitis were exclusively found in patients with DU of the hands or feet (Tab. 4).

One third of SSc patients developed two or more types of SU during the course of the disease, often as concomitant lesions.

The analysis of SSc-SU variants evidenced that 140 patients developed at least one episode of DU of the hands, alone or in concomitancy with other types of SU; DU of the hands were the most frequent SSc-SU (140/282, 49.6%), showing some interesting correlations with other SSc clinico-serological features (Tab. 3). Other SSc-SU variants were less frequently observed during

the patients' follow-up; they were characterized by some significant correlations with SSc features. In particular, DU of the feet (52/282, 18.4%) were more frequently observed in males ( $p=0.026$ ) and correlated with longer follow-up ( $p=.003$ ), presence of calcinosis ( $p=.002$ ), telangiectasia ( $p<.001$ ), and increased value of ESR and CRP ( $p=.015$  and  $p<.001$ , respectively); SU on bony prominence (38/282, 13.5%) correlated with diffuse cutaneous SSc subset ( $p=.006$ ), telangiectasia ( $p=.02$ ), and serum positivity for anti-topoisomerase autoantibodies ( $p<.001$ ), while an inverse correlation was observed with ACA positivity ( $p=.012$ ); SU on calcinosis (36/282, 12.7%) showed significant lower mean age at SSc onset and a longer SSc duration ( $p=.029$  and  $p=.037$ , respectively). Finally, SU of the lower limbs (30/282, 10.6%) correlated with increased values of ESR and CRP ( $p=.002$ ;  $p<.001$ ; respectively).

All SSc patients underwent systemic therapy (Tab. 2; Fig. 3) with at least two drugs; namely, calcium channel blockers (86%), acetylsalicylic acid (75%), prostanoids (75%), steroids (66%), bosentan (25%), and/or immunomodulators/immunosuppressants (anti-CD20 monoclonal antibodies, mycophenolate mophetyl, cyclophosphamide) (33%). These latter were employed in patients with severe/active cutaneous and/or visceral organ involvement, mainly interstitial lung involvement, for one or more cycles. In some cases the concomitancy of non-healing, recurrent SU was also considered in the therapeutical decisions.

With regards the SU complicating over half of our SSc patients, the systemic and local treatment was invariably adjusted according to the patients' general conditions, including the concomitant comorbidities; in particular, local management of SU was decided from time to time considering the objective characteristics of each lesion (Fig. 2-3; Tab. 2).

### 3.1. Review of the literature

The high number of studies published during the last years on SSc-SU assessment and management indicates the growing interest on this issue, considering the negative impact of SSc-SU on the whole disease outcome. Tab. 5 summarizes the main publications in the world literature regarding the SSc-SU; they represent a heterogeneous body of clinical studies on patients' series of largely variable dimensions dealing with various aspects of SSc-SU (4-7, 10-12, 13-15, 20, 21, 39-54). Several studies focusing on distinctive features of SSc-SU spectrum referred to mono- or multicenter unselected patients series or to specific patients' populations included in therapeutical trials. The large majority of authors focused on the DU that represent the most common complication of SSc skin involvement, including consensus/registry studies; in other instances on the clinical status at the time of ulcer assessment (active or not) or on the evolutionary pattern of SSc-SU (episodic or recurrent) (4, 10, 40, 43-45, 49, 50).

The comparison between the previously and more recently published studies revealed a progressive accuracy and uniformity in the proposed definition and classification criteria of SSc-SU. A number of specific issues relative to previously published studies on SSc-SU are addressed in the following paragraph.

#### **4. Discussion.**

The present proposal of definition, classification criteria, and treatment strategies of SSc-SU is the result of our long-term experience in this challenging scleroderma manifestation in the light of the growing knowledge on the same topic as evidenced by the review of the world literature.

The analysis of our patients' series enrolled during the last decade evidenced one or more episodes of SSc-SU in over half individuals. Skin lesions were often recurrent and difficult-to-heal because of local complications, mainly infections; the latter were observed in over two third of individuals and were often responsible for more severe complications, namely osteomyelitis, gangrene, and/or amputation. The development of SSc-SU was significantly associated with lower patients' mean age at the disease onset, male gender, diffuse cutaneous subset, calcinosis, telangiectasia, melanoderma, abnormal PAPs, and/or altered inflammation reactant (CRP). The SSc-SU were classified in distinct clinical variants according to prominent etiopathogenetic mechanism(s) and localization, namely DU of hands or feet, bone prominence, calcinosis, and lower limbs; two or more variants can be often concomitant in the same individual, in some cases complicated by gangrene. This is a very harmful evolution of both DU of the hands and feet needing a differential diagnosis with critical limb ischemia (37, 55). Overall, SSc-SU subtypes showed some significant correlations with specific clinico-serological features, mainly lower patient's age at disease onset, diffuse cutaneous scleroderma, and/or serum anti-Scl70 autoantibodies, likely related to different underlying pathogenetic mechanisms.

The treatment strategy based on combined systemic and advanced local treatments, regularly adopted during the last decade, is clearly more effective if compared with those observed previously in term of the patients' quality of life and disability. Overall retrospective evaluation indicates a clear reduction of either the healing time of single lesion and the incidence of severe complications (gangrene, amputation) in recently referred patients possibly due to the progressive improvement of both systemic and local treatments.

An increasing number of clinical reports focused on clinical correlation between skin ulcers and other scleroderma manifestations with the purpose of better define the burden and the

distinctive features of different SSc-SU variants (Tab. 5). Our definition and classification criteria are quite concordant with those emerging from the analysis of more recent studies reported in the literature (14, 20, 47, 50, 52-54). In the past years some important differences were recognizable among different Authors, particularly with regards to the definition of 'skin ulcer'; the lack of agreement among clinicians was clearly evidenced in a web-based study reporting high intra-rater reliability in grading images of SSc digital lesions [10]. The frequent limitations and discrepancies among definition and classification proposals are shown in details in Table 5.

In a controlled and randomized study (44), the DU was defined as a 'loss of surface epithelization without including fissures or cracks in the skin'; similarly, other Authors defined DU as an 'area of loss of surface epithelization affecting the digital pulp or bony prominence, not including fissures or areas of calcium extrusions' (40). In other reports the definition of DU was totally lacking or simply identified as 'loss of skin epithelization' (Tab. 1).

While in a recent study DU was properly defined as 'denuded area of tissue with well-demarcated borders involving loss of both the dermis and epidermis' (47). Nowadays there is a general agreement to define SU as skin lesion involving epidermal covering, basement membrane, dermis, and possibly *deeper skin layers*. Skin lesions detected on the bony prominence such as the volar surface of proximal interphalangeal, metacarpal joints, and/or elbows can be categorized as distinct SSc-SU more likely secondary to concurrent ischemic and traumatic mechanisms (47). Comparable considerations can be deserved for SSc-SU complicating the skin areas above subcutaneous calcinosis (13, 15). Finally, there was a general agreement to avoid a number of minor skin lesions, i.e. *abrasions, fissures, scars, digital pitting scars, and subungual hyperkeratosis, inconsistent with diagnosis of SSc-SU* (14).

A number of studies focused on scleroderma DU of the hands without any concern for DU of the feet and lower limbs that may also represent a relevant cause of morbidity in SSc patients (56, 57). In particular, DU of the feet may recognize the same SSc-related microangiopathy responsible for DU of the hands, with a variable contribution of regional macrovascular involvement; while combined arterial-venous angiopathy can be the major cause of SU of lower limbs.

Gangrene is one of the most challenging SSc complications that may be observed in a minority of patients. It may be the evolution of severe, non-healing DU of the hands or feet, or in some cases as presenting symptom at the patient's referral; this troublesome condition may need a differential diagnosis between critical ischemia of the acral districts and typical

microangiopathic SSc-SU complicated by gangrene. The careful classification of these distinct conditions may be crucial for timely adequate treatment, considering also the possible concomitancy of both micro- and macroangiopathy in some cases.

A shared SSc-SU definition/classification is critical for both clinico-pathogenetic studies and therapeutic trials; therefore, the present proposal remains totally open to further improvement and revision possibly by expert consensus study.

Overall, SSc-SU are often associated with more severe disease course due to internal organ complications; they may contribute to progressive deterioration of the patient's general conditions and in some cases to worse disease outcome (17, 58). Skin lesions, mainly the DU, are frequently very painful, leading to severe reduction the patient's quality of life and relevant disability; SSc-SU are among other symptoms, i.e. dyspnea, pain, muscle weakness, and dysphagia, that SSc patients perceive as the main factors affecting their level of disability (59).

Therefore, a correct treatment strategy of SSc-SU may be as relevant as that adopted for other major organ involvement; in addition, the SSc-SU treatment should be correctly combined with the whole disease management. The management of SSc encompasses a complex of therapeutical measures, including both systemic and local, pharmacological and non-pharmacological treatments (22). The pharmacological therapies include both pathogenetic and symptomatic treatments, namely immunosuppressor/immunomodulators, antifibrotics, corticosteroids, plasmapheresis, phototherapy, anti-inflammatory, vasoactive, and analgesic drugs (Tab. 2; 22, 60, 61). Almost all the above therapies may be potentially useful on SSc-SU, particularly vasoactive drugs such as calcium channel blockers, prostanoids, ERA, and PDE-5 inhibitors, (22). In more severe, non-healing SSc-SU the use of more innovative treatments were employed with some benefit in small patients' series, namely grow factors, i.e. GCSF and EPO, *PG, autologous and allogeneic skin grafting*. However, the local treatment employing the more advanced measures, particularly the wound bed preparation procedures and advanced dressing (27, 29), plays a decisive role in the majority of SSc-SU.

Recently published studies focusing on SSc treatment strategy are quite concordant as regards the importance of a multidisciplinary approach for both SSc-SU and other major organ involvement (20, 22). In this respect, it is recommendable to tailor the whole therapy to each patient; moreover, the patient's education may be decisive for the adherence and efficacy of treatments, including an adequate analgesia for both chronic and procedural pain mainly due

to skin ulcers (8, 20, 37). The usefulness of pharmacological, pathogenetic and symptomatic, and non-pharmacological treatments (20, 22), as well as some precautionary measures and a proper life-style such as avoiding cold or smoke, may be important to prevent and treat the scleroderma skin lesions (20, 22, 37).

In conclusion, the progressive improvement of both systemic and advanced local treatments lead to an appreciable reduction of either the healing time of SSc-SU and the incidence of severe complications (infections, gangrene, amputation) in recently referred patients. Overall, the treatment strategy developed during the last decade represents a clear-cut advancement in term of improved patients' quality of life and reduced long-term disability (59). Clearly, the continuing refinement of SSc-SU definition and classification criteria is the precondition for suitable pathogenetic studies and therapeutical trials.

## 5. References

- [1] Ferri C, Valentini G, Cozzi F, Sebastiani M, Michelassi C, La Montagna G, Bullo A, Cazzato M, Tirri E, Storino F, Giuggioli D, Cuomo G, Rosada M, Bombardieri S, Todesco S, Tirri G; Systemic Sclerosis Study Group of the Italian Society of Rheumatology (SIR-GSSSc). Systemic sclerosis: demographic, clinical, and serologic features and survival in 1,012 Italian patients. *Medicine* 2002;81:139-53.
- [2] Steen VD. The many faces of scleroderma. *Rheum Dis Clin North Am* 2008;34:1-15.
- [3] Denton CP, Khanna D. Systemic sclerosis. *Lancet* 2017;S0140-6736:30933-9.
- [4] Matucci-Cerinic M, Krieg T, Guillevin L, Schwierin B, Rosenberg D, Cornelisse P, Cornelisse P, Denton CP. Elucidating the burden of recurrent and chronic digital ulcers in systemic sclerosis: long-term results from the DUO Registry. *Ann Rheum Dis* 2016;75:1770-6.
- [5] Guillevin L, Hunsche E, Denton CP, Krieg T, Schwierin B, Rosenberg D, Matucci-Cerinic M; DUO Registry Group. Functional impairment of systemic sclerosis patients with digital ulcerations: results from the DUO Registry. *Clin Exp Rheumatol*. 2013;31(2 Suppl 76):71-80.
- [6] Steen V, Denton CP, Pope JE, Matucci-Cerinic M. Digital ulcers: overt vascular disease in systemic sclerosis. *Rheumatology* 2009;48 Suppl 3:19-24.
- [7] Amanzi L, Braschi F, Fiori G, Galluccio F, Miniati I, Guiducci S, Conforti ML, Kaloudi O, Nacci F, Sacu O, Candelieri A, Pignone A, Rasero L, Conforti D, Matucci-Cerinic M. Digital ulcers in scleroderma: staging, characteristics and sub-setting through observation of 1614 digital lesions. *Rheumatology* 2010;49:1374-82.
- [8] Giuggioli D, Manfredi A, Vacchi C, Sebastiani M, Spinella A, Ferri C. Procedural pain management in the treatment of scleroderma digital ulcers. *Clin Exp Rheumatol* 2015;33:5-10.
- [9] Giuggioli D, Manfredi A, Colaci M, Lumetti F, Ferri C. Scleroderma digital ulcers complicated by infection with fecal pathogens. *Arthritis Care Res* 2012;64:295-7.
- [10] Herrick AL, Roberts C, Tracey A, Silman A, Anderson M, Goodfield M, Goodfield M, McHugh N, Muir L, Denton CP. Lack of agreement between rheumatologists in defining digital ulceration in systemic sclerosis. *Arthritis Rheum* 2009;60:878-82.
- [11] Hammers LK, Wigley FM. Management of Raynaud's phenomenon and digital ischemic lesions in scleroderma. *Rheum Dis Clin North Am* 2003;29:293-313.
- [12] Korn JH, Mayes M, Matucci Cerinic M, Rainisio M, Pope J, Hachulla E, Rich E, Carpentier P, Molitor J, Seibold JR, Hsu V, Guillevin L, Chatterjee S, Peter HH, Coppock J, Herrick A, Merkel PA, Simms R, Denton CP, Furst D, Nguyen N, Gaitonde M, Black C. Digital ulcers in systemic sclerosis: prevention by treatment with bosentan, an oral endothelin receptor antagonist. *Arthritis Rheum* 2004;50:3985-93.
- [13] Valenzuela A, Baron M; Canadian Scleroderma Research Group, Herrick AL, Proudman S, Stevens W; Australian Scleroderma Interest Group, Rodriguez-Reyna TS, Vacca A, Medsger TA Jr, Hinchcliff M, Hsu V, Wu JY, Fiorentino D, Chung L.

Calcinosis is associated with digital ulcers and osteoporosis in patients with systemic sclerosis: A Scleroderma Clinical Trials Consortium study. *Semin Arthritis Rheum* 2016;46:344-349.

[14] Suliman YA, Bruni C, Johnson SR, Praino E, Alemam M, Borazan N, Cometi L, Myers B, Khanna D, Allanore Y, Baron M, Krieg T, Herrick A, Afonso A, Distler O, Kafaja S, Denton CP, Matucci-Cerinic M, Furst DE. Defining skin ulcers in systemic sclerosis: systematic literature review and proposed World Scleroderma Foundation (WSF) definition. *J Scleroderma Relat Disord* 2017;2:115-120.

[15] Baron M, Pope J, Robinson D, Jones N, Khalidi N, Docherty P, Kaminska E, Masetto A, Sutton E, Mathieu JP, Ligier S, Grodzicky T, LeClercq S, Thorne C, Gyger G, Smith D, Fortin PR, Larché M, Abu-Hakima M, Rodriguez-Reyna TS, Cabral-Castaneda AR, Fritzler MJ, Wang M, Hudson M. Calcinosis is associated with digital ischaemia in systemic sclerosis—a longitudinal study. *Rheumatology* 2016;55:2148-2155.

[16] van den Hoogen F, Khanna D, Fransen J, Johnson SR, Baron M, Tyndall A, Matucci-Cerinic M, Naden RP, Medsger TA Jr, Carreira PE, Riemekasten G, Clements PJ, Denton CP, Distler O, Allanore Y, Furst DE, Gabrielli A, Mayes MD, van Laar JM, Seibold JR, Czirjak L, Steen VD, Inanc M, Kowal-Bielecka O, Müller-Ladner U, Valentini G, Veale DJ, Vonk MC, Walker UA, Chung L, Collier DH, Ellen Csuka M, Fessler BJ, Guiducci S, Herrick A, Hsu VM, Jimenez S, Kahaleh B, Merkel PA, Sierakowski S, Silver RM, Simms RW, Varga J, Pope JE. 2013 classification criteria for systemic sclerosis: an American College of Rheumatology/European League against Rheumatism collaborative initiative. *Arthritis Rheum* 2013;65:2737-47.

[17] Ferri C, Sebastiani M, Lo Monaco A, Iudici M, Giuggioli D, Furini F, Manfredi A, Cuomo G, Spinella A, Colaci M, Govoni M, Valentini G. Systemic sclerosis evolution of disease pathomorphosis and survival. Our experience on Italian patients' population and review of the literature. *Autoimmun Rev* 2014;13:1026–34.

[18] Burgdorf W, Plewig G, Wolff H.H, Landthaler M (Eds). *Braun-Falco's Dermatology*. 3th ed. Springer-Verlag Berlin Heidelberg; 2009.

[19] Giuggioli D, Manfredi A, Colaci M, Lumetti F, Ferri C. Osteomyelitis complicating scleroderma digital ulcers. *Clin Rheumatol* 2013;32:623-7.

[20] Denton CP, Hughes M, Gak N, Vila J, Buch MH, Chakravarty K, Fligelstone K, Gompels LL, Griffiths B, Herrick AL, Pang J, Parker L, Redmond A, van Laar J, Warburton L, Ong VH; BSR and BHRP Standards, Guidelines and Audit Working Group. BSR and BHRP guideline for the treatment of systemic sclerosis. *Rheumatology (Oxford)* 2016;55:1906-10.

[21] Moinzadeh P, Riemekasten G, Siegert E, Fierlbeck G, Henes J, Blank N, Melchers I, Müller-Ladner U, Frerix M, Kreuter A, Tigges C, Lahner N, Susok L, Guenther C, Zeidler G, Pfeiffer C, Worm M, Karrer S, Aberer E, Bretterkieber A, Genth E, Simon JC, Distler JH, Hein R, Schneider M, Seitz CS, Herink C, Steinbrink K, Sárdy M, Varga R, Mensing H, Mensing C, Lehmann P, Neeck G, Fiehn C, Weber M, Goebeler M, Burkhardt H, Buslau M, Ahmadi-Simab K, Himsel A, Juche A, Koetter I, Kuhn A, Sticherling M, Hellmich M, Kuhr K, Krieg T, Ehrchen J, Sunderkoetter C, Hunzelmann N; German Network for Systemic Scleroderma.. Therapeutic Practice in More Than 3000 Patients. *J Rheumatol* 2016;43:66-74.

[22] Kowal-Bielecka O, Fransen J, Avouac J, Becker M, Kulak A, Allanore Y, Distler O, Clements P, Cutolo M, Czirjak L, Damjanov N, Del Galdo F, Denton CP, Distler JHW, Foeldvari I, Fligelstone K, Frerix M, Furst DE, Guiducci S, Hunzelmann N, Khanna D, Matucci-Cerinic M, Herrick AL, van den Hoogen F, van Laar JM, Riemekasten G, Silver R, Smith V, Sulli A, Tarner I, Tyndall A, Welling J, Wigley F, Valentini G, Walker UA, Zulian F, Müller-Ladner U; EUSTAR Coauthors.. Update of

EULAR recommendations for the treatment of systemic sclerosis. *Ann Rheum Dis* 2017;76:1327-1339.

[23] Herrick AL, Pan X, Peytrignet S, Lunt M, Hesselstrand R, Mouthon L, Silman A, Brown E, Czirják L, Distler JHW, Distler O, Fligelstone K, Gregory WJ, Ochiel R, Vonk M, Ancuța C, Ong VH, Farge D, Hudson M, Matucci-Cerinic M, Balbir-Gurman A, Midtvedt Ø, Jordan AC, Jobanputra P, Stevens W, Moinzadeh P, Hall FC, Agard C, Anderson ME, Diot E, Madhok R, Akil M, Buch MH, Chung L, Damjanov N, Gunawardena H, Lanyon P, Ahmad Y, Chakravarty K, Jacobsen S, MacGregor AJ, McHugh N, Müller-Ladner U, Riemekasten G, Becker M, Roddy J, Carreira PE, Fauchais AL, Hachulla E, Hamilton J, İnanç M, McLaren JS, van Laar JM, Pathare S, Proudman S, Rudin A, Sahhar J, Coppere B, Serratrice C, Sheeran T, Veale DJ, Grange C, Trad GS, Denton CP. Treatment outcome in early diffuse cutaneous systemic sclerosis: the European Scleroderma Observational Study (ESOS). *Ann Rheum Dis* 2017;76:1207-1218.

[24] Pellar RE, Pope JE. Evidence-based management of systemic sclerosis: Navigating recommendations and guidelines. *Semin Arthritis Rheum* 2017; 6:767-774.

[25] Giuggioli D, Magistro R, Colaci M, Franciosi U, Caruso A, Ferri C. The treatment of skin ulcers in systemic sclerosis: use of granulocyte-colony stimulating factor (G-CSF) in 26 patients. *Reumatismo* 2006;58:26-30.

[26] Ferri C, Giuggioli D, Manfredi A, Quirici N, Scavullo C, Colaci M, Gianelli U, Deliliers GL, Del Papa N. Recombinant human erythropoietin stimulates vasculogenesis and wound healing in a patient with systemic sclerosis complicated by severe skin ulcers. *Clin Exp Dermatol* 2010;35:885-7.

[27] Schultz GS, Sibbald RG, Falanga V, Ayello EA, Dowsett C, Harding K, Harding K, Romanelli M, Stacey MC, Teot L, Vanscheidt W. Wound bed preparation: a systematic approach to wound management. *Wound Repair Regen* 2003;11:1-28.

[28] Leaper D, Schultz G, Carville K, Fletcher J, Swanson T, Drake R. Extending the TIME concept: what have we learned in the past 10 years? *International Wound Journal* 2012;9(Suppl 2):1-19.

[29] Boateng J, Catanzano O. Advanced Therapeutic Dressings for Effective Wound Healing--A Review. *J Pharm Sci* 2015;104:3653-80.

[30] World Union of Wound Healing Societies (WUWHS). Advances in wound care: the Triangle of Wound Assessment Wounds International. Florence Congress. Position Document;2016.

[31] Giuggioli D, Colaci M, Manfredi A, Mariano M, Ferri C. Platelet gel in the treatment of severe scleroderma skin ulcers. *Rheumatol Int* 2012;32:2929-32.

[32] Giuggioli D, Sebastiani M, Cazzato M, Piaggese A, Abatangelo G, Ferri C. Autologous skin grafting in the treatment of severe scleroderma cutaneous ulcers: a case report. *Rheumatology* 2003;42:694-6.

[33] Barsotti S, Mattaliano V, d'Ascanio A, Mosti G, Della Rossa A, Mattaliano C, Giuggioli D, Giraldi E, Ferri C, Mosca M. Systemic sclerosis chronic ulcers: preliminary results of treatment with allogenic skin grafting in a cohort of Italian patients. *Int Wound J* 2016;13:1050-1.

[34] Del Papa N, Di Luca G, Sambataro D, Zaccara E, Maglione W, Gabrielli A, Fraticelli P, Moroncini G, Beretta L, Santaniello A, Sambataro G, Ferraresi R, Vitali C.. Regional implantation of autologous

adipose tissue-derived cells induces a prompt healing of long-lasting indolent digital ulcers in patients with systemic sclerosis. *Cell Transplant* 2015;24:2297-305.

[35] Daumas A, Magalon J, Jouve E, Truillet R, Casanova D, Giraudo L, Veran J, Benyamine A, Dignat-George F, Magalon G, Sabatier F, Granel B.. Long-term follow-up after autologous adipose derived stromal vascular fraction injection into fingers in systemic sclerosis patients. *Curr Res Transl Med*. 2017;65:40-43.

[36] Giuggioli D, Manfredi A, Colaci M, Ferri C. Oxycodone in the long-term treatment of chronic pain related to scleroderma skin ulcers. *Pain Med* 2010;11:1500-3.

[37] Herrick AL. Recent advances in the pathogenesis and management of Raynaud's phenomenon and digital ulcers. *Curr Opin Rheumatol* 2016;28:577-85.

[38] Willems LM, Vriezেকolk JE, Schouffoer AA, Poole JL, Stamm TA, Boström C, Kwakkenbos L, Vliet Vlieland TP, van den Ende CH. Effectiveness of Nonpharmacologic Interventions in Systemic Sclerosis: A Systematic Review. *Arthritis Care Res (Hoboken)* 2015;67:1426-39.

[39] Chung L, Fiorentino D. Digital ulcers in patients with systemic sclerosis. *Autoimmun Rev* 2006;5:125-8.

[40] Nihtyanova SI, Brough GM, Black CM, Denton CP. Clinical burden of digital vasculopathy in limited and diffuse systemic sclerosis. *Ann Rheum Dis* 2008;67:120–3.

[41] Sunderkötter C, Herrgott I, Brückner C, Moinzadeh P, Pfeiffer C, Gerss J, Hunzelmann N, Böhm M, Krieg T, Müller-Ladner U, Genth E, Schulze-Lohoff E, Meurer M, Melchers I, Riemekasten G; DNSS Centers.. Comparison of patients with and without digital ulcers in systemic sclerosis:detection of possible risk factors. *Br J Dermatol* 2009;160:835-43.

[42] Alivernini S, De Santis M, Tolusso B, Mannocci A, Bosello SL, Peluso G, Pinnelli M, D'Antona G, La Torre G, Ferraccioli G.. Skin ulcers in systemic sclerosis: determinants of presence and predictive factors of healing. *J Am Acad Dermatol* 2009;60:426-35.

[43] Khimdas S, Harding S, Bonner A, Zummer B, Baron M, Pope J; Canadian Scleroderma Research Group. Associations with digital ulcers in a large cohort of systemic sclerosis: results from the Canadian Scleroderma Research Group registry. *Arthritis Care Res* 2011;63:142-9.

[44] Matucci-Cerinic M, Denton CP, Furst DE, Mayes MD, Hsu VM, Carpentier P, Wigley FM, Black CM, Fessler BJ, Merkel PA, Pope JE, Sweiss NJ, Doyle MK, Hellmich B, Medsger TA Jr, Morganti A, Kramer F, Korn JH, Seibold JR. Bosentan treatment of digital ulcers related to systemic sclerosis: results from the RAPIDS-2 randomised, double-blind, placebo-controlled trial. *Ann Rheum Dis* 2011;70:32-8.

[45] Baron M, Chung L, Gyger G, Hummers L, Khanna D, Mayes MD, Pope JE, Shah AA, Steen VD, Steele R, Tatibouet S, Herrick A, Müller-Ladner U, Hudson M.. Consensus opinion of a North American Working Group regarding the classification of digital ulcers in systemic sclerosis. *Clin Rheumatol* 2014;33:207-14.

[46] Moran ME. Scleroderma and evidence based non-pharmaceutical treatment modalities for digital ulcers: a systematic review. *J Wound Care* 2014;23:510-6.

- [47] Abraham S, Steen V. Optimal management of digital ulcers in systemic sclerosis. *Ther Clin Risk Manag* 2015;11:939-47.
- [48] Hachulla E, Hatron PY, Carpentier P, Agard C, Chatelus E, Jego P, Mouthon L, Queyrel V, Fauchais AL, Michon-Pasturel U, Jaussaud R, Mathian A, Granel B, Diot E, Farge-Bancel D, Mekinian A, Avouac J, Desmurs-Clavel H, Clerson P; SEDUCE study group.. Efficacy of sildenafil on ischaemic digital ulcer healing in systemic sclerosis: the placebo-controlled SEDUCE study. *Ann Rheum Dis* 2016;75:1009-15.
- [49] Khanna D, Denton CP, Merkel PA, Krieg T, Le Brun FO, Marr A, Papadakis K, Pope J, Matucci-Cerinic M, Furst DE; DUAL-1 Investigators; DUAL-2 Investigators. . Effect of macitentan on the development of new ischemic digital ulcers in patients with systemic sclerosis: DUAL-1 and DUAL-2 randomized clinical trials. *JAMA* 2016; 315:1975-88.
- [50] Hunzelmann N, Riemekasten G, Becker MO, Moinzadeh P, Kreuter A, Melchers I, Mueller-Ladner U, Meier F, Worm M, Lee H, Herrgott I, Pfeiffer C, Fierlbeck G, Henes J, Juche A, Zeidler G, Mensing H, Günther C, Sárdy M, Burkhardt H, Koehm M, Kuhr K, Krieg T, Sunderkötter C.. The Predict Study: low risk for digital ulcer development in patients with systemicsclerosis with increasing disease duration and lack of topoisomerase-1antibodies. *Br J Dermatol* 2016;174:1384-7.
- [51] Ahrens HC, Siegert E, Tomsitz D, Mattat K, March C, Worm M, Riemekasten G. Digital ulcers score: a scoring system to assess digital ulcers in patients suffering from systemic sclerosis. *Clin Exp Rheumatol* 2016;34 Suppl 100:142-147.
- [52] Morrisroe K, Frech T, Schniering J, Maurer B, Nikpour M. Systemic sclerosis: The need for structured care. *Best Pract Res Clin Rheumatol* 2016;30:3-21.
- [53] Souza EJR, Muller CS, Horimoto A, Rezende RA, Guimarães I, Mariz HA, Dantas AT, Da Costa IP, Del-Rio A, Sekiyama J, Kahwage CB, Kayser C. Geographic variation as a risk factor for digital ulcers in systemic sclerosis patients: a multicentre registry. *Scand J Rheumatol* 2016;20:1-8.
- [54] Cutolo M, Herrick AL, Distler O, Becker MO, Beltran E, Carpentier P, Ferri C, Inanç M, Vlachoyiannopoulos P, Chadha-Boreham H, Cottreel E, Pfister T, Rosenberg D, Torres JV, Smith V; CAP Study Investigators.. Nailfold Videocapillaroscopic Features and Other Clinical Risk Factors for Digital Ulcers in Systemic Sclerosis: A Multicenter, Prospective Cohort Study. *Arthritis Rheumatol* 2016;68:2527-39.
- [55] Sharp CA, Akram Q, Hughes M, Muir L, Herrick L. Differential diagnosis of critical digital ischemia in systemic sclerosis: Report of five cases and review of the literature. *Semin Arthritis Rheum.* 2016;46:209-16
- [56] Sari-Kouzel H, Hutchinson CE, Middleton A, Webb F, Moore T, Griffin K, Herrick AL.. Foot problems in patients with systemic sclerosis. *Rheumatology* 2001;40:410-3.
- [57] Blagojevic J, Piemonte G, Benelli L, Braschi F, Fiori G, Bartoli F, Guiducci S, Bellando Randone S, Galluccio F, Cometi L, Castellani S, Boddi M, Moggi Pignone A, Rasero L, Epifani F, Matucci-Cerinic M. Assessment, Definition, and Classification of Lower Limb Ulcers in Systemic Sclerosis: A Challenge for the Rheumatologist. *J Rheumatol.* 2016;43:592-8.
- [58] Tolosa-Vilella C, Morera-Morales ML, Simeón-Aznar CP, Marí-Alfonso B, Colunga-Arguelles D,

Callejas Rubio JL, Rubio-Rivas M, Freire-Dapena M, Guillén-Del Castillo A, Iniesta-Arandia N, Castillo-Palma MJ, Egurbide-Arberas M, Trapiella-Martínez L, Vargas-Hitos JA, Todolí-Parra JA, Rodríguez-Carballeira M, Marin-Ballvé A, Pla-Salas X, Rios-Blanco JJ, Fonollosa-Pla V; RESCLE Investigators, Autoimmune Diseases Study Group (GEAS). Digital ulcers and cutaneous subsets of systemic sclerosis: Clinical, immunological, nailfold capillaroscopy, and survival differences in the Spanish RESCLE Registry. *Semin Arthritis Rheum*. 2016;46:200-8.

[59] Jaeger VK, Distler O, Maurer B, Czirják L, Lóránd V, Valentini G, Vettori S, Del Galdo F, Abignano G, Denton C, Nihtyanova S, Allanore Y, Avouac J, Riemekasten G, Siegert E, Huscher D, Matucci-Cerinic M, Guiducci S, Frerix M, Tarnier IH<sup>12</sup>, Garay Toth B, Fankhauser B, Umbricht J, Zakharova A, Mihai C, Cozzi F, Yavuz S, Hunzelmann N, Rednic S, Vacca A, Schmeiser T, Riccieri V, García de la Peña Lefebvre P, Gabrielli A, Krummel-Lorenz B, Martinovic D, Ancuta C, Smith V, Müller-Ladner U, Walker UA. Functional disability and its predictors in systemic sclerosis: a study from the DeSSciper project within the EUSTAR group. *Rheumatology* 2017;in press.

[60] Cozzi F, Marson P. Plasma-exchange in the treatment of systemic rheumatic diseases: past and present experience. *Reumatismo*. 2009;61:161-4.

[61] Chaowattanapanit S, Choonhakarn C, Foocharoen C, Julanon N. Phototherapy in systemic sclerosis: review. *Photodermatol Photoimmunol Photomed*. 2017;in press.

## 6. Legend to the Figures.

### Fig. 1. Schematic representation of skin lesions in SSc patients (see also Tab. 1).

Patients with SSc may develop a variety of cutaneous lesions: the break of basement membrane with more or less pronounced dermis involvement can represent the pathological distinctive feature of true skin ulcers (SU).

According to the definition currently used in the wound care field, chronic (lasting >6 weeks) SU complicating the SSc can be defined as *'loss of substance involving epidermis, basement membrane, and dermis; the latter can be variably involved, considering that the more severe lesions may affect deeper skin layers, i.e. subcutaneous tissue, muscle, ligament, and bone'* (right: in red SU with different depth levels).

Several cutaneous lesions, generally characterized by surface loss of substance, can be frequently observed in scleroderma patients, namely abrasions and fissures, as well as digital pitting scars and sub-ungual hyperkeratosis; these manifestations are inconsistent with diagnosis of true SSc-SU (left).

### Fig. 2. Different subtypes of scleroderma skin ulcers (SSc-SU) according to proposed definition and classification criteria (see text, Tab. 1, and Fig. 1).

Digital ulcers (DU) of the hands or feet are the most frequent wound skin lesions of SSc; they may be complicated by gangrene. DU with gangrene represent a very challenging condition that may be observed in a minority of patients with severe, non-healing DU of the hands or feet, or in some cases as presenting symptom at the patient's referral. This latter occurrence needs a differential diagnosis with critical ischemia of the acral districts considering its relevant therapeutical implications (see text). Some scleroderma skin lesions inconsistent with the diagnosis of SU/DU are shown in the bottom of the figure.

SU: skin ulcer; DU: digital ulcer; SU on calcinosis: the arrows point small solid calcium lumps.

### Fig. 3. Therapeutic strategies of scleroderma skin ulcers (SSc-SU).

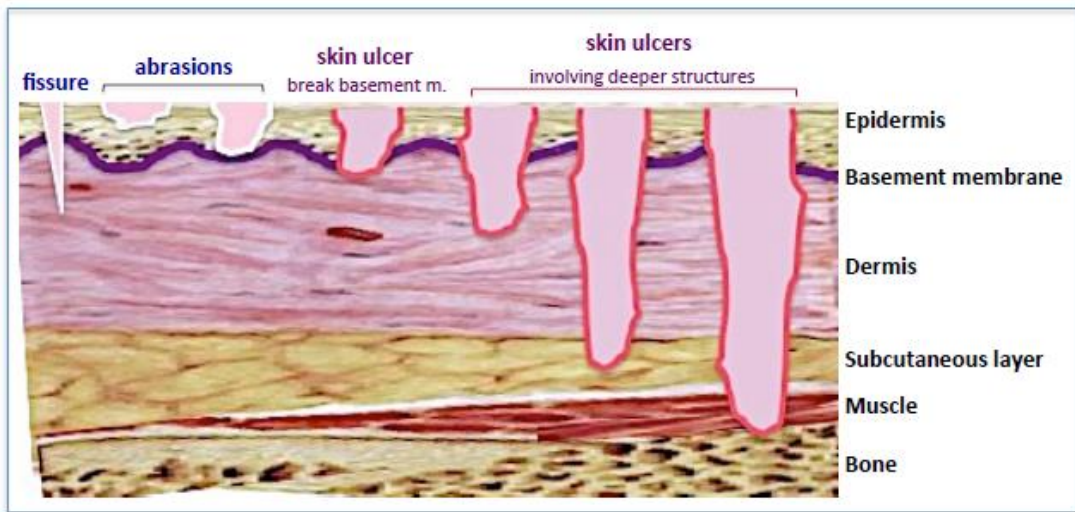
The therapeutic approach of SSc-SU should be invariably tailored to individual patient on the basis of both general clinical conditions and careful evaluation of single skin wound. In particular, a correct therapeutical strategy should always be preceded by the evaluation of the activity/severity of each SSc-SU, the presence of possible often subclinical local complications (infections, osteomyelitis, gangrene), and/or comorbidities (district macrovascular

involvement, diabetes, and other systemic disorders). Systemic and local treatments encompass both pathogenetic and symptomatic drugs, as well as different non-pharmacological measures. Noteworthy, chronic and procedural pain treatments using systemic and local analgesics are invariably required (see text; tab. 2). Wound bed preparation according to TIME procedures and advanced dressing are described in details in the text and Tab. 4.

**Fig. 4. Wound bed preparation according to the TIME procedures.**

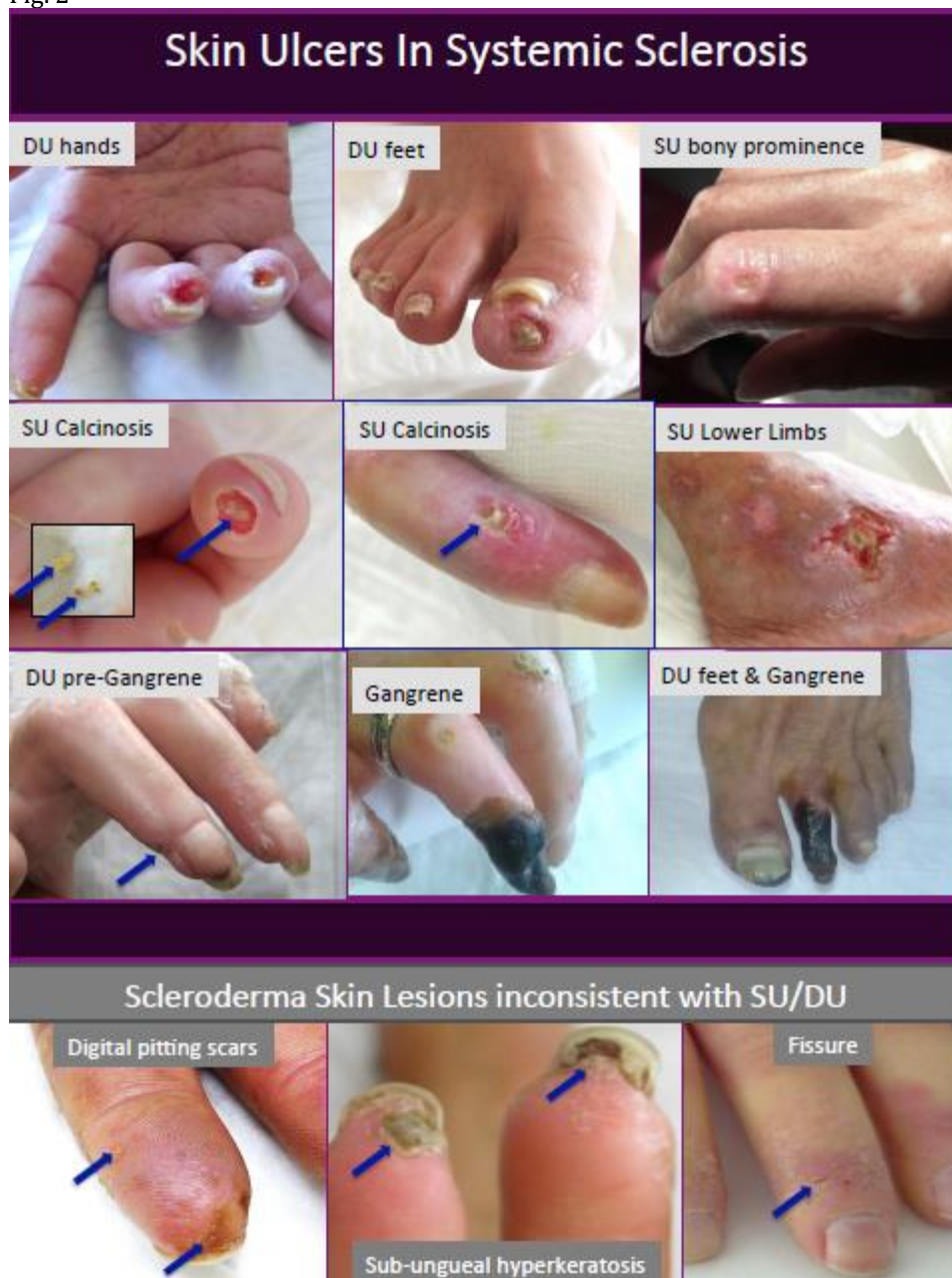The figure shows in details the local treatment flowcharts of SSc-SU according to the wound bed preparation by TIME procedures that are also described in the text.

Fig. 1



ACCEPTED MANUSCRIPT

Fig. 2



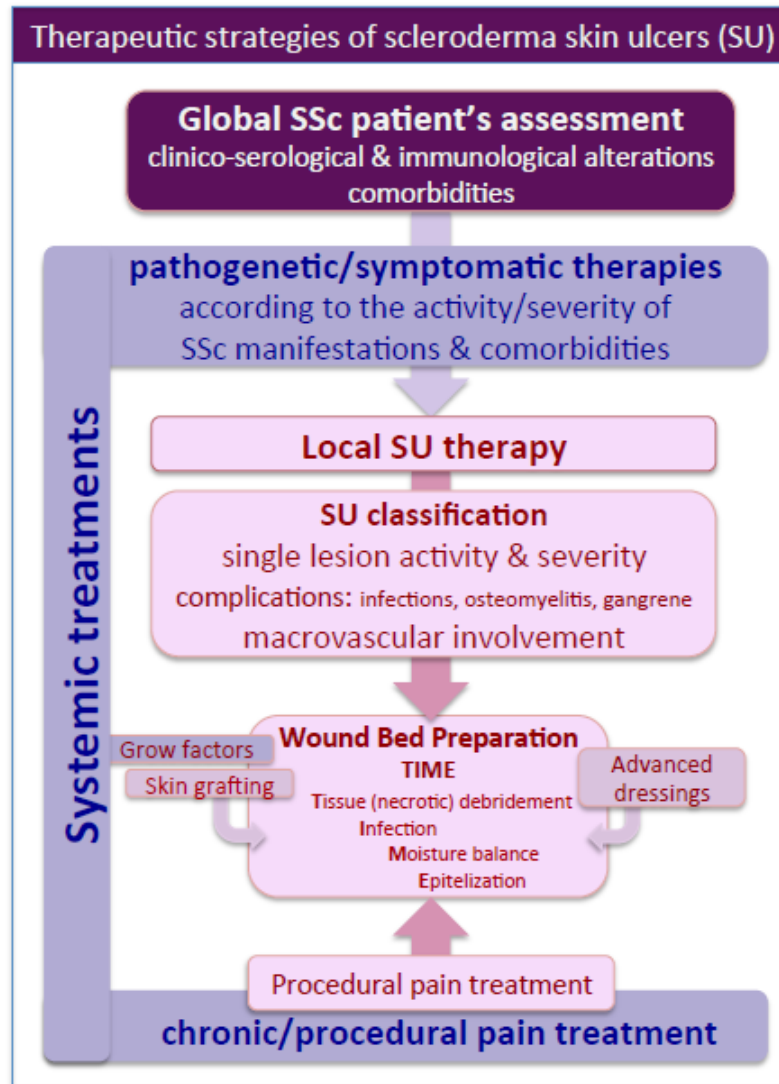


Fig. 3

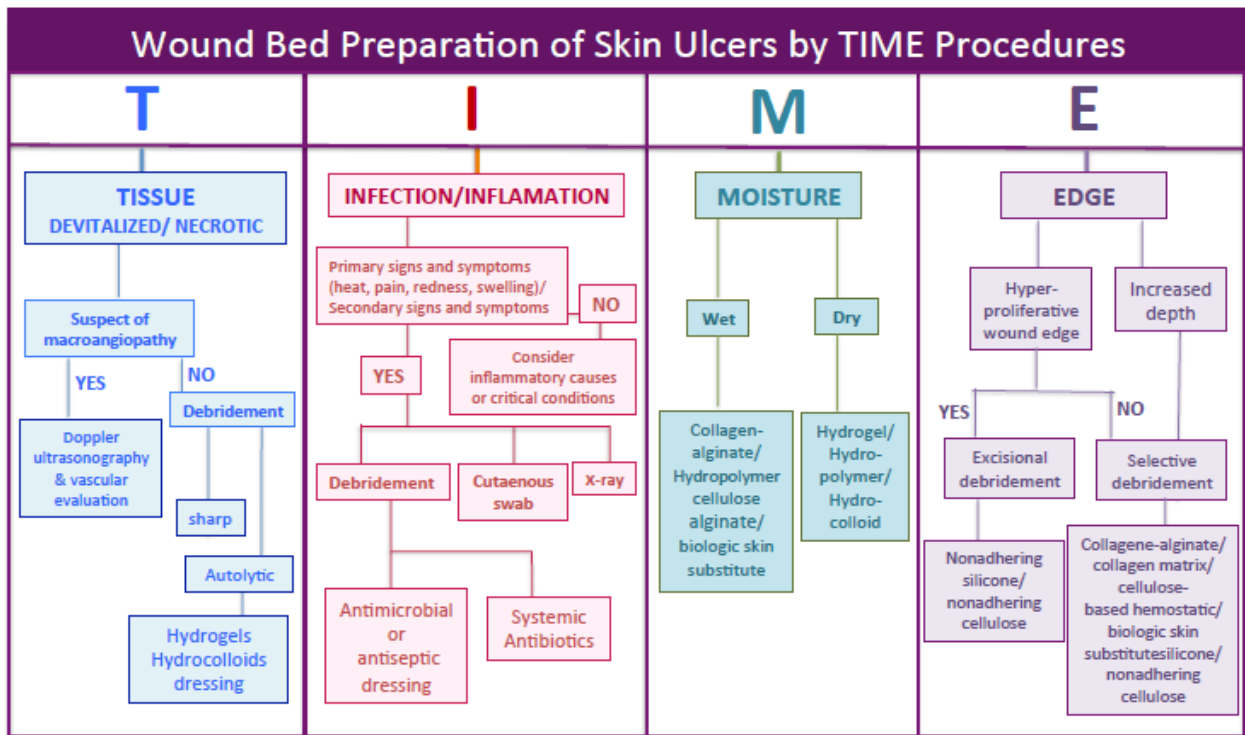


Fig. 4

**Tab 1. Definition and classification of scleroderma skin ulcers (SSc-SU)**

<b>Definition of SSc-SU</b>	<i>loss of substance involving epidermis, basement membrane, and dermis, and frequently deeper skin structures, lesions may be multiple, recurrent, and/or relapsing, they are localized at one or more skin areas, often acral zones of the hands and feet</i>
	SU refers to all ulcerative cutaneous lesions, including DU
<b>Classification of SSc-SU</b>	
<b>1. Digital ulcers (DU)</b>	
a- DU of the hands	<i>skin ulcers localized on fingertip or close to the nails</i>
b- DU of the feet	<i>skin ulcers localized on toe tips or close to the nails</i>
<b>2. SU of bony prominence</b>	<i>skin ulcers localized on joint contractures: PIP, MCP, elbows</i>
<b>3. SU of calcinosis</b>	<i>skin ulcers localized on subcutaneous calcinosis</i>
<b>4. SU of lower limbs</b>	<i>skin ulcers localized between knees and ankle-feet</i>
<b>5. SU/DU with gangrene</b>	<i>SU or DU presenting with gangrene needing differential diagnosis with critical ischemic lesions</i>
<b>Pseudo-DU/SU*</b>	<i>abrasions, fissures, scars digital pitting scars, sub-ungual hyperkeratosis</i>

\*Skin lesions inconsistent with diagnosis of DU/SU (see text)

PIP: proximal interphalangeal; MCP: metacarpal phalangeal joints

Tab. 2. Treatments of Systemic Sclerosis (SSc) and Scleroderma Skin Ulcers		
SSc	Skin Ulcers	
	systemic	local
<b>immunomodulators</b>	Ca-channel blockers prostacyclin analogue <sup>^^</sup> ERA PDE-5 inhibitors GCSF, EPO homologous PG	Wound Bed Preparation (TIME)  advanced dressings <sup>oo</sup> alginate, hydrocolloid hydrofiber, hydrogel polyurethane foam/film
cyclophosphamide mycophenolate mofetil azathioprine methotrexate corticosteroids plasmapheresis phototherapy HSCT rituximab	autologous/allogenic skin grafting  autologous adipose tissue-derived cell fractions	silver hydrofiber/foams/others  antimicrobial peptides
<b>others</b>		bacteriolytic enzymes naturally derived agents
ERA, PDE-5 inhibitors prostacyclin analogue ACE inhibitors*, PPI prokinetic drugs <sup>^</sup>	analgesics** antibiotics non-pharmacological measures <sup>o</sup>	analgesic dressings
analgesics, NSAIDs antibiotics  nutritional support		

HSCT: haematopoietic stem cell transplantation; PPI: proton pump inhibitors;

PDE-5, phosphodiesterase type5 inhibitors; GCSF: granulocyte-colony stimulating factor;

ACE: angiotensin-converting enzyme inhibitors for scleroderma renal crisis;

ERA: endothelin receptor antagonist; EPO: erythropoietin; <sup>^</sup>for gastroesophageal reflux disease;

PG: platelet gel, autologous and allogenic skin grafting,

\*\*analgesics: paracetamol, opioids; <sup>o</sup>see text; NSAIDs: nonsteroidal anti-inflammatory drugs

TIME:Tissue (necrotic ), Infection, Inflammation, Moisture (balance), and Epithelization (see Fig. 4)

^^iloprost, alprostadil; °°Advanced dressings: see ref. No. 29;

analgesic dressings: lydocaine, lydocaine and prilocaine mixture (EMLA), morphine.

ACCEPTED MANUSCRIPT

Tab. 3. Clinico-epidemiological features of SSc patients with/without skin ulcers (SU)

	total	SU+	SU-	<i>p</i>	DU hand+*	DU hand-*	<i>p</i>
Patients no. (%)	282 (100)	156 (55)	126 (45)		140 (50)	142 (50)	
Females	254 (90)	135 (87)	119 (94)	.03	120 (86)	134 (94)	ns
Males	28 (10)	21 (13)	7 (6)		20 (14)	8 (6)	
Age at SSc onset	51.5±13.9	50.0±14.5	53.9±12.8	.024	48.3±14.2	54.9±12.9	<0.001
Age at first visit	54.6±13.5	53.3±13.9	56.8±12.7	.034	51.7±12.9	57.5±12.9	<.001
Follow-up (yrs ± SD)	5.8±4.6	6.3±4.6	5.4±4.4	ns	6.5±4.5	5.4±4.7	.025
SSc duration (yrs ± SD)	3.1±5.7	3.3±5.6	2.7±6.1	ns	2.8±6.1	2.8±5.6	ns
Ray. duration (yrs ± SD)**	6.4±11.0	6.5±11.1	6.0±10.6	ns	8.7±10.9	6.2±10.9	ns
Limited cutaneous SSc	236 (84)	123 (79)	113 (90)	.015	106 (76)	130 (91)	<.001
Diffuse cutaneous SSc	46 (16)	33 (21)	13 (10)		34 (24)	12 (9)	
Raynaud's phenomenon	254 (90)	142 (91)	112 (89)	ns	128 (91)	126 (89)	ns
Calcinosis	37 (13)	29 (19)	8 (6)	.002	21 (15)	16 (11)	ns
Teleangiectasias	183 (65)	112 (72)	71 (56)	.008	102 (73)	81 (57)	.006
Melanoderma	109 (39)	74 (47)	35 (28)	<.001	65 (46)	54 (38)	ns
Arthritis	19 (7)	10 (6)	9 (7)	ns	10 (7)	9 (6)	ns
Myositis	9 (3)	6 (4)	3 (2)	ns	5 (4)	4 (3)	ns
Sicca Syndrome	129 (46)	65 (42)	64 (51)	ns	66 (47)	63 (44)	ns
lung fibrosis^	134 (48)	81 (52)	53 (42)	ns	70 (50)	64 (45)	ns
Heart inv.	94 (33)	48 (31)	46 (36)	ns	39 (28)	55 (39)	ns
PAPs>40	39 (14)	28 (20)	11 (9)	.036	16 (11)	23 (16)	ns
Renal inv.	19 (7)	11 (7)	8(6)	ns	10(7)	9(6)	ns
smoking habit	91 (32)	51 (33)	40 (32)	ns	47 (34)	44 (31)	ns
ESR altered	84 (30)	51 (33)	33 (26)	ns	42 (30)	42 (30)	ns
CRP altered	59 (21)	44 (28)	15 (12)	.001	33 (24)	27 (19)	ns
anti-Scl70+	94 (33)	54 (35)	40 (32)	ns	54 (39)	40 (28)	ns
ACA+	126 (45)	64 (41)	62 (49)	ns	52 (37)	74 (52)	.012
ANoA+	44 (16)	27 (17)	17 (13)	ns	25 (18)	19 (13)	ns

\*with/without other types of SU; \*\*before dis onset

^at high resolution computed tomography

**Tab. 4. Prevalence of different complications of skin ulcers (SU) in SSc patients.**

Complications	total SU (156)	DU hand (129)	DU feet (28)	SU-BP (25)	SU-CA (14)	SU-LEGS (21)
Infections	105 (67.3%)	41 (31.8%)	20 (71.4%)	19 (78%)	8 (57.7%)	17 (81%)
Osteomyelitis	30 (19.2%)	20 (15.5%)	10 (35.7%)	0	0	0
Gangrene	26 (16%)	19(15%)	7(25%)	0	0	0
Amputations*	18 (11.5%)	10 (7.8%)	8 (26.8%)	0	0	0

DU digital ulcers ;

BP: SU of bone prominence ;

CA: SU of calcinosis (see Tab.1)

\*including autoamputations

**Tab. 5.**  
**Clinical studies reporting definitions and classification criteria of scleroderma SU (review of the world literature).**

	Authors	year	Refence No.	mono-/multicenter	definition/classification
1	Hummers LK.	2003	11	-/+	<b>DU:</b> a. small, superficial ulcerations occurring on the distal or proximal finger; b. deep ulcerations of the distal digit.
2	Korn J.H.	2004	12	-/+ (clinical trial)	<b>DU:</b> loss of surface epithelialization, not including fissures, cracks, or calcinosis-related.
3	Chung L.	2006	39	+/-	<b>DU:</b> necrotic lesion that occur either at distal aspects of digits or over bony prominences.
4	Nihtyanova S.I.	2008	40	+/-	<b>DU:</b> areas of loss of surface epithelisation affecting the digital pulp or bony prominence, not including fissures or areas of calcium extrusions.
5	Sunderkotter C.	2009	41	-/+ (GermanNetwork SSc - DNSS)	<b>Active DU:</b> loss of both epidermis and dermis in an area of at least 2 mm in diameter on the distal phalanx of the fingers.
6	Steen V.	2009	6	-/+	<b>DU:</b> may occur on the fingers or toes and can manifest on the tips, the finger creases, over the extensor surfaces of the joints or in association with calcinosis.
7	Alivernini S.	2009	42	+/-	<b>DU:</b> classified into fingertip ulcers, located on the distal digits and 'other' ulcers situated over bony prominences.
8	Herrick A.L.	2009	10	-/+ (web-based study)	Lack of agreement between 'inactive' and 'active' <b>DU</b> through images
9	Amanzi L.	2010	7	-/+	<b>classification at presentation:</b> <b>DPS</b> , defined as small-sized hyperkeratosis; <b>DU</b> , defined as a loss of epithelialization and tissues involving, in different degrees, the epidermis, the dermis, the subcutaneous tissue and sometimes also involving the bone; <b>calcinosis</b> , defined as deposits of calcium phosphate in soft tissues; <b>gangrene</b> , defined as the death of tissues caused by a total lack of blood supply.

10	Khimdas S.	2011	43	-/+ (CSRG)	<b>Active ulcers</b> defined as denuded areas with defined borders and loss of epithelialization, loss of epidermis, and dermis distal to the proximal interphalangeal joint on the volar aspect of a finger.
11	Matucci-Cerinic M.	2011	44	-/+ (clinical trial)	<b>Healed ulcers</b> defined by complete epithelialization of an ischemic ulcer.
12	Guillevin L.	2013	5	-/+ (DUO Registry Group)	<b>Active DU:</b> onset between 1 week and 3 months prior to randomisation, selected and termed the 'cardinal ulcer' ( $\geq 2$ mm diameter) at volar surface of the digit distal to the proximal interphalangeal digital crease
13	Baron M.	2014	45	-/+ (consensus opinion)	<b>DU</b> defined as a denuded area with defined border and loss of epithelialisation, loss of epidermis and dermis.
					<b>DU:</b> lesion with visually discernable depth and a loss of continuity of epithelial coverage, denuded or covered by a scab or necrotic tissue
					<b>Active ulcers:</b> denudation is clearly visible at any part of the base, and the de-epithelialized bed can be seen.
					<b>Indeterminate ulcers:</b> the examiner is not able to determine whether an ulcer is active or not
					<b>Healed ulcers:</b> complete healing when total re-epithelialization is observed.
14	Moran M.E.	2014	46	review	<b>DU</b> categorised as either ischemic or traumatic.
					<b>Ischemic lesion or ulcers</b> are formed by a lack of blood flow to the digits and these ulcers are very painful. Most ischemic ulcers will be found on the second and third digits.
					<b>Traumatic lesions or ulcers</b> occur over boney prominences such as the elbows or phalangeal joints and are thought to be formed from repetitive trauma to relatively avascular areas.
15	Abraham S.	2015	47	review	<b>DU</b> defined as a denuded area of tissue with well-demarcated borders involving loss of both the dermis and epidermis
16	Matucci-Cerinic M.	2016	4	-/+ (DUO Registry Group)	<b>Episodic:</b> rarely recurrent: only 1 FU visit with either $\geq 1$ DU or new DU; the remaining FU visits have no DU and no new DU
					<b>Recurrent:</b> frequently recurrent, $\geq 2$ FU visits with DU and/or new DU, and $\geq 1$ visit with no DU and no new DU
					<b>Chronic:</b> $\geq 1$ DU and/or new DU at every FU visit

17	Hachulla E.	2016	48	-/+ (clinical trial)	<b>DU:</b> break in the skin with loss of epithelialisation on the distal finger surface not located over subcutaneous calcifications or over extensor surfaces of joints.
18	Khanna D.	2016	49	-/+ (clinical trial)	<b>Active DU</b> defined as a finger lesion with visually discernible depth and a loss of continuity of epithelial coverage associated.
19	Baron M.	2016	15	-/+	<b>DU</b> defined as ulcers on the volar aspect of the digits distal to the PIP joints thought to be caused by ischaemia and specifically excluding ulcers over calcium deposits
20	Hunzelmann N.	2016	50	-/+	<b>Active DU</b> defined as a loss of both epidermis and dermis in an area of at least 2-mm diameter at the distal phalanx of the fingers but not over bony prominences, encompassing the palmar (volar) area.
21	Ahrens H.C.	2016	51	-/+	<b>DU</b> defined as epithelial lesions with tissue loss occurring at the fingers or the feet, they can be classified into three groups: DUs on digital pitting scars, primary DUs and DUs on calcinosis .
22	Morrisroe K.	2016	52	-/+	<b>Persistent DU</b> defined as the loss of epithelialization of any degree of the dermis and/or the subcutaneous tissue, distal to or at the proximal interphalangeal joint of the hands or feet not due to trauma or underlying calcinosis.
23	Souza E.J.R.	2016	53	-/+	<b>DU</b> defined as denuded areas with defined borders and loss of epithelization and tissues involving, to different degrees, the epidermis, dermis, and the subcutaneous tissue distal to the proximal interphalangeal joint.
24	Denton C.P.	2016	20	-/+ (BSR and BHPR guidelines)	<b>DU</b> result of poor tissue perfusion over the digital pulps, around the nailfold and on extensor surfaces of the fingers or toes and may also occur in relation to calcinosis.
25	Cutolo M.	2016	54	-/+ (CAP Study)	<b>DU</b> defined as a denuded area located on the fingers and with a defined border and loss of epithelialization and a loss of epidermis and dermis.
26	Moinzadeh P.	2016	21	-/+ (GermanNetwork SSc - DNSS)	<b>Digital tip ischemia/ulcer</b> defined as digital pitting scars, ulcerations or gangrene, located at finger and/or toe tips.

27	Valenzuela A.	2016	13	-/+ (Scleroderma Clinical Trials Consortium - SCTC)	<b>DU</b> defined as denuded areas with a defined border, loss of epithelialization and loss of epidermis and dermis on the volar aspect distal to the proximal interphalangeal joints.
28	Suliman Y.A.	2017	14	review	<b>SU</b> defined as loss of epidermal covering with a break in the basement membrane. It appears clinically as visible blood vessels, fibrin, granulation tissue and/ or underlying deeper structures (e.g., muscle, ligament, fat), or as it would appear on debridement.
29	present series	2017		+/-	<b>SU</b> defined as <i>loss of substance involving epidermis, basement membrane, and dermis; the latter can be variably involved, considering that the more severe lesions may affect deeper skin layers, i.e. subcutaneous tissue, muscle, ligament, and bone; classified: 1. DU of the hands and DU of the feet, 2. SU on bony prominence, 3. SU on calcinosis, 4. SU of lower limbs, and 5. SU or DU presenting with gangrene</i>

SU: skin ulcers; DU: digital ulcers; FU: follow up;