



---

Scand J Work Environ Health 2011;37(3):253-258

<https://doi.org/10.5271/sjweh.3132>

Published online: 17 Nov 2010, Issue date: May 2011

**“Is this case of a very rare disease work-related?” A review of reported cases of Pacinian neuroma**

by [Zanardi F](#), [Cooke RMT](#), [Maiorana A](#), [Curti S](#), [Farioli A](#), [Bonfiglioli R](#), [Violante FS](#), [Mattioli S](#)

**Affiliation:** Università di Bologna, Unita Operativa di Medicina del Lavoro, Policlinico S.Orsola-Malpighi, via Pelagio Palagi, 9, I-40138 Bologna, Italy. [s.mattioli@unibo.it](mailto:s.mattioli@unibo.it)

**Key terms:** [hand injury](#); [mechanoreceptors pathology](#); [occupational exposure](#); [pacinian corpuscles](#); [Pacinian neuroma](#); [work-related](#)

This article in PubMed: [www.ncbi.nlm.nih.gov/pubmed/21082159](http://www.ncbi.nlm.nih.gov/pubmed/21082159)

---

**Additional material**

Please note that there is additional material available belonging to this article on the [Scandinavian Journal of Work, Environment & Health -website](#).



This work is licensed under a [Creative Commons Attribution 4.0 International License](#).

## “Is this case of a very rare disease work-related?” A review of reported cases of Pacinian neuroma

by Francesca Zanardi, MD,<sup>1</sup> Robin MT Cooke, MA,<sup>1</sup> Antonino Maiorana, MD,<sup>2</sup> Stefania Curti, MStat,<sup>1</sup> Andrea Farioli, MD,<sup>1</sup> Roberta Bonfiglioli, MD,<sup>1</sup> Francesco Saverio Violante, MD,<sup>1</sup> Stefano Mattioli, MD,<sup>1</sup>

Zanardi F, Cooke RMT, Maiorana A, Curti S, Farioli A, Bonfiglioli R, Violante FS, Mattioli S. “Is this case of a very rare disease work-related?” A systematic review of reported cases of Pacinian neuroma. *Scand J Work Environ Health*. 2011;37(3):253–258. doi:10.5271/sjweh.3132.

**Objective** In response to a request for a medicolegal opinion from an orthopaedic technician with pacinian neuroma of the hand, we conducted a systematic review of reported cases designed to assess whether this rare disease could be considered to be work-related.

**Methods** We used Medline, Embase, Google Scholar, Google, and a manual search to identify reports of histologically confirmed pacinian neuroma of the hand manifesting after 15 years of age. Cases with available information (from article/authors) on personal history were considered eligible. We tabulated information on age/gender; localization and histopathologic features; signs/symptoms; history of local trauma; occupation, sports/hobbies or other physical exposures; right- or left-handedness; and outcome.

**Results** We found 44 eligible cases (including the present referral). Of these, 21 (48%) followed a trauma [ $<6$  months from onset/presentation (N=7); 0.5–2 years from onset (N=6);  $\geq 2$  years from onset (N=7); and timing unknown (N=1)] involving the same anatomic site. Three of these 21 traumas definitely occurred at work, and a further 2 cases occurred at the site of definite work-related repetitive microtrauma.

**Conclusions** The results reinforce the concept that pacinian neuroma of the hand can follow local trauma or repetitive microtrauma. Implicated traumas were either recent or remote, and they sometimes occurred while performing manual tasks at work. We concluded that the referred case could plausibly be considered work-related.

**Key terms** hand injury; mechanoreceptors pathology; occupational exposure; pacinian corpuscles.

How should an occupational physician determine whether a specific case of a very rare disease could be considered to be of a work-related origin? When asked for a medicolegal opinion regarding a highly suspicious case of pacinian neuroma in the hand of an orthopaedic technician, we did not wish to avoid the question by giving the standard response of “insufficient evidence”.

First described in 1952 (1), pacinian neuroma is a benign lesion involving proliferation of normal sized or enlarged pacinian corpuscles (cutaneous mechanoreceptors sensitive to rapid vibrations). Pacinian neuroma is mainly observed in the hand and foot and it can be excruciatingly painful and incapacitating. Trauma to digital nerves or normal (2) pacinian corpuscles has been postulated as a plausible risk factor (3, 4). How-

ever, knowledge of this rare entity is largely based on non-systematic reviews of case reports and small case series which may not provide strong enough evidence for many medicolegal contexts. To address the question whether onset of this rare disease can be attributed to work-related factors (within our own national medicolegal context), we decided to conduct a systematic review of reported cases of pacinian neuroma of the hand.

### Case report

A 38-year-old man with a histopathological diagnosis of pacinian neuroma (figure 1) visited our unit to verify, for medicolegal purposes, whether the condition was likely of a professional origin. The patient had worked for 21

<sup>1</sup> Section of Occupational Medicine, Department of Internal Medicine, Geriatrics and Nephrology, Alma Mater Studiorum University of Bologna, Bologna, Italy.

<sup>2</sup> Università di Modena e Reggio-Emilia, Dipartimento di Servizi Diagnostici, di Laboratorio e di Medicina Legale, Sezione di Anatomia Patologica, Modena, Italy.

Correspondence to: Professor Stefano Mattioli, Unità Operativa di Medicina del Lavoro, Policlinico S.Orsola-Malpighi, via Pelagio Palagi 9, I-40138 Bologna, Italy [E-mail: s.mattioli@unibo.it]

years as an orthopaedic technician preparing prosthetic limbs and strongly suspected that occupational use of solvents could have been responsible for the disease. In a clinical interview, it emerged that the patient (who is right-handed) used a hammer, blade, and handsaw to build the prosthesis, a pneumatic hammer to break the chalk mould, and milling machines for finishing. These tasks all produced many flying splinters of different materials (mainly carbon fibers and resins) that sometimes penetrated the patient's fingers (including the affected one) despite the use of latex gloves. He had regularly used various types of pliers to try to extract the splinters.

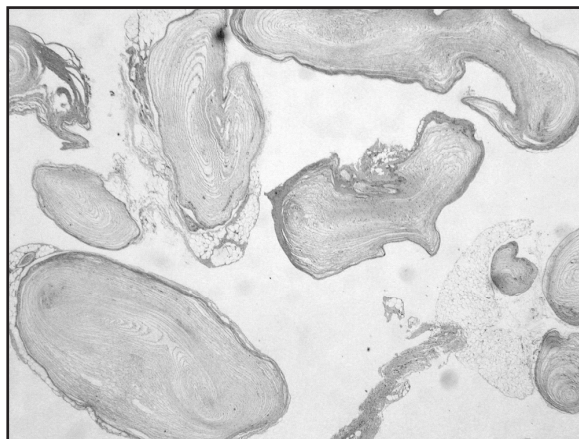
In 2003, the patient had experienced mounting pain, swelling and functional limitation of the right thumb. A rapidly growing nodule was evident at the level of the first interphalangeal joint. Despite X-ray and magnetic resonance imaging examinations, the nature of the lesion remained unclear. Following total body bone scintigraphy, which suggested a possible neoplastic lesion in the right thumb, the nodule was surgically excised in February 2004. At macroscopic examination, the lesion consisted of a well-defined, hard, whitish nodule (9 × 8 mm). Microscopically, it was composed of a clump of about a dozen adjacent, enlarged pacinian corpuscles, which appeared to be normally structured, exhibiting concentric lamellae around terminal nerve endings (figures 1 and 2).

Due to incomplete functional recovery, the patient was operated again to remove adhesions three months later. Despite resolution of functional limitations and pain, the patient subsequently experienced sensitivity loss between the first and second phalanx of the right thumb (plausibly due to nerve compression) and a new adhesion in the operated zone, restricting his professional dexterity. Having completed courses of physiotherapy and non-steroid anti-inflammatory drugs, the patient currently performs self-massage with gel to maintain elasticity of the skin.

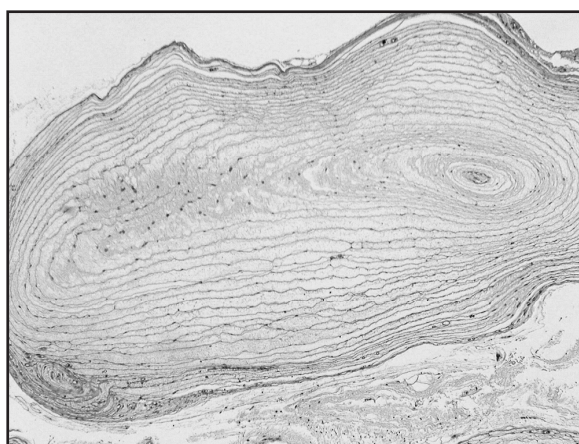
## Methods

### Search strategy and selection criteria

We conducted a systematic search of the literature devised to retrieve reports ever published in any language of histologically diagnosed pacinian neuroma of the hand with onset/presentation after 15 years of age (a cut-off point based on the minimum working age in many countries). We used the following PubMed search string (applying the "humans" limit only when screening articles already indexed for Medline that were published since 1966): (pacini\* NOT pacini[au]) OR (pacini[au]



**Figure 1.** Pacinian neuroma exhibiting a group of about a dozen normally structured pacinian corpuscles. Haematoxylin and eosin, x 1.25 (original magnification).



**Figure 2.** Higher magnification of pacinian corpuscle in pacinian neuroma. Concentric lamellae are layered around central nerve endings. Haematoxylin and eosin, x 4 (original magnification).

AND (pacini[tw] OR pacinian[tw])). We also used the terms "pacini" and "pacinian" to search Embase, Google Scholar and Google. Finally, we manually searched all the citations contained in the retrieved articles and obtained all potentially pertinent additional articles whenever possible. Electronic database searches were closed on 24 March 2010.

Specific eligibility criteria were: (i) histological confirmation of pacinian neuroma of the hand; (ii) presentation after 15 years of age; and (iii) some available information regarding personal history (other than age and gender).

One of the authors screened all retrieved articles for pertinence and eligibility in the present study, and doubtful cases were decided by discussion. Whenever appropriate and feasible, we solicited additional

information regarding personal history from the authors of the original reports (6 articles; 14 cases).

#### Data extraction and case classification

Two authors performed data extraction and checked case classification. After piloting the extraction, we decided to record the following information: age/gender; localization of nodule and brief histopathological description; localized signs and symptoms; reported history of local trauma, specifying temporality (preferably time to onset, ie, latency); any information on occupation and sports/hobbies or other physical exposure information; right- or left-handedness; anatomically distant traumas; childhood onset; outcome of treatment, comorbidities (eg, glomus tumour). Finally, we classified the history of each case as “following a local trauma”, and temporality in terms of (i) “very recent” (1 week to 6 months from onset/presentation), (ii) “recent” (6 months to 2 years) or (iii) “remote” ( $\geq 2$  years); “following local repetitive microtrauma”; or “unclear”. In cases where local trauma/repetitive microtrauma definitely (or presumably) occurred at work, we specified the occupational setting, whenever known. We classified as work-related cases, pacinian neuromas of the hand that arose at the site of a previous single trauma or repetitive microtrauma that was definitely reported to have occurred at work.

## Results

### Cases identified

The PubMed search string evoked 953 publications. We were able to glean a further 21 potentially pertinent publications using Embase, and an additional article from Google. Manually searching all the citations led to retrieval of a further 22 accessible publications (the single inaccessible publication did not appear to report cases). Thus, we retrieved a total of 997 potentially pertinent articles. After eliminating articles not containing reports of cases (regarding plastic surgery techniques, associations with other pathologies or anatomical observations etc.), we identified 78 cases of pacinian neuroma diagnosed after 15 years of age (reported in 63 articles). Remarkably, only 29% (23/78) of cases concerned localizations other than the hand [foot (N=4), anogenital (N=3), intra-abdominal (N=3), oral cavity (N=2), sacrococcygeal region (N=3), buttocks (N=2), maxilla (N=1), arm (N=1), loin (N=1), neck (N=1), lymph node (N=1), retroperitoneal (N=1)].

After assessing the 55 reported cases of pacinian neuroma of the hand and receiving personal commu-

nications from two groups of authors, 44 cases [in 35 articles (4–36), including the present one; 34 women; median age 45 years, range 17–72] were deemed to satisfy the specific eligibility criteria. Case number 28 was described in two separate reports (one in Japanese language only) (10, 22).

### Description and classification of cases

Table 1 in the Appendix ([www.sjweh.fi/data\\_repository.php](http://www.sjweh.fi/data_repository.php)) reports extracted information for each of the 44 cases. Job titles were available for 23 cases [blue-collar (N=11); white-collar (N=2); nurses (N=2); housewives (N=5); students (N=3)]. Of the 44 cases, 21 (48%) were classified as definitely having followed a single local trauma [very recent (N=7); recent (N=6); remote (N=7); unknown timing (N=1)]. Of these 21 trauma, 3 (14%) were *definitely* work-related (case numbers 2, 7, and 12); 2 (10%) *presumably* were work-related (cases 15 and 34); 4 (19%) were *definitely/presumably not* work-related (numbers 3, 5, 19, and 35); in 12 cases (57%), the setting is unknown (cases 9, 13, 14, 20, 22, 23, 28, 36, 39, 40, 42, and 43). A further 2 (4%) of the 45 cases of pacinian neuroma of the hand (cases 30 and 44) were classified as following well-documented local repetitive microtrauma at work [of note, a further case (number 6) may have been related to amateur sport-related repetitive microtrauma]. Thus, a total of 5 cases could be considered to have followed a definite occupational history of local trauma or local repetitive microtrauma.

## Discussion

When asked to provide a professional opinion regarding the possible occupational etiology of a case of pacinian neuroma in the hand of a worker found to be exposed to repetitive microtrauma at the site of the lesion, we conducted a systematic review of reported cases in the literature. The results reinforce the concept that this rare disease can follow trauma in the same anatomical site. Remarkably, the implicated local trauma could be recent or remote. The trauma sometimes occurred while performing manual tasks at work, and at least one other documented case definitely followed repetitive microtrauma. Based on these findings, we expressed our professional opinion that the case referred to us for medicolegal purposes could plausibly be considered work-related.

Knowledge of whether a rare disease can be attributed to work-related factors can be of considerable medicolegal relevance to affected individuals. For instance, an employee who has experienced a pacinian neuroma of

the hand that is deemed to be work-related may be able to claim financial compensation and more easily change job task. However, it is difficult to find evidence to determine whether cases of rare diseases can be considered to be of a work-related origin. Systematic reviews of cases can help gain reliable evidence on rare harms and other unusual occurrences (37). We adopted this study design as an evidence-based method of actively addressing a specific medicolegal question concerning the possible work-related aetiology of a clinically relevant rare disease.

In the context of an extremely rare disease, for which we were able to trace only 44 reported cases supplying some personal information about the patient (other than age and gender), the finding that a total of 23 cases could be strictly classified as directly following a trauma/repetitive microtrauma at the same anatomical site seems remarkable. Unsurprisingly perhaps, at least five of the implicated traumas were definitely work-related. Even considering publication bias (in a disease widely suspected to be related to trauma, authors may be predisposed to search for and report traumas and suspect activities), the thematic consistency of the findings presented in table 1 seems to provide strong suggestive evidence that pacinian neuroma of the hand frequently has a direct, trauma-related aetiology. Remarkably, onset tended to occur at the exact site of trauma at varying times, ranging from a few weeks to decades after the original exposure. Thus, we think that it is reasonable on medicolegal grounds to classify as sequelae of an occupational injury those cases of pacinian neuroma of the hand that arise on the anatomical site of a work-related trauma, even if experienced many years previously.

The pathogenesis of pacinian neuroma is unclear. It has been postulated that any insult to the nerves or tendons, including repetitive traumas, could be a precipitating factor, promoting proliferation of the corpuscles (3, 4, 24, 28, 29). Case number 18, involving incidental finding of a non-symptomatic example in an expert reader of Braille, was originally interpreted as implying a causative link with increased demand for fine tactile perception; however, this claim was unsubstantiated (38), and since this blind man worked with power tools he would presumably have been exposed to hand-arm vibrations. Although the spectrum of the different types of trauma implicated was wide (ranging from fracture to contusion), we were somewhat surprised to find that hand-arm vibrations were not implicated in any of the reports under review even though this exposure can affect the function of pacinian corpuscles (39).

Regarding pacinian neuroma of the hand following repetitive microtrauma, we were able to locate a single definite reported case (occurring in a professional violinist) in addition to the one described herein. Nevertheless, on pathophysiologic grounds, repetitive local traumas

can be considered a particular type of “local trauma” (adding insult to injury, one might say). Therefore, we think that local repetitive microtraumas, such as those encountered in these two cases, can also be considered a plausible causal factor.

### Limitations

It might be tempting to conclude that pacinian neuroma of the hand may be considered a new work-related disease. However, a systematic review of reported cases has inherent methodological limitations. Indeed, the study design precluded definition of a clear-cut outcome measure to determine whether pacinian neuroma of the hand could be considered a work-related disease. Of particular concern is that a systematic review of reported cases cannot generate information regarding the strength of association – an important criterion for consideration of causality. Case-control studies would be necessary to evaluate risk analytically, but such an undertaking seems scarcely feasible due to the extreme rarity of the condition.

In addition to publication bias (see above), other forms of bias require consideration, including the “Texas sharpshooter fallacy”, ie, fixing the hypothesis after collection of study data (many of the reported cases included in the present study had already been considered in earlier non-systematic reviews such as, most recently, reference 35). However, 7 of the 21 cases classified as following a local trauma (numbers 9, 30, 35, 37, 39, 40, 43) were not considered in earlier reviews. Classification of cases as being definitely trauma- and work-related was hampered by the scarce information regarding personal history (or ambiguous wording) in many of the eligible reports where it was not possible to gain additional clarification from the authors. It is plausible that a higher number of the implicated local traumas actually occurred at work.

It might be argued that this systematic review only helped “rediscover the wheel” given that many authors have already emphasized the relevance of a history of local trauma for onset of pacinian neuroma. Nevertheless, formal production of evidence is generally considered necessary in medicolegal contexts. To our knowledge, this is the first time that pacinian neuroma of the hand has been investigated as a putative new work-related disease.

### Concluding remarks

The results of this systematic review of pacinian neuroma of the hand reinforce the concept that a causal link can be considered plausible for cases that arise in the anatomical site of past occupational or non-occupational traumas, including repetitive microtraumas. We think that possible

history of occupational (or non-occupational) traumas or repetitive microtraumas should be investigated and reported when painful pacinian neuroma of the hand is diagnosed in adult age. Documentation regarding any further cases linked to repetitive microtraumas may provide useful information on the spectrum of traumatic events that may be linked to the disease and indirectly to evaluate whether pacinian neuroma of the hand could be considered a new (albeit very rare) work-related disease. Such information may help provide a basis for medico-legal decisions within different national contexts. In the meantime, we think it is reasonable to suppose that painful cases of pacinian neuroma of the hand occurring even several years after a local trauma encountered at work can plausibly be considered clinically relevant sequelae of an occupational injury.

### Acknowledgements

We thank Professor Jos Verbeek for discussing the study with us and providing some valuable methodological suggestions. We are also grateful to Professor Ana De Kaminsky, Professor Christopher Fletcher, Dr Brent T Harris and Dr Paolo Rinaldi for providing personal communications containing further information on reported cases.

### References

- Prichard RW, Custer RP. Pacinian neurofibroma. *Cancer*. 1952;5:297–301. doi:10.1002/1097-0142(195203)5:2<297::AID-CNCR2820050215>3.0.CO;2-3.
- Stark B, Carlstedt T, Hallin RG, Risling M. Distribution of human Pacinian corpuscles in the hand. A cadaver study. *J Hand Surg Br*. 1998;23:370–2. doi:10.1016/S0266-7681(98)80060-0.
- Requena L, Sanguenza OP. Benign neoplasm with neural differentiation: a review. *Am J Dermatopathol*. 1995;17:75–96. doi:10.1097/00000372-199502000-00015.
- Zweig J, Burns H. Compression of digital nerves by pacinian corpuscles: a report of two cases. *J Bone Joint Surg*. 1968;50:999–1001.
- Patterson TJ. Pacinian corpuscle neuroma of the thumb pulp. *Br J Plast Surg*. 1956;9:230–231. doi:10.1016/S0007-1226(56)80039-8.
- Hart WR, Thompson NW, Hildreth DH, Abell MR. Hyperplastic pacinian corpuscles: a cause of digital pain. *Surgery*. 1971;70:730–735.7.
- Sandzen SC, Baksic RW. Pacinian hyperplasia. *Hand*. 1974;6:273–274. doi:10.1016/0072-968X(74)90039-4.
- Rhode CM, Jennings WD Jr. Pacinian corpuscle neuroma of digital nerves. *South Med J*. 1975;68:86–89.
- Cameron S. Two rare case of nerve entrapment. *J Bone Joint Surgery*. 1976;58:266.
- Kojima T, Kasai S, Aizawa S, Kirino Y. A case of hyperplasia of pacinian corpuscles [in Japanese]. *Jpn J Plast Reconstr Surg*. 1977;20:8–12.
- Schuler FA 3rd, Adamson JE. Pacinian neuroma, an unusual cause of finger pain. *Plast Reconstr Surg*. 1978;62:576–579. doi:10.1097/00006534-197810000-00014.
- Chavoin JP, Durroux R, Mansat M, Costagliola M, Souquet R. Painful tumoral proliferation of the Pacinian corpuscles in the hand. *Ann Chir*. 1980;34:738–742.
- Gama C, Franca LC. Nerve compression by pacinian corpuscles. *J Hand Surg (Am)*. 1980;5:207–210.
- Greider JL Jr, Flatt AE. Glomus tumor associated with pacinian hyperplasia – case report. *J Hand Surg (Am)*. 1982;7:113–117.
- Yasunaga H, Abe M, Ikeda K, Shigematsu T, Onomura T, Ogihara K. Pacinian hyperplasia; a report of two cases. *Orthop Surg*. 1983;34:1835–1838.
- Lang-Stevenson AI. Induction of hyperplasia and hypertrophy of pacinian corpuscles. *Br Med J (Clin Res Ed)*. 1984;288:972–973. doi:10.1136/bmj.288.6422.972.
- Friedman HI, Nichter LS, Morgan RF, Edgerton MT. Subepineural pacinian corpuscle: a cause of digital pain. *Plast Reconstr Surg*. 1984;74:699–703. doi:10.1097/00006534-198411000-00020.
- Brynildsen PJ. Painful digital subepineural pacinian corpuscles. *Plast Reconstr Surg*. 1985;75:929–30. doi:10.1097/00006534-198506000-00044.
- Fletcher CD, Theaker JM. Digital pacinian neuroma: a distinctive hyperplastic lesion. *Histopathology*. 1989;15:249–256. doi:10.1111/j.1365-2559.1989.tb03075.x.
- De Kaminsky AR, Glikin I, Torres Cortijo A, Poledore I, Kaminsky CA, Cordero AA. Vater Pacini's neurofibroma. Report of 3 cases. *Med Cutan Ibero Lat Am*. 1989;17:317–320.
- Jones NF, Eadie P. Pacinian corpuscle hyperplasia in the hand. *J Hand Surg (Am)*. 1991;16:865–869. doi:10.1016/S0363-5023(10)80151-0.
- Kojima T. Pacinian corpuscle hyperplasia in the hand. *J Hand Surg (Am)*. 1992;17:976–977. doi:10.1016/0363-5023(92)90484-7.
- McPherson SA, Meals RA. Digital pacinian corpuscle neuroma eroding bone: a case report. *J Hand Surg (Am)*. 1992;17:476–478. doi:10.1016/0363-5023(92)90354-R.
- Dobyns JH. Digital nerve compression. *Hand clinics*. 1992;8:359–367.
- Bas L, Oztek I, Numanoglu A. Subepineural hyperplastic pacinian corpuscle: an unusual cause of digital pain. *Plast Reconstr Surg*. 1993;92:151–153. doi:10.1097/00006534-199307000-00024.
- Fraitag S, Gherardi R, Wechsler J. Hyperplastic pacinian corpuscles: an uncommonly encountered lesion of the hand. *J Cutan Pathol*. 1994;21:457–460. doi:10.1111/j.1600-0560.1994.tb00289.x.
- Reznik M, Thiry A, Fridman V. Painful hyperplasia and hypertrophy of pacinian corpuscles in the hand: report of

- two cases with immunohistochemical and ultrastructural studies, and a review of the literature. *Am J Dermatopathol.* 1998;20:203–207. doi:10.1097/00000372-199804000-00019.
28. Rinaldi P, Andreini A, Ercolani C, Bernardi L, Bernardi S. Digital pacinian hyperplasia. Report of a case associated with foreign body reaction. *Pathologica.* 2000;92:36–40.
29. Imai S, Kikuchi K, Matsusue Y. Digital pacinian corpuscle hyperplasia. *J Am Soc Surg Hand.* 2003;3:175–180. doi:10.1016/S1531-0914(03)00071-8.
30. Vaes F, De Smet L. A rare cause of digital pain: The subepineural Pacinian corpuscle. *Eur J Plast Surg.* 2003;26:370–372. doi:10.1007/s00238-003-0569-7.
31. Kumar A, Darby AJ, Kelly CP. Pacinian corpuscles hyperplasia—an uncommon cause of digital pain. *Acta Orthop Belg.* 2003;69:74–76.
32. Kuruvila S, Devi KL, Malhotra G, Thomas C. Pacinian neuroma. *Neurosciences.* 2003;8:53–54.
33. Kenmochi A, Satoh T, Fukuyama K, Yokozeki H. Pacinian neuroma. *J Eur Acad Dermatol Venereol.* 2006;20:1384–1385. doi:10.1111/j.1468-3083.2006.01737.x
34. Yan S, Horangic NJ, Harris BT. Hypertrophy of Pacinian corpuscles in a young patient with neurofibromatosis. *Am J Dermatopathol.* 2006;28:202–204. doi:10.1097/00000372-200606000-00004
35. Vijayaraghavan R, Chandrashekar R, Belagavi CS, Murthy NB. Painful digital Pacinian corpuscle hyperplasia following dog bite: a case report. *Int J Surg.* 2008;6:e42–5. doi:10.1016/j.ijssu.2007.01.001.
36. Yenidunya MO, Yenidunya S, Seven E. Pacinian hypertrophy in a type 2A hand burn contracture and Pacinian hypertrophy and hyperplasia in a Dupuytren’s contracture. *Burns.* 2009;35:446–450. doi:10.1016/j.burns.2008.01.019.
37. Glasziou P, Vandenbroucke JP, Chalmers I. Assessing the quality of research. *BMJ.* 2004;328:39–41. doi:10.1136/bmj.328.7430.39.
38. Ponsford JR. Tactile spatial resolution in blind braille readers. *Neurology.* 2000;55:1597.
39. Bovenzi M, Apostoli P, Alessandro G, Vanoni O. Changes over a workshift in aesthesiometric and vibrotactile perception thresholds of workers exposed to intermittent hand transmitted vibration from impact wrenches. *Occup Environ Med.* 1997;54:577-87. doi:10.1136/oem.54.8.577.
39. Bovenzi M, Apostoli P, Alessandro G, Vanoni O. Changes over a workshift in aesthesiometric and vibrotactile perception thresholds of workers exposed to intermittent hand transmitted vibration from impact wrenches. *Occup Environ Med.* 1997;54:577-87.

Received for publication: 3 May 2010